

# Disc Herniation and Cyst Gas: A Rare Association Causing Radicular Compression

## *Herniação de gás intraespinal: uma associação rara causando compressão radicular*

Cherkaoui Mandour<sup>1</sup> Miloudi Gazzaz<sup>1</sup> Brahim el Mostarchid<sup>1</sup>

<sup>1</sup> Department of Neurosurgery; Military Hospital Mohammed V, Rabat, Morocco

**Address for correspondence** Cherkaoui Mandour, MD, Department of Neurosurgery, Military Hospital Mohammed V, Rabat 10000, Morocco (e-mail: mandour1978@hotmail.com).

Arq Bras Neurocir 2017;36:133–135.

### Abstract

**Introduction** Intraspinal gas is a common clinical finding, but an epidural gas pseudocyst in association with lateral disc herniation compressing a nerve root is an exceptional observation.

**Case Report** A 49-year-old man was admitted to our department presenting with sciatica. The neurological examination demonstrated moderate lumbar pain without neurological deficit. A lumbosacral computed tomography showed the presence of degenerated disc herniation and epidural gas collection.

**Discussion** The pathological association between the cyst and the hernia is probably due to the migration of gas pumped from the intervertebral space through a breaking point or lower in the annulus fibrosis, involving its contiguity with the herniated disc.

**Conclusion** An association between a disc herniation and a gas pseudocyst can be a cause of sciatica.

### Keywords

- disc herniation
- gas pseudocyst
- sciatica

### Resumo

**Introdução** O gás intraespinal é um achado clínico comum, mas um pseudocisto epidural de gás associado a herniação discal lateral comprimindo uma raiz nervosa é uma observação excepcional.

**Relato de caso** Um homem de 49 anos de idade foi admitido em nosso departamento apresentando sintomas de ciática. O exame neurológico demonstrou dor lombar moderada sem déficit neurológico. A tomografia computadorizada lombossacral mostrou presença de hérnia discal degenerada e coleta epidural de gás.

**Discussão** A associação patológica entre o cisto e a hérnia é provavelmente devida à migração do gás bombeado do espaço intervertebral através de um ponto de ruptura ou menor na fibrose do anel, envolvendo a sua contiguidade com o disco herniado.

**Conclusão** Uma associação entre uma hérnia de disco e um pseudocisto de gás pode ser uma das causas de ciática.

### Palavras-Chave

- hérnia discal
- pseudocisto de gás
- ciática

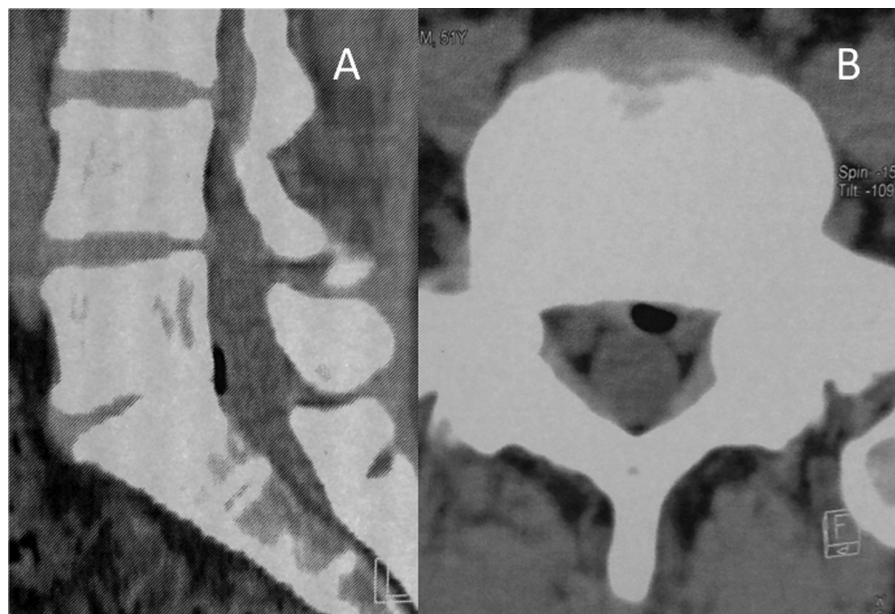
received  
February 18, 2017  
accepted  
April 7, 2017

DOI <https://doi.org/10.1055/s-0037-1603986>.  
ISSN 0103-5355.

Copyright © 2017 by Thieme Revinter  
Publicações Ltda, Rio de Janeiro, Brazil

License terms





**Fig. 1** Sagittal reformatted (Panel A) and axial reformatted (Panel B) computed tomography image of lumbosacral spine showing clearly a lateral disc herniation and gas pseudocyst with evidence of root compression.

## Introduction

The most common causes of lumbar radiculopathy are intervertebral disc herniation and lumbar canal stenosis.<sup>1</sup> Intraspinal extradural masses like disc cysts, perineural cysts, synovial cysts, and ganglion cysts are rare causes.<sup>1</sup>

Intraspinal gas has been reported in several situations, including craniocervical trauma, epidural anesthesia, spinal surgery, infection and tumors.<sup>2</sup> First reported in 1980 by Gulati and Weinstein,<sup>3</sup> an association between disc herniation and gas pseudocyst has rarely been reported ever since. We report a case of this unusual clinical presentation.

## Case Report

A 49-year-old Moroccan man was admitted to our department presenting with sciatica for 10 days. The neurological examination objectified a moderate low back pain without neurological deficit. A lumbosacral spine computed tomography scan (→ Fig. 1: Panel A and B) showed the presence of a degenerated disc hernia and an epidural gas collection with evidence of root compression. The patient refused surgery after improvement achieved under medical treatment.

## Discussion

Gas in the intervertebral disk space is a relatively common radiologic finding, seen in 46% of cases on computed tomography examinations.<sup>4</sup> However, the existence of gas within the spinal canal has been seen in only a few cases in the literature worldwide,<sup>5</sup> and an epidural gas pseudocyst compressing a nerve root associated with a lateral disc herniation is also a rare clinical presentation.<sup>6,7</sup>

This pathological association between the cyst and the hernia is probably due to the migration of gas pumped from

the intervertebral space through a breaking point in the annulus fibrosis, involving its contiguity with the herniated disc.<sup>8</sup>

The vacuum phenomenon in the intervertebral disk space and gas accumulation in the epidural space can be better characterized with CT by its typical attenuation values. Also, associated findings include osteophytes of adjacent vertebral bodies and degeneration of discs,<sup>6</sup> but magnetic resonance imaging is a good modality for evaluation of the intervertebral disc, the spinal cord and the nerve roots.<sup>9</sup>

Surgery is the preferred treatment in chronic encapsulated lesions that do not resolve with conservative management.<sup>10,11</sup>

## Conclusion

Through this clinical case, we find that an association between a disc herniation and an epidural gas pseudocyst can be a cause of sciatica.

## References

- Jeong GK, Bendo JA. Lumbar intervertebral disc cyst as a cause of radiculopathy. *Spine J* 2003;3(03):242–246
- Ilica AT, Kocaoglu M, Bulakbasi N, Kahraman S. Symptomatic epidural gas after open discectomy: CT and MR imaging findings. *AJNR Am J Neuroradiol* 2006;27(05):998–999
- Gulati AN, Weinstein ZR. Gas in the spinal canal in association with the lumbosacral vacuum phenomenon: CT findings. *Neuroradiology* 1980;20(04):191–192
- Belfquih H, El Mostarchid B, Akhaddar A, gazzaz M, Boucetta M. Sciatica caused by lumbar epidural gas. *Pan Afr Med J* 2014;18:162
- Lardé D, Mathieu D, Frija J, Gaston A, Vasile N. Spinal vacuum phenomenon: CT diagnosis and significance. *J Comput Assist Tomogr* 1982;6(04):671–676
- Hidalgo-Ovejero AM, Martinez-Grande M, Garcia-Mata S; HIDALGO OVEJERO A.M. Disc herniation with gas. *Spine* 1994; 19(19):2210–2212

- 7 Battal B, Bozlar U, Sanal H, Saglam M, Bulakbasi N, Ustunsoz B. Symptomatic epidural gas accumulation originating from vacuum phenomenon in the intervertebral disc: CT imaging findings. *The Internet Journal of Radiology*. 2008;10(01):1–4
- 8 Salpietro FM, Alafaci C, Collufio D, et al. Radicular compression by lumbar intraspinal epidural gas pseudocyst in association with lateral disc herniation. Role of the posterior longitudinal ligament. *J Neurosurg Sci* 2002;46(02):93–95, discussion 95
- 9 Giraud F, Fontana A, Mallet J, Fischer LP, Meunier PJ. Sciatica caused by epidural gas. Four case reports. *Joint Bone Spine* 2001; 68(05):434–437
- 10 Tamburrelli F, Leone A, Pitta L. A rare cause of lumbar radiculopathy: spinal gas collection. *J Spinal Disord* 2000;13(05):451–454
- 11 Demierre B, Ramadan A, Hauser H, Reverdin A, Rilliet B, Berney J. Radicular compression due to lumbar intraspinal gas pseudocyst: case report. *Neurosurgery* 1988;22(04):731–733