



Smokeless Tobacco: Insight on Prevalence of Oral Manifestation

Hasan Baber¹, Zunaira Rabbani², Ambreen Meghani³

¹Assistant Professor, Department of Oral Biology, Dow University of Health Sciences, Karachi, Pakistan.

²Lecturer, Department of Periodontology, Baqai Medical University, Karachi, Pakistan.

³House Officer, Dr Ishrat ul Ibad Institute of Oral Health Sciences, Dow University of Health Sciences, Karachi, Pakistan.

Author to whom correspondence should be addressed: Hasan Baber, Department of Oral Biology, Dow University of Health Sciences, Mission Rd, New Labour Colony Nanakwara, Karachi, Karachi City, Sindh 74200, Pakistan. Phone: +923352369977. E-mail: relicpassion@yahoo.com.

Academic Editors: Alessandro Leite Cavalcanti and Wilton Wilney Nascimento Padilha

Received: 02 July 2018 / Accepted: 29 October 2018 / Published: 09 November 2018

Abstract

Objective: To determine the prevalence of oral mucosal lesions among smokeless tobacco users of Pakistani Population. **Material and Methods:** A cross-sectional study was conducted for a period of six months (from July 2017 to January 2018) at Dental Outpatient department of Sindh, via aid of a validated custom-made questionnaire. Random sampling technique was adopted among patients attending dental Outpatient Departments, making use of OPEN API online software determining sample size as 289, with limitation included exclusion of pregnant women, edentulous individuals, children under age of 18 years and those having oral manifestations associated with any systemic disease. Statistical analysis included Logistic Regression and Chi-square for determining odds' ratio and possible associations. **Results:** Logistic regression model 71% predicted discoloration of buccal mucosa 206 times in absence of any predictor variable. Discoloration of oral tissues was prevalent among individuals who chewed tobacco at least 6 times or more in a day. Periodontal associated damage was also prevalent among 6 times/day and more tobacco chewers. Statistically significant values were for normal buccal mucosa 06-10 times ($p=0.007$), white patch on buccal mucosa 11-15 times ($p=0.0043$) and swelled buccal mucosa 11-15 times ($p=0.002$). **Conclusion:** This study has demonstrated specific smokeless tobacco associated oral lesions. Further studies nationwide, addressing attributes of socioeconomic status and ethnicity with respect to composition of smokeless tobacco will reveal more conclusive findings.

Keywords: Tobacco Use; Tobacco, Smokeless; Mouth Mucosa.

Introduction

Oral cavity is susceptible to a plethora of variations with increasing age, change of environment and factors related to life patterns. Oral lesions can occur due to number of factors such as trauma, infections, irritation, systemic diseases and oral consumption of tobacco [1]. The latter is consumed in many forms with most prevalent form as smokeless tobacco and cigarette smoke. Prevalence of oral mucosal lesions as a result of factors such as tobacco is available for different countries but the information within that context cannot be always applicable to subcontinent population because of cultural, ethnic and demographic differences. Although efforts have been made by various researchers regarding establishment of oral mucosal lesions, but is meager in subcontinent literature [2].

Etiology for increased prevalence of oral cancer in South Asia has been investigated at some level, but as in case with most developing countries, lack of research infrastructure has become a stumbling block in studying risk factors and epidemiology of these conditions with respect to South Asia [3]. Among various risk factors, smokeless tobacco is highly associated with oral premalignant lesions and oral cancer. Tobacco has been used in smoke, inhaled and chewed forms for more than 500 years [4]. Tobacco use is and will persist as a global phenomenon.

Epidemiological studies have reported south Asia accounting for 90% of smokeless tobacco use among rest of the world. Estimates suggest around 100 million people consume tobacco in Indian Subcontinent alone [5]. Various forms of smokeless tobacco consumed in Pakistan and India include chewing form with a mixture of Gutkha, Khaini, betel nut and Mishri. Smokeless tobacco has around 28 carcinogens [6]. Thus, changes associated in oral cavity as a result of smokeless tobacco are of utmost importance, and with such a high prevalence rate epidemiological studies must be carefully carried out. Present study is an effort to narrow the gap in determining prevalence of oral mucosal lesions among smokeless tobacco users of Pakistani Population.

Material and Methods

Study Design

This cross-sectional study was conducted in Dental Outpatient Department (OPD) of Sindh, Pakistan, among patients coming in Department of Oral Diagnosis.

Sampling

Population size was calculated by number of patient's intake in dental OPD during a period of six months (July 2017 to January 2018). Collected data was computed in online sample size calculator Open EPI, keeping 95% confidence interval, 5% Standard error of means and other factors set as default. The minimum sample size was 289 subjects.

Data Collection

Participants were selected between age of 18 and 75 years. Pregnant women or people having disability or disease affecting the response gathered were excluded from the study and participants are dentate.

Custom made questionnaire was developed from a similar study [7] and modified according to local setting. For collection of data three field investigators in form of dental house officers were selected based on their GPA. Each field investigator was told to attend annual workshop on research data collection and questionnaire design held during month of May each year. With respect to collection of data via questionnaire for this study, field investigators were demonstrated on demo patients by Head of the Department of Oral Pathology, regarding how to extract the required information from the questionnaire with respect to study objective.

A pilot study during month of May 2017 was initially conducted among 59 participants as problems with a prevalence of 5% will almost certainly be identified (with 95% confidence) in a pilot study including minimum 59 participants. Variables to assess oral features associated with smokeless tobacco included appearance, discoloration, and possible swelling of oral tissues including mucosa, tongue, lips, palate, gingiva and floor of the mouth. Each participant was asked number of times (less than 5 times, 6-10 times, 11-15 times, 16-20 times and more than 20 times) he/she chewed tobacco in a day (number of times here refer to individual kept small tobacco pellet in this mouth and number of times it was replaced or reused). Further variables included presence of any systemic disease not related to oral lesions. Participant highest qualification, evaluating oral hygiene practices by determining number of times participant brush their teeth daily and use any mouth wash, form in which they consumed smokeless tobacco such as chewing snuff and dissolvable. Pilot study excluded oral findings such as white patch on hard palate, smoker's palate, white patch and bands on mucosa as these features are not always associated with smokeless tobacco users. Apart from these, questionnaire for pilot study remained same.

Data Analysis

Chi-square test was used to determine possible association of oral mucosal lesions with smokeless tobacco use and logistic regression to determine odds ratio of smokeless tobacco with oral mucosa lesions. Data were analyzed using IBM SPSS Statistics for Windows Software, version 18 (IBM Corp., Armonk, NY, USA). Descriptive statistics were used to calculate the absolute and relative frequencies.

Ethical Aspects

A written informed consent was obtained from all the participants prior to the inclusion in the study.

Results

Logistic regression model 71.3% predicted discoloration of buccal mucosa 206 times in absence of any predictor variable (Table 1). Logistic regression model 51% predicted discoloration of labial mucosa 120 times in absence of any predictor variable.

Table 1. Logistic regression model for discolored buccal and labial mucosa.

Observed		Predicted		
		Discolored Buccal Mucosa		
Discolored Buccal Mucosa		Yes	No	Percentage Correct
	Yes	206	0	100.0
	No	83	0	0.0
	Overall Percentage			71.3
		Discolored Labial Mucosa		
Discolored Labial Mucosa		Yes	No	Percentage Correct
	Yes	120	18	10.7
	No	108	13	87.0
	Overall Percentage			51.4

Logistic Regression for discoloration of labial mucosa predicted Odds ratio of Betal nut chewing to cause 0.9 times more likely discoloration of buccal mucosa than cigarette smoke (0.7 times) (Table 2).

Table 2. Logistic regression for discoloration of labial mucosa.

		B	S.E.	Wald	df	Sig.	Exp(B)	95% C.I. for EXP(B)	
								Lower	Upper
Step 1a	Cigarette	-0.283	0.269	1.103	1	0.294	0.754	0.445	1.277
	Betal Nut	-0.047	0.273	0.030	1	0.862	0.954	0.559	1.627
	Constant	0.366	0.701	0.273	1	0.601	1.442		

*Variable(s) entered on step 1: Cigarette, Betal Nut.

Logistic regression model 55% predicted no discoloration of floor of mouth in absence of any predictor variable (Table 3).

Table 3. Logistic regression model for discoloration of floor of mouth.

Observed		Predicted		
		Discolored Floor of Mouth		
Discolored Floor of Mouth*		Yes	No	Percentage Correct
	Yes	0	130	0.0
	No	0	159	100.0
	Overall Percentage			55.0

*The cut value is 0.500.

Regarding discoloration of floor of mouth, logistic regression predicted Odds ratio of Betal nut chewing to cause 1.3 times more likely discoloration of floor of mouth than cigarette smoke (0.9 times) (Table 4).

Table 4. Logistic regression for discoloration of floor of mouth.

		B	S.E.	Wald	df	Sig.	Exp(B)	95% C.I. for EXP(B)	
								Lower	Upper
Step 1a	Cigarette	-0.004	0.255	0.000	1	0.986	0.996	0.604	1.641
	Betal Nut	0.275	0.257	1.148	1	0.284	1.316	0.796	2.176
	Constant	-0.0220	0.659	0.111	1	0.739	0.803		

*Variable(s) entered on step 1: Cigarette, Betal Nut.

Statistically significant values were for normal buccal mucosa 06-10 times ($p=0.007$), white patch on buccal mucosa 11-15 times ($p=0.004$) and swelled buccal mucosa 11-15 times ($p=0.002$) (Figure 1).

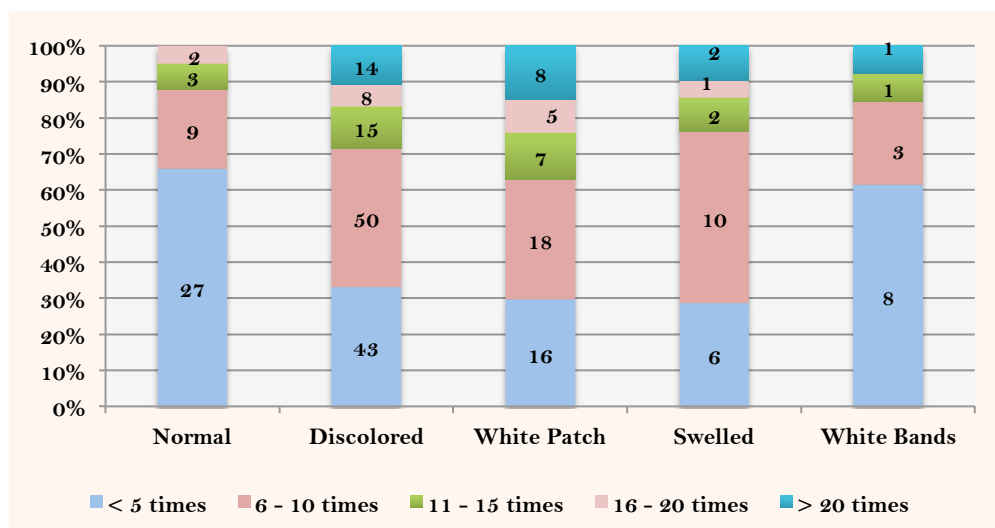


Figure 1. Appearance of the buccal mucosa according to number of times chewed tobacco/day.

Individuals that consumed tobacco at least 5 times a day had either normal lips or discoloration observed (Figure 2).

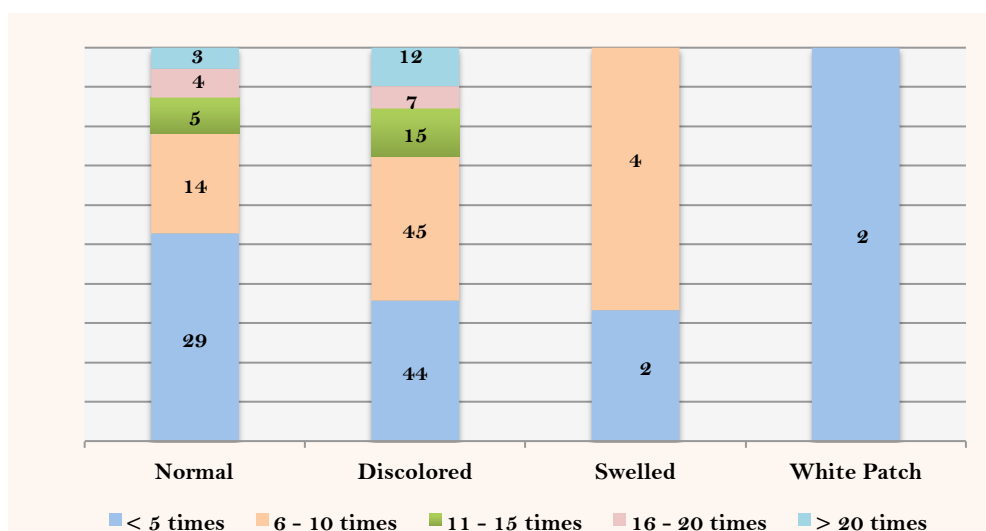


Figure 2. Appearance of the lips according to number of times chewed tobacco/day.

Individuals that chewed tobacco 6-10 times at least in a day had tongue discoloration absorbed among those that failed to maintain oral hygiene practices (Figure 3). Majority of individuals consuming tobacco on daily basis had normal palate with some having discoloration observed (Figure 4).

With respect to periodontal status, individuals consuming tobacco 6-10 times/day at least had discoloration of gingiva with apical migration of gingiva leading to recession, as observed by

cementoenamel junction (Figure 5). Normal and discolored labial mucosa was observed among individuals consuming 6-10 times tobacco in a day (Figure 6).

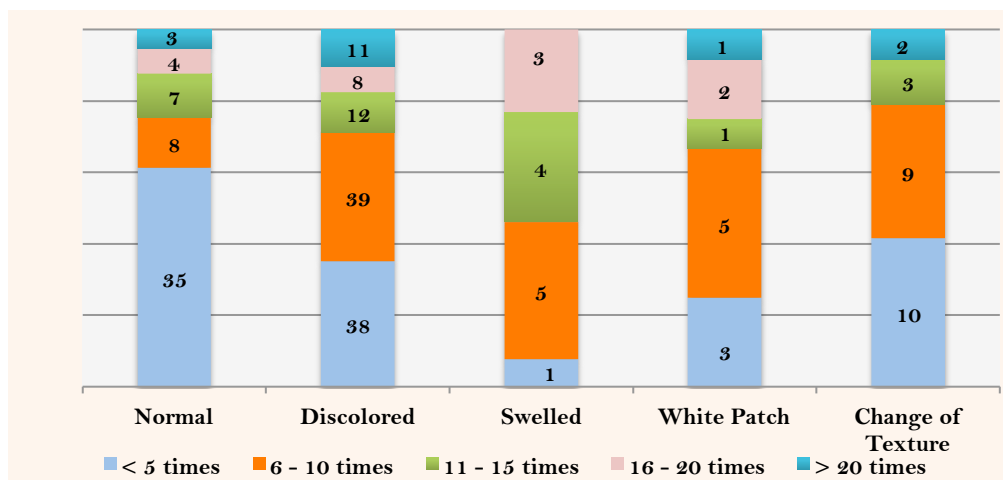


Figure 3. Appearance of the tongue according to number of times chewed tobacco/day.

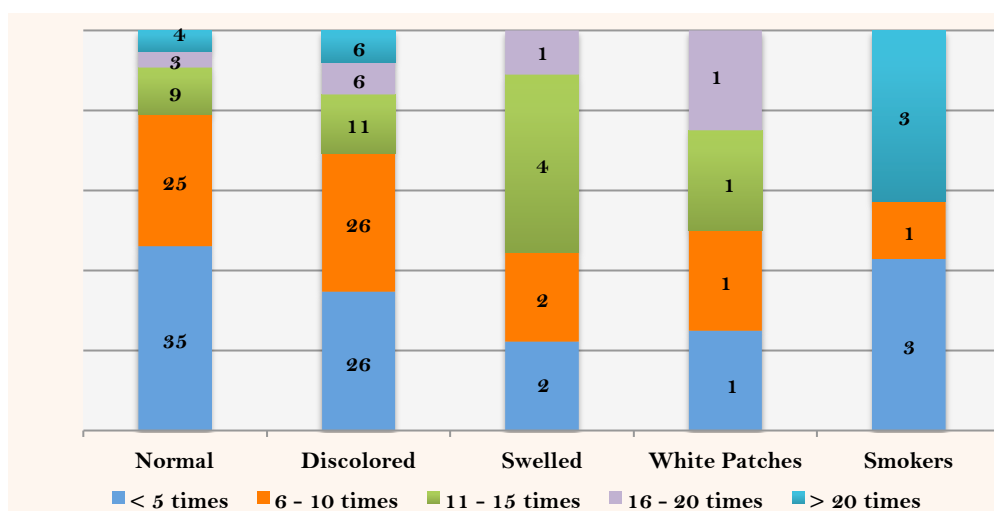


Figure 4. Appearance of the hard palate according to number of times chewed tobacco/day.

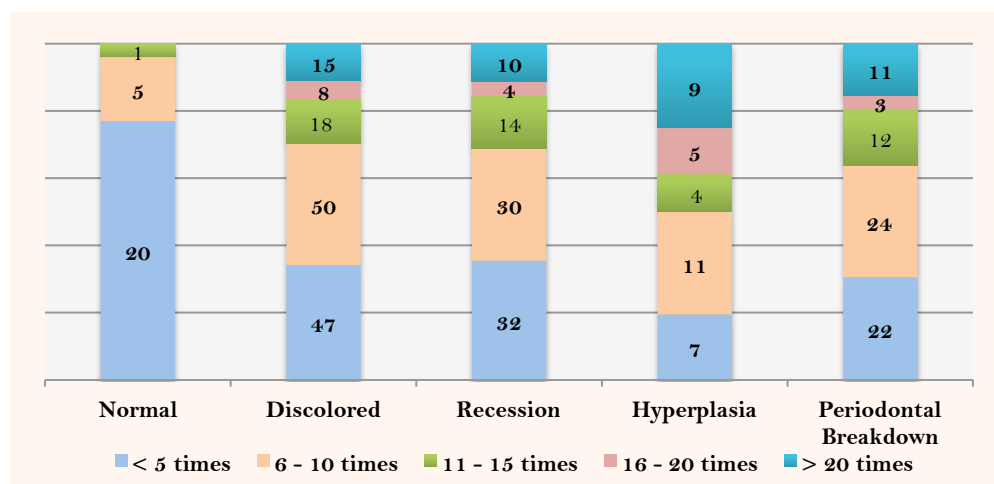


Figure 5. Periodontal status according to number of times chewed tobacco/day.

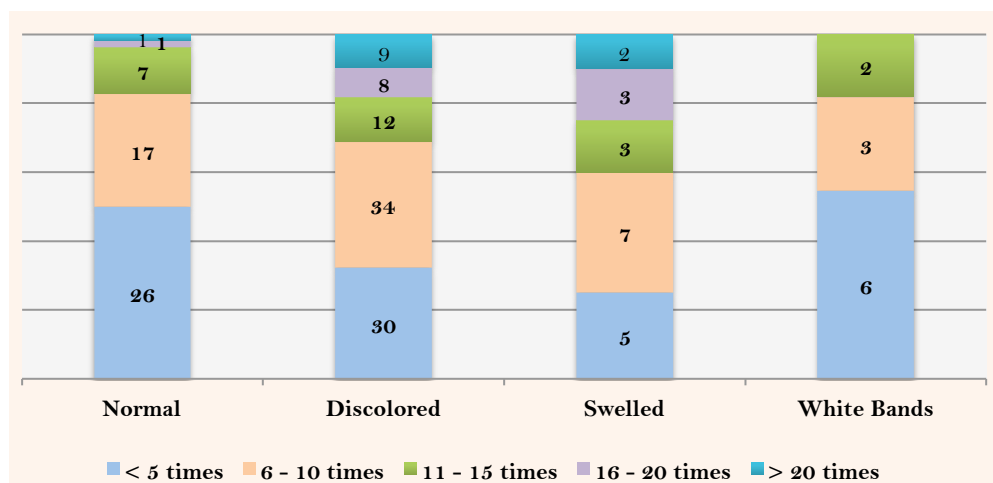


Figure 6. Appearance of the labial mucosa according to number of times chewed tobacco/day.

No significant changes were observed on floor of the mouth among individuals chewing tobacco 6-10 times/day with some having smoker's melanosis (Figure 7).

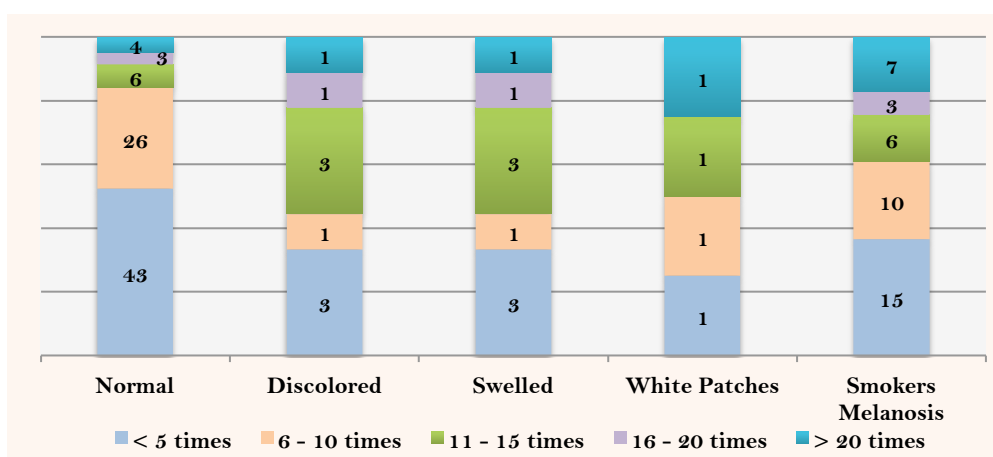


Figure 7. Appearance of the floor of mouth according to number of times chewed tobacco/day.

Discussion

Smokeless tobacco is mainly available as chewing tobacco and oral snuff. Grounded tobacco bound in a loose packaging or small tea bag like bags are available for oral snuff. Smokeless tobacco users usually insert a small pinch of oral snuff, aka dip in between gingiva and buccal mucosa for about 30 mins before replacing it. Coarsely shredded tobacco available in form of twists and bricks are consumed as chewing tobacco. Both forms of tobacco expectorate tobacco saliva liquid. Tobacco consumed in any form contain cancer causing chemicals such as N-nitrosamines, hydrocarbons, aromatic and formaldehyde [8].

Persistent contact of smokeless tobacco with oral tissues results in number of alterations possible due to presence of carcinogens as a protective response of oral tissues. Researchers term these variations as tobacco induced oral mucosal lesions [17].

Authors are of the opinion that occurrence of lesions in oral mucosa occurs, at site where tobacco is placed and is largely dependent on duration it is kept and number of times tobacco is consumed [7]. With respect to demographic factors respondents having high school and undergraduate education accounted for highest number of tobacco users. This is in line with another South Asian study that reported 56.7% and 24% tobacco users having at least basic and high school education [9]. This demonstrates a similar trend among tobacco users in South Asia. White patch on buccal mucosa was observed among 46% of participants who consumed smokeless tobacco with dose dependent parameters, similar to 47.4% subjects having leukoplakia in another study [9].

Past studies have evaluated oral mucosal lesions due to smokeless tobacco, based on amount of time tobacco kept at a specific site in buccal mucosa or used in a year or months. Present study evaluated oral lesions based on dose dependent and number of times respondents kept tobacco in mucosa. Discoloration of oral mucosa was highest among respondents, with major bulk contributed by individuals consuming smokeless tobacco 6 to 10 times in a day. This has not come as a surprise due to fact that smokeless tobacco use results in change in area of vicinity where it is held. The severity of discoloration depends upon type of smokeless tobacco leaf versus fine cut, brand of tobacco use, size of smokeless tobacco that is kept under mucosa and duration it is kept. This has been confirmed previously by other authors who demonstrated that oral lesions have an association with amount and duration of tobacco use [4,10-12].

Majority of oral lesions observed in current study were among respondents who kept at least 6-10 times smokeless tobacco in their mouth. Similar trend was observed in a previous study that showed individuals that kept tobacco in their mouth for 3-4 hrs and 4-5 packs to be 83.8% [17]. This trend of increase in number and duration of smokeless tobacco to be associated with increased risk for oral lesions has been reported by many researchers in similar studies [4,10-12]. Researchers have reported individuals chewing tobacco 6 to 10 times a day for 2 to 5 years displayed increased appearance of oral lesions, as a result of exposure to carcinogens.

With respect to effects on gingiva and periodontium, respondents that consumed 6-10 times smokeless tobacco in a day had the highest gingival discoloration, recession and periodontal breakdown. Recent studies have reported high frequency of periodontal breakdown and gingival recession associated with increased exposure to smokeless tobacco [13,14]. This high frequency of periodontal and gingival lesion was highest for individuals that consumed smokeless tobacco at least five times a day. Periodontal destruction due to smokeless tobacco was observed in adults group, which is backed by studies stating advanced periodontal destruction, severe and hard tissue changes are accounted by long term use of smokeless tobacco and these features are classically observed among adults. Severity and clinical oral lesions observed among smokeless tobacco users is largely dependent upon abrasive quality, content of tobacco, chemical composition and processing that varies widely among different parts of the globe [15]. Researchers have successfully reported characteristic pumice like appearance of oral mucosal lesions due to long term use of smokeless tobacco [16]. In our study none of the subjects were observed to have this sort of characteristic oral appearance and this can be due to different composition and processing of smokeless tobacco.

Current study is a small effort to discriminate oral lesions as a result of use of smokeless tobacco. Some limitations should be mentioned. First, this study has not evaluated subtypes of smokeless tobacco used among participants that can affect due to area of tobacco in contact with oral mucosa to vary. Sample size not large enough to be able to do multivariate analysis on smokeless tobacco chewers. And finally, this study did not classify sites where tobacco was kept, as this has varied impact on tissues exposed to tobacco in that area.

Conclusion

The study has revealed premalignant oral lesions to be associated with smokeless tobacco as compared to cigarette smoke since smokeless tobacco has thirty different cancer-causing agents and the fact that it spends more time in mouth than cigarette smoke, that otherwise has increased susceptibility for lung cancer.

References

1. Patel P, Patel V. Oral mucosal lesions among residence of a town in north Gujarat. *Nat J Med Res* 2011; 1(1):3-6.
2. Sudhakar S, Praveen Kumar B, Prabhat M. Prevalence of oral mucosal changes in Eluru, Andhra Pradesh (India) - An institutional study. *J Oral Health Comm Dent* 2011; 5(1):42-6.
3. Sridharan G. Epidemiology, control and prevention of tobacco induced oral mucosal lesions in India. *Indian J Cancer* 2014; 51(1):80-5. doi: 10.4103/0019-509X.134651.
4. Ashraf F, Pandey A, Laheji A, Paliwal K. Oral tissue changes associated with smokeless tobacco users of age group 15- 30 years residing in hadoti region - An epidemiological study. *Clin Dent* 2017; 11(7):9-14.
5. Mishra GA, Pimple SA, Shastri SS. An overview of the tobacco problem in India. *Indian J Med Paediatr Oncol* 2012; 33(3):139-45. doi: 10.4103/0971-5851.103139.
6. Stepanov I, Jensen J, Hatsukami D, Hecht SS. New and traditional smokeless tobacco: Comparison of toxicant and carcinogen levels. *Nicotine Tob Res* 2008; 10(12):1773-82. doi: 10.1080/14622200802443544.
7. Al-Maweri SA, Alaizari NA, Al-Sufyani GA. Oral mucosal lesions and their association with tobacco use and qat chewing among Yemeni dental patients. *J Clin Exp Dent* 2014; 6(5):e460-6. doi: 10.4317/jced.51706.
8. Souto GR, Matias MD, Nunes LF, Ferreira RC, Mesquita RA. Mature dendritic cell density is affected by smoking habit, lesion size, and epithelial dysplasia in oral leukoplakia samples. *Arch Oral Biol* 2018; 95:51-57. doi: 10.1016/j.archoralbio.2018.07.008.
9. Al-Attas SA, Ibrahim SS, Amer HA, Darwish ZE, Hassan MH. Prevalence of potentially malignant oral mucosal lesions among tobacco users in Jeddah, Saudi Arabia. *Asian Pac J Cancer Prev* 2014; 15(2):757-62.
10. Behura SS, Masthan MK, Narayanasamy AB. Oral mucosal lesions associated with smokers and chewers - A case-control study in Chennai population. *J Clin Diagn Res* 2015; 9(7):ZC17-22. doi: 10.7860/JCDR/2015/14008.6169.
11. Wolfe MD, Carlos JP. Oral health effects of smokeless tobacco use in Navajo Indian adolescents. *Community Dent Oral Epidemiol* 1987; 15(4):230-5. doi: 10.1111/j.1600-0528.1987.tb00527.x.
12. Singh I, Singh A, Kour R, Singh A, Singh R, Bali A. Is sodium carbonate in snuff a causative factor for oral mucosal lesions: A cross-sectional analysis. *J Int Soc Prev Community Dent* 2018; 8(4):339-42. doi: 10.4103/jispcd.JISPCD_134_18.
13. Noland M, Rayens MK, Wiggins AT, Huntington-Moskos L, Rayens EA, Howard T, Hahn EJ. Current use of e-cigarettes and conventional cigarettes among US high school students in urban and rural locations: 2014 National Youth Tobacco Survey. *Am J Health Promot* 2018; 32(5):1239-47. doi: 10.1177/0890117117719621.
14. Carr AB, Ebbert J. Interventions for tobacco cessation in the dental setting. *Cochrane Database Syst Rev* 2012; (6):CD005084. doi: 10.1002/14651858.CD005084.pub3.
15. Kharazmi M, Carlsson AP, Hallberg P, Modig M, Björnstad L, Hirsch JM. Surgical approach to snus-induced injury of the oral mucosa. *J Oral Sci* 2014; 56(1):91-4.

16. Warnakulasuriya S, Ariyawardana A. Malignant transformation of oral leukoplakia: A systematic review of observational studies. *J Oral Pathol Med* 2016; 45(3):155-66. doi: 10.1111/jop.12339.
17. Grady D, Greene J, Daniels TE, Ernster VL, Robertson PB, Hauck W, et al. Oral mucosal lesions found in smokeless tobacco users. *J Am Dent Assoc* 1990; 121(1):117-23.