

Extruded Lumbar Disc Herniation with Spontaneous Reabsorption: Case Report and Review

Reabsorção espontânea de hérnia discal lombar extrusa: relato de caso

Carlos Eduardo da Silva¹ Paulo Eduardo P. de Freitas² Matheus V. Fernandes³ Matheus F. Gomes³
Alex Spassim³ Ademar S. Mesquita Jr³ Geniffer C. Cardoso³ Gustavo S. Raupp³ Leonardo D. Olijnyk⁴

¹ Director, Neurosurgery and Skull Base Surgery Department, Hospital Ernesto Dornelles, Porto Alegre, RS, Brazil

² Neurosurgeon, Neurosurgery and Skull Base Surgery Department, Hospital Ernesto Dornelles, Porto Alegre, RS, Brazil

³ Medical Academic, Neurosurgery and Skull Base Surgery Department, Hospital Ernesto Dornelles, Porto Alegre, RS, Brazil

⁴ Resident, Neurosurgery and Skull Base Surgery Department, Hospital Ernesto Dornelles, Porto Alegre, RS, Brazil

Address for correspondence Carlos Eduardo da Silva, MD, Av. Ipiranga, 1801, Azenha, Porto Alegre, RS, Brazil 90160-093 (e-mail: dasilvacebr@yahoo.com.br).

Arq Bras Neurocir 2016;35:70–73.

Abstract

Keywords

- disc herniation
- spontaneous regression
- disc reabsorption

Resumo

Palavras-chave

- hérnia discal
- regressão espontânea
- reabsorção discal

Disc herniation is a common condition in the population and has a direct impact on the quality of life in patients, also causing functional limitations in the work place. Treatment protocols include conservative management and/or various surgical interventions. This paper reports on a case of symptomatic large extruded disc herniation, together with spontaneous clinical regression and total re-absorption. We show here conservative management, and a literature review of the main pathophysiological hypotheses for such an unusual evolution.

Hérnia discal é condição comum na população e tem impacto direto na qualidade de vida dos pacientes, assim como causa limitações funcionais em seu ambiente de trabalho. Protocolos de tratamento incluem manejo conservador e/ou diversos tipos de intervenção cirúrgica. Este artigo relata o caso de uma extensa hérnia extrusa sintomática, juntamente a sua regressão clínica espontânea e sua total reabsorção. Descrevemos também seu manejo conservador e uma revisão da literatura para a principal hipótese diagnóstica nesta evolução incomum.

Introduction

The herniated disc of the lumbar spine occurs more frequently in discs L4-L5 and L5-S1 transitionally. It is estimated that 2–3% of the population may be affected, with prevalence of

4.8% in men and 2.5% in women aged over 35 years.¹ All patients present changes in their performance at work due to pain, including the inability to work.²

Although surgical intervention for the treatment of this disease has existed for over 60 years, and the literature

received
October 4, 2014
accepted
August 28, 2015

DOI <http://dx.doi.org/10.1055/s-0035-1570496>.
ISSN 0103-5355.

Copyright © 2016 by Thieme Publicações Ltda, Rio de Janeiro, Brazil

License terms



describes many different techniques, conservative treatment is an alternative to surgery that may reverse the symptoms completely or partially, including partial reduction in the size of the hernia.

The authors present the case of a patient with a large extruded lumbar disc herniation and severe sciatic symptoms with spontaneous reabsorption of the disc and discuss the clinical aspects of this disease.

Case Report

A 31-year-old man, with morbid obesity, complains of intense lumbar and sciatic pain experienced for about two months and reports a worsening after physiotherapy. Magnetic resonance imaging (MRI) of the lumbar spine revealed a voluminous posterior median disc protrusion L5-S1, migrating cranial to the posterior portion of the L5 vertebral body (►Fig. 1). We considered surgical treatment, following a period of nutritional treatment. After 40 days, the patient had returned showing a weight loss of 29kg and controlled pain (score 1 on a scale of 1 to 10), after using a nonsteroidal anti-inflammatory. A new MRI showed a spontaneous resolution of the herniated lumbar disc ~5 months after onset (►Figs. 1 and 2). In twelve months, the patient no longer complained of sciatic pain.

Discussion

Teplick and Haskin³ first documented spontaneous regression of a herniated disc after confirmation via a follow-up of computed tomography (CT) scans on 11 patients. Since then, reports of this phenomenon have surfaced randomly.

The literature describes cases of spontaneous resolution of the lumbar disc herniation in different clinical situations, including the presence of severe radiculopathy.⁴⁻⁸ Three mechanisms were proposed to explain this phenomenon.

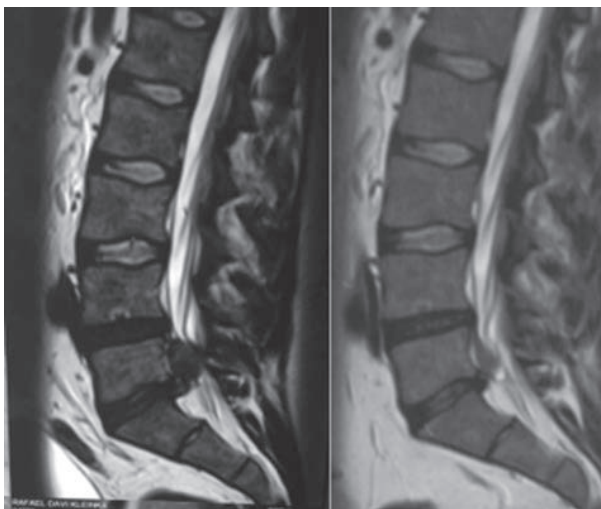


Fig. 1 Left: sagittal MRI with L5-S1 extruded disc herniation with upward dislocation; Right: sagittal MRI 5 months later with spontaneous disc herniation reabsorption.

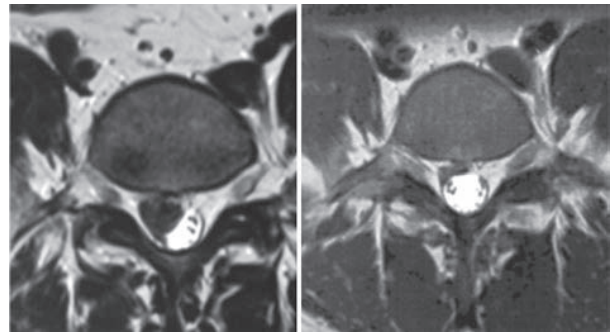


Fig. 2 Left: axial MRI with right disc herniation; Right: axial MRI presenting the spontaneous disc reabsorption.

The first defends that the herniated disc retracts, returning into the intervertebral space again. The second emphasizes that dehydration followed by shrinkage of the herniated disc occur. The last mechanism advocates enzymatic degradation and phagocytosis, due to an inflammatory reaction and neovascularization, which are responsible for such reabsorption.^{8,9} Hernias in the epidural space would be recognized by the immune system as foreign bodies, therefore, programming an inflammatory answer against trying to remove this invasive tissue. This reaction would lead to neovascularization, enzymatic degradation, and phagocytosis.¹⁰⁻¹⁵ Haroet et al, in a study designed with animal subjects, demonstrated that the induction of a chondrocytic enzyme (metalloproteinase-3), through the macrophages, plays an essential role in the spontaneous re-absorption of the herniated tissue.¹³

The literature offers other pathologic processes. Burke et al¹⁶ stated that the intervertebral disc is able to produce cytokines (MCP-1 and IL-8), responsible for the macrophage chemotaxis and capillarization, which culminate in the synthesis of a granulation tissue that precedes the hernia reabsorption. Hirabayashi et al¹¹ showed that epidural fat vessels infiltrate the herniated disc, and are followed by granulation tissue, with possible transformation into scar tissue. Carreon et al¹⁷ showed evidence of the different reactions between the fibrous annulus, which induce neovascularization and propitiate spontaneous reabsorption, including of the cartilage endplate. This presence reduces the neovascular response and prevents the degradation of the herniated tissue and reabsorption.

In a clinical study, Minamide et al¹⁸ demonstrated the presence of neovascularization and the increase in inflammatory cell numbers, which facilitated the reabsorption of the disc herniation in a group treated with fibroblastic growing factor.

The clinical impact of this spontaneous hernia resolution reflects a gradual change in management protocols, prioritizing the initial conservative treatment. Weber's study¹⁹ estimated that in one year of evolution, 25% of the patients initially managed conservatively would require surgery. In a larger study,²⁰ only 15% of the patients managed conservatively needed the surgery within 3 months. This shows the importance of initially trying the conservative approach.

In a retrospective cohort study, Saal and Saal²¹ demonstrated that the conservative management of lumbar disc herniation

with radiculopathy was considered efficacious in 90% of patients. In another study, Takada and Takahashi²² advocated that the average time for spontaneous regression of more than 50% of the herniated mass varied from between 3 and 12 months.

In this context of initial conservative treatment, it is important to consider the predictive factors of hernia disc reabsorption known. Ahn et al²³ elucidated that sequestered disc herniation regresses faster than protuse herniation. Gadolinium contrasted MR studies demonstrated that sequestered hernias tend to present rim enhancement, a sign of spontaneous regression or considerable mass reduction, in 75% of cases.^{24,25} Komori et al²⁴ showed that the more pronounced the rim enhancement, the greater the tendency of regression.

Buttermann et al²⁶ concluded that the larger the size of the herniated disc – specifically sequestered and extrude types –, the greater the percentage of regression in size. They observed that patients who responded positively to the conservative management in the first six weeks exhibited faster hernia regression, with concomitant decrease in inflammation and pain.

Radicular pain can be explained either by the nervous compression by the hernia or by radicular inflammation and blood congestion. Radicular pain relief is justifiable in some cases before the reduction in size of the hernia, as a result of the improvement of secondary inflammatory responses. Pain usually reduces in 3–6 weeks, while hernia reabsorption takes 4–9 months.²⁷

Rothoerl et al²⁸ analyzed the time of the onset of symptoms in a surgically treated group, comparing with the postoperative outcomes, to define when to indicate surgery to obtain the best possible results. The conclusion was that the conservative treatment should be tried before 2 months, during which time the pain should have already presented a regression. After this period, surgery should be considered.

Conclusion

The possibility of spontaneous disc reabsorption should be considered in cases of lumbar disc herniation, even in large and extruded ones. In cases where there are no emergency criteria for radicular decompression, conservative management should be a reasonable option for the initial treatment of these patients.

References

- Vialle LRV, Emiliano N, Henao JES, Giraldo G. Hérnia discal lombar. *Rev Bras Ortop* 2010;45(1):17–22
- Carvalho MEI, Carvalho Junior RM, Carvalho RA, Paula Junior AR. Limitação funcional em pacientes com hérnia discal lombar e o impacto na vida laboral. *Terapia Manual* 2010;38(8):320–324
- Teplick JG, Haskin ME. Spontaneous regression of herniated nucleus pulposus. *AJR Am J Roentgenol* 1985;145(2):371–375
- Sabuncuoğlu H, Ozdoğan S, Timurkaynak E. Spontaneous regression of extruded lumbar disc herniation: report of two illustrative case and review of the literature. *Turk Neurosurg* 2008;18(4):392–396
- Ellenberg M, Reina N, Ross M, Chodoroff G, Honet JC, Gross N. Regression of herniated nucleus pulposus: two patients with lumbar radiculopathy. *Arch Phys Med Rehabil* 1989;70(12):842–844
- Fager CA. Observations on spontaneous recovery from intervertebral disc herniation. *Surg Neurol* 1994;42(4):282–286
- Komori H, Shinomiya K, Nakai O, Yamaura I, Takeda S, Furuya K. The natural history of herniated nucleus pulposus with radiculopathy. *Spine* 1996;21(2):225–229
- Slavin KV, Raja A, Thornton J, Wagner FC Jr. Spontaneous regression of a large lumbar disc herniation: report of an illustrative case. *Surg Neurol* 2001;56(5):333–336, discussion 337
- Guinto FC Jr, Hashim H, Stumer M. CT demonstration of disk regression after conservative therapy. *AJNR Am J Neuroradiol* 1984;5(5):632–633
- Doita M, Kanatani T, Harada T, Mizuno K. Immunohistologic study of the ruptured intervertebral disc of the lumbar spine. *Spine* 1996;21(2):235–241
- Hirabayashi S, Kumano K, Tsuiki T, Eguchi M, Ikeda S. A dorsally displaced free fragment of lumbar disc herniation and its interesting histologic findings. A case report. *Spine* 1990;15(11):1231–1233
- Ito T, Yamada M, Ikuta F, et al. Histologic evidence of absorption of sequestration-type herniated disc. *Spine* 1996;21(2):230–234
- Haro H, Crawford HC, Fingleton B, et al. Matrix metalloproteinase-3-dependent generation of a macrophage chemoattractant in a model of herniated disc resorption. *J Clin Invest* 2000;105(2):133–141
- Doita M, Kanatani T, Ozaki T, Matsui N, Kurosaka M, Yoshiya S. Influence of macrophage infiltration of herniated disc tissue on the production of matrix metalloproteinases leading to disc resorption. *Spine* 2001;26(14):1522–1527
- Henmi T, Sairyo K, Nakano S, et al. Natural history of extruded lumbar intervertebral disc herniation. *J Med Invest* 2002;49(1–2):40–43
- Burke JG, Watson RW, McCormack D, Dowling FE, Walsh MG, Fitzpatrick JM. Spontaneous production of monocyte chemoattractant protein-1 and interleukin-8 by the human lumbar intervertebral disc. *Spine* 2002;27(13):1402–1407
- Carreon LY, Ito T, Yamada M, Uchiyama S, Takahashi HE. Neovascularization induced by annulus and its inhibition by cartilage endplate. Its role in disc absorption. *Spine* 1997;22(13):1429–1434, discussion 1446–1447
- Minamide A, Hashizume H, Yoshida M, Kawakami M, Hayashi N, Tamaki T. Effects of basic fibroblast growth factor on spontaneous resorption of herniated intervertebral discs. An experimental study in the rabbit. *Spine* 1999;24(10):940–945
- Weber H. Lumbar disc herniation. A controlled, prospective study with ten years of observation. *Spine* 1983;8(2):131–140
- Atlas SJ, Keller RB, Chang Y, Deyo RA, Singer DE. Surgical and nonsurgical management of sciatica secondary to a lumbar disc herniation: five-year outcomes from the Maine Lumbar Spine Study. *Spine* 2001;26(10):1179–1187
- Saal JA, Saal JS. Nonoperative treatment of herniated lumbar intervertebral disc with radiculopathy. An outcome study. *Spine* 1989;14(4):431–437
- Takada E, Takahashi M, Shimada K. Natural history of lumbar disc hernia with radicular leg pain: Spontaneous MRI changes of the herniated mass and correlation with clinical outcome. *J Orthop Surg (Hong Kong)* 2001;9(1):1–7
- Ahn SH, Ahn MW, Byun WM. Effect of the transligamentous extension of lumbar disc herniations on their regression and the clinical outcome of sciatica. *Spine* 2000;25(4):475–480
- Komori H, Okawa A, Haro H, Muneta T, Yamamoto H, Shinomiya K. Contrast-enhanced magnetic resonance imaging in conservative management of lumbar disc herniation. *Spine* 1998;23(1):67–73

- 25 Yamashita K, Hiroshima K, Kurata A. Gadolinium-DTPA-enhanced magnetic resonance imaging of a sequestered lumbar intervertebral disc and its correlation with pathologic findings. *Spine* 1994;19(4):479-482
- 26 Buttermann GR. Lumbar disc herniation regression after successful epidural steroid injection. *J Spinal Disord Tech* 2002;15(6):469-476
- 27 Orief T, Orz Y, Attia W, Almusrea K. Spontaneous resorption of sequestrated intervertebral disc herniation. *World Neurosurg* 2012;77(1):146-152
- 28 Rothoerl RD, Woertgen C, Brawanski A. When should conservative treatment for lumbar disc herniation be ceased and surgery considered? *Neurosurg Rev* 2002;25(3):162-165