


Evaluation of Alveolar Bone on Dental Implant Treatment using Cone Beam Computed Tomography


Edward Dwingadi¹, Yuniarti Soeroso², Robert Lessang³, Menik Priaminiarti⁴

¹Periodontology Residency Program, Faculty of Dentistry, Universitas Indonesia, Jakarta, Indonesia.  0000-0002-7338-4178

²Department of Periodontology, Faculty of Dentistry, Universitas Indonesia, Jakarta, Indonesia.  0000-0003-4660-3045

³Department of Periodontology, Faculty of Dentistry, Universitas Indonesia, Jakarta, Indonesia.  0000-0001-6997-5736

⁴Department of Oral and Maxillofacial Radiology, Faculty of Dentistry, Universitas Indonesia, Jakarta, Indonesia.

 0000-0001-6574-6928

Author to whom correspondence should be addressed: Yuniarti Soeroso, Jalan Salemba Raya No. 4, Jakarta Pusat 10430, Indonesia. Phone: +62 816832240. E-mail: yuniarti_22@yahoo.co.id.

Academic Editors: Alessandro Leite Cavalcanti and Wilton Wilney Nascimento Padilha

Received: 28 January 2019 / Accepted: 30 April 2019 / Published: 16 May 2019

Abstract

Objective: To observe the outcomes of dental implant treatment based on the evaluation of bone conditions using Cone Beam Computed Tomography (CBCT). **Material and Methods:** A total of 31 dental implants were collected for the present study. Subsequently, mesial and distal bone losses were examined, while buccal and lingual bone thickness were measured at 7 levels. Evaluation and interpretation of CBCT results was performed by 3 independent examiners.

Results: The average of mesial bone loss was 1.08 mm and 1.36 mm on distal bone. Every dental implant had lingual/palatal bone on level 1 to 3, only 1 (6.5%) didn't have bone on level 4, 3 implants (9.7%) had no bone at level 5 and 6, and 22 implants (74.2%) had no bone at level 7/implant platform. There were 8 implants (25.8%) didn't have buccal bone at level 7, only 1 implant (3.2%) didn't have buccal bone at level 2,4,5 and 6, and there were 2 implants (6.5%) had no buccal bone on level 3. Dehiscence / fenestration can be seen on 90% of the implant subjects.

Conclusion: These bone loss condition could be consequence of several factors such as infection, diagnosis, treatment plan, and operator's surgery skills. The implants that placed without CBCT could lead to operator miscalculation on bone condition, therefore in moderate to advanced cases, the use of CBCT should be mandatory for treatment plan.

Keywords: Dental Implants; Dental Implantation; Diagnostic Imaging.

Introduction

The increasing awareness of better dental prostheses makes dental implants the most favorable choice for patients, due to its comfort and its ability to prevent further bone resorption. In a previous analysis through a meta-analytic review on 19 research efforts, it was found that the average survival rates of dental implant treatments after one year was 95.5%, with a confidence level 95% [1].

The high survival rate could not be confirmed as being successful implant treatments, where the implants have no pathologic conditions and work functionally well [2]. It has been reported common parametric used to evaluate dental implant. Specifically, these are implant fixture (mobility, pain, radiolucency, and bone loss around the implant), soft tissue around implant, prostheses, and patient's subjective assessment [3].

Radiographic parametric on mesial and distal bone has been widely used for the successful evaluation of dental implants [4]. Observing a marginal bone loss of 1.5 mm on the first year and 0.2 mm on subsequent years on periapical a radiograph is considered to be normal and acceptable [4,5]. In an earlier study, it was found that 37.9% only of dental implants have buccal bone on the implant platform six months after placement, with a 0.4 mm horizontal resorption [6]. Bone loss around implants could influence both osseointegration and long-term prognosis [7,8].

The radiographic evaluation of dental implants could provide information on the: tissue surrounding the implant; degree of marginal bone loss; and condition of implant mechanic's component [9]. However, while periapical radiographs can visualize interproximal bone and bone level from an apical to a coronal view, only Cone Beam Computed Tomography (CBCT) can visualize the bone's actual three-dimensional condition [10].

The use of CBCT on dental implants could show: bone angulation and form; bone contour; bone thickness at different height levels; and the position along with the anatomical structure surrounding it [11]. Furthermore, CBCT projection can contribute to the early detection of bone loss around dental implant. This in turn can help the improvement of existing implants before further destruction occurs, as well as identify factors for the next implant placement [12].

Dental implant evaluation using CBCT was never been done before in Dental Teaching Hospital of Universitas Indonesia (Rumah Sakit Khusus Gigi Mulut Fakultas Kedokteran Gigi Universitas Indonesia) and it could be used to provide an improvement of the standard operational procedures of implant placement. In the present study, we aim at evaluating bone thickness and height around dental implants by means of CBCT.

Material and Methods

Study Design

In the present study, we performed a descriptive clinical analysis of dental implants originating from the Periodontics Clinic, Faculty of Dentistry, Universitas Indonesia between 2009 and 2016. The study was performed between June and November 2017.

The patients received Straumann dental implants, either at a bone level or at a tissue level with similar methods and surgical technique. The exclusion criteria were as follows: subjects with aggressive periodontitis; necrotizing ulcerative gingivitis (NUG); necrotizing ulcerative periodontitis (NUP); and diabetes mellitus.

Dental implants' evaluation was performed radiographically using CBCT (3D Aquitomo® 170, Morita Inc, Japan) with FOV 40x40 mm or 60x60 mm, voxel 80 µm. Evaluation and interpretation of CBCT results was performed by 3 independent examiners in the Oral and Maxillofacial Radiology Clinic, Faculty of Dentistry, Universitas Indonesia.

Data Collection

With the aim of analyzing bone level and bone thickness on mesial, distal, buccal/labial, and lingual/palatal aspects, we evaluated the projection of CBCT by using the One Volume Viewer (Morita, Japan). The mesial and distal aspect measurements were performed in sagittal view. To this end we used as reference points the dental implant platform and the first contact between crestal bone and implant. The implant platform was defined as the border between implant fixture and abutment. Straumann's tissue level implant has a 1.8 mm polished surface on the implant platform.

Therefore, the reference point was set at 1.8 mm below the implant platform. The measurement of buccal/labial and lingual/palatal started by identifying the exact position of dental implant, re-orientation, set as perpendicular on coronal view. A parallel line with the palatal or lingual plane was set to get the coronal cutting location. Alveolar bone thickness was measured from seven level (Lv) of height [13]: Lv 1 from the apical implant; Lv 2 from the most buccal aspect of apical area; Lv 3 in between mid-implant and apical; Lv 4 exactly on the mid implant; Lv 5 in between mid-implant and implant platform; Lv 6 on 2.5mm apically from the implant platform; Lv 7 on the implant platform (Figure 1).

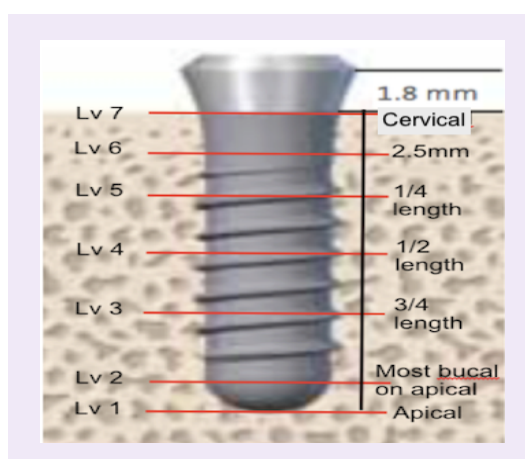


Figure 1. Illustration of bone level measurement on straumann tissue level implant.

Figure 2 shows an example of buccal and lingual bone measurement at 7 different levels performed in this experiment.

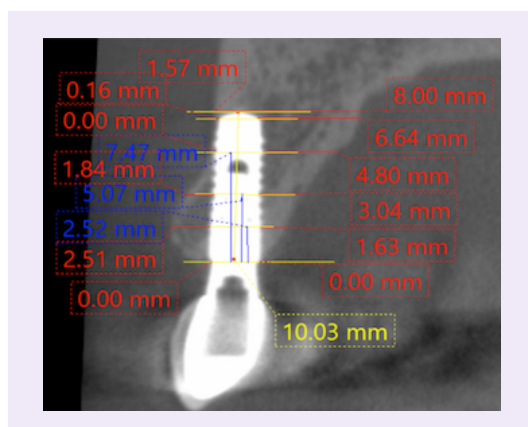


Figure 2. Buccal and lingual bone measurement at 7 different levels. The vertical yellow line measure length of the implant while blue lines help determine 2,5 mm from implant platform (Level 6), $\frac{1}{4}$ length (Level 5), $\frac{1}{2}$ length (Level 4), $\frac{3}{4}$ length (Level 3). Horizontal yellow lines were drawn perpendicular to the blue lines as guidelines and red line measures bone thickness at each level.

Data Analysis

Data were analyzed using IBM SPSS Statistics Software, version 20 (IBM Corp., Armonk, NY, USA). Descriptive statistics were used to calculate the absolute and relative frequencies, minimum and maximum values, mean, median and standard deviation. Non-parametric Wilcoxon test was used to check the Technical Error of Measurement with $p < 0.05$. Dahlberg formula was used to check validity between examiners with 1 mm difference considered acceptable.

Ethical Aspects

This research project was approved by the Ethics Research Committee of the Universitas Indonesia (33/EthicalApproval/FKGUI/VI/2017 on June 19, 2017). All the patients signed an informed consent.

Results

Table 1 describes the distribution of subjects enrolled in this study. Analytic validity among 3 examiners was performed with the Dahlberg formula in Table 2. Acceptable difference is maximum 1 mm and the results showed this data can be utilized for additional analysis (0.16 – 0.47).

Table 1. Distribution of patients according to demographic and clinical characteristics.

Variables	N (%)
Gender [14]	
Male	5 (35.7)
Female	9 (64.3)
Age (Years) [14]	
Mean (SD)	51.00 ± 10.218
Median	54
Minimum-Maximum	25 – 69
Duration of Implant Placement [31]	
Mean (SD)	4.23 ± 1.875
Median	3
Minimum-Maximum	1 – 8

Region [31]	
Anterior	5 (16.1)
Posterior	26 (83.9)
Type of Dental Implant [31]	
Bone Level	12 (38.7)
Tissue Level	19 (61.3)
Design of Dental Implant [31]	
Parallel	26 (83.9)
Tapered	5 (16.1)
Length of Dental Implant [31]	
6 mm	1 (3.2)
8 mm	14 (45.2)
10 mm	16 (51.6)
Diameter of Dental Implant [31]	
3.3 mm	8 (25.8)
3.7 mm	12 (38.7)
4.1 mm	8 (25.8)
4.7 mm	3 (9.7)
Location of Dental Implant	
Maxilla	14 (45.2)
Mandible	17 (54.8)

Table 2. Dahlberg analysis to measure validity between 3 examiners.

Differences Between Examiners	Dahlberg Formula
Examiner 1 and 2	0.20 – 0.47
Examiner 1 and 3	0.18 – 0.49
Examiner 2 and 3	0.16 – 0.40

*1 mm Differences considered acceptable.

Technical error of measurement (TEM) performed by using the non-parametric Wilcoxon analysis demonstrated that the difference between examiner 1 and 2 has the least delta score can be seen on Table 3. Therefore, the data from examiner 1 was utilized.

Table 3. Technical error of measurement with Wilcoxon analysis to measure reliability between examiners.

Differences Between Examiners	Level of Height	p-value
Examiner 1 and 2	Buccal Bone Level 5	0.027*
Examiner 1 and 3	Buccal Bone Level 3	0.025*
	Lingual Bone Level 1	0.036*
Examiner 2 and 3	Distal Bone	0.050*
	Buccal Bone Level 1	0.028*
	Buccal Bone Level 2	0.012*
	Buccal Bone Level 3	0.012*
	Buccal Bone Level 4	0.012*
	Buccal Bone Level 5	0.012*
	Lingual Bone Level 5	0.027*

*Statistically Significant.

We observed pathologic bone loss on 29.3% of the samples on the mesial aspect; 22.6% of the sample on the distal aspect. This evaluation was based on Albrektsson's criteria of bone loss. Table 4 shown average bone loss on the mesial aspect was 1.08 mm and 1.36 mm on the distal aspect.

Table 4. Average bone loss on mesial and distal.

Bone Loss	Average (SD)	Minimum – Maximum
Mesial	1.08 ± 1.06	0.00 – 5.25
Distal	1.36 ± 1.25	0.16 – 5.97

As Figures 3 and 4 show, the percentage of bone loss on the buccal and lingual area was identified. It was found that at Buccal Level 1 all subjects had bone. Only 1 subject (3.2%) did not have buccal bone on level 2, 4, 5, and 6 found, level 3 had 2 subjects (6.5%), and at level 7 got 8 subjects (25.8%) who doesn't have buccal bones at all.

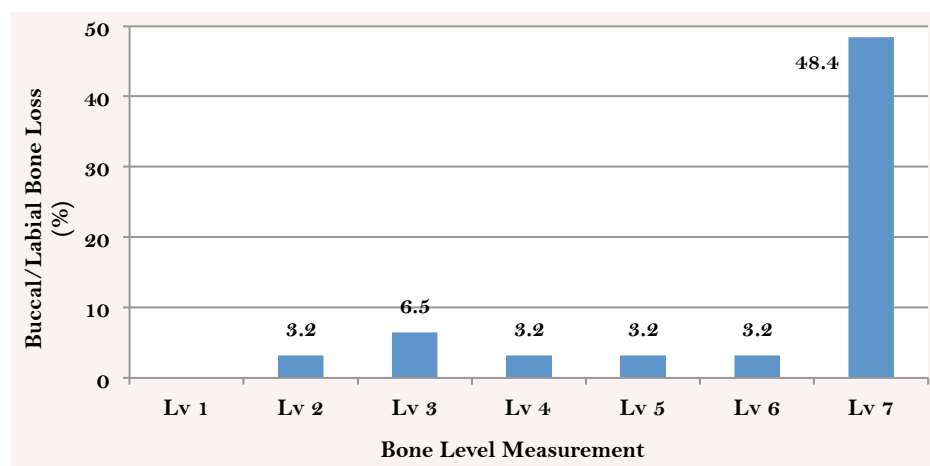


Figure 3. Buccal / labial bone loss percentage at different levels.

All subjects have lingual/palatal bone at level 1 to level 3. Two subjects (6.5%) were found without lingual bone at level 4. Level 5 and level 6 there were 3 subjects (9.7%) without lingual bone, and at level 7 there were 22 subjects (74.2%) already lost lingual/palatal bone.

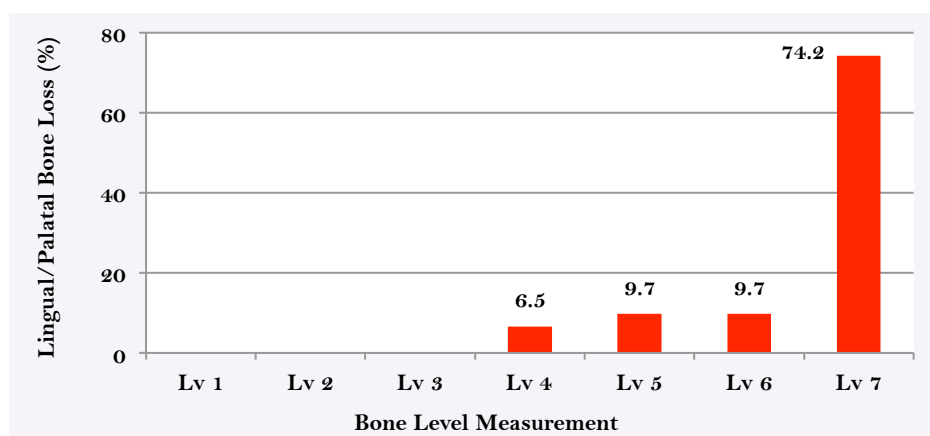


Figure 4. Lingual / palatal bone loss percentage at different levels.

Discussion

Dental implant itself still have not widely accepted in the majority of Indonesia people on account of pricewise, fear of surgery, and beliefs. In the present study we only successfully examined

31 implants due to technical factors, namely incomplete patient information on medical records made it difficult to recall, some patients moved cities, in addition to awareness of patients who are still lacking in the importance of periodic recalls. Only eight of the 14 patients who performed routine control every 6 months after implant placement were based on records in the medical record.

This is estimated because dental implant patients generally have good oral hygiene so that they do not have any periodontal problems, which causes them to feel that they do not need to carry out routine controls. After an explanation and signing of an informed consent, only 92% of patients understood the possible risks and complications, 24% of patients believed that dental implants would remain in the mouth, 12% did not understand that there was a possibility of gingival recession, peri-implantitis, implant fracture, or permanent nerve damage, and 20% were unaware that periodontal disease could affect dental implants [14].

The use of CBCT could aid in the accurate identification of peri-implant damage. Similarly, in a study performed on dogs comparing the accuracy of CBCT with histologic evaluation showed that CBCT could not identify buccal bone thickness smaller than 0.5 mm [15,16]. We observed that the average mesial bone loss was 1.08 mm and distal bone loss was 1.36 mm between one to eight years. The variation of anterior and posterior implants with wide range of time after placement could give a broad outlook of implant's bone modification throughout the time.

Albrektsson criteria was used to determined acceptable bone loss at each year of placement [5] and we found pathologic bone loss of the mesial aspect was 29% and of the distal aspect was 22.6%. These results were similar to previous findings showing that, of 4.591 dental implants after 8-10 years, 15% had more than 1.02 mm bone loss on the mesial/distal area and 5% had more than 2.28 mm bone loss [17]. Other authors get better results in 58 dental implants after 2 years of installation, the loss of bone bones was only 0.32 mm with a standard deviation of ± 0.37 mm [18]. A systematic review on dental implant placements with minimum 10-year-evaluation found a 1.3 mm average bone loss [19].

All subjects had buccal bone at level 1 at the apical dental implant, while there were 1 (3.2%) subject that had no buccal bone at levels 2, 4, 5, and 6. There were 2 dental implants (6.5 %) those who were not covered by bone at level 3 and there were 8 dental implants did not have buccal bones at level level 7 (cervical dental implants). All dental implant samples in this study had lingual / palatal bone level 1 to 3. Bone loss was seen at level 4 as many as 2 dental implants (6.5%), level 5 to 6 as many as 3 dental implants (9.7%), and the highest bone loss was found at level 7 (on platform implants), as many as 23 dental implants (74.2%) did not have lingual / palatal bone. This study found that 90% of dental implants had dehiscence or fenestration.

These results are slightly better than those found previously, which evaluated 168 dental implants in the anterior region with 56% of dental implants at level 7 (on implant platforms), 44% at level 6, 42% at level 5, 36% at level 4, 27% at level 3, 16% at level 2, and 14% at level 1 (at apical implant) with absolutely no buccal bone [13]. After an average of 8.9 years none of the dental implants they evaluated were covered with bone on the entire surface. The buccal bone is about

3.8mm more apical than the shoulder implant, but this thin or missing condition of the buccal bone clinically does not interfere with the aesthetics and stability of the dental implant [20].

Vertical bone changes measured from the implant / abutment interface after 1 year are reduced by 1.12 mm. Horizontal bone changes in the cervical implant decreased by 0.62 mm, in the middle of the implant 0.57 mm, and at the apical reduced by 0.19 mm [21]. A previous study showed that of the 66 dental implants evaluated only 37.9% had buccal bone on the implant platform after 6 months of placement. Vertical buccal resorption occurs as much as 1 mm at 6 months to 1 year and there is a horizontal resorption of 0.4 mm within 6 months of installation.

This present study limitation was the absence of bone thickness's baseline, since the radiograph taken before and immediately after implant placement were either panoramic or periapical. CBCT examination for implant placement was not mandatory before 2016 thus preliminary data not available in this study. This could provide a very important evidence to predict whether the initial placement of the dental implant was too lingual / palatal to cause bone loss occurred at the implant platform as much as 74.2% of the total sample. Operators could face challenge in diagnosing volume, contour and bone angulation due to the fact that all of the implant subjects were placed only by panoramic and bone caliper guidance. Implant treatment plan using a panoramic radiograph is not adequate since the distortion factor could made operator incorrectly predict available bones. This deficiency can have an impact on the selection of larger implants and increase the risk of injuring the adjacent anatomical structures [22].

Operator's skill and experience are also very important in determining the success of dental implant treatment [23,24]. Dental implants that are not installed by a surgeon significantly have a 2.5-5 times greater probability of failure [25]. However, a previous study found there were no statistically significant difference in the success rates of dental implants installed by resident oral surgery from various levels of residency [26].

Conclusion

We found that 90% implant subjects had dehiscence or fenestration at various bone level with concerning result of 74.2% implants did not have lingual/palatal bone at implant platform level. This could be a result of several factors such as infection, diagnosis, treatment plan, and operator's surgery skills. Only eight of the 14 patients who performed routine dental checkup every 6 months after implant placement could increase the risk of peri-implantitis.

Bone loss on the mesial and distal aspects of dental implants was observed after 1-8 years of placement found the bone loss were averagely 1.08 mm on mesial and 1.36 mm on distal. All the implants were placed without CBCT could lead to operator miscalculation on bone volume, contour, and angulation. Therefore, in moderate to advanced cases, the use of CBCT should be mandatory for treatment plan and could serves as long term evaluation reference. Dental implant evaluation using CBCT can also contribute to early detection of bone loss and help the improvement of existing implants conditions before further destruction occurs.

Authors' Contributions: Each author made significant individual contributions to this manuscript. ED performed the experiment and wrote the manuscript, RL and YS designed the study and reviewed the manuscript, and MP performed the experiments and reviewed the manuscript.

Acknowledgements: We thank Lecturer from Department of Periodontology and Oral and Maxillofacial Radiology.

Financial Support: This work was supported by grant from Universitas Indonesia (Hibah PITTA).

Conflict of Interest: The authors declare no conflicts of interest.

References

- [1] den Hartog L, Slater JJ, Vissink A, Meijer HJ, Raghoobar GM. Treatment outcome of immediate, early and conventional single-tooth implants in the aesthetic zone: A systematic review to survival, bone level, soft-tissue, aesthetics and patient satisfaction. *J Clin Periodontol* 2008; 35(12):1073-86. <https://doi.org/10.1111/j.1600-051x.2008.01330.x>
- [2] Clark D, Barbu H, Lorean A, Mijiritsky E, Levin L. Incidental findings of implant complications on postimplantation CBCTs: A cross-sectional study. *Clin Implant Dent Relat Res* 2017; 19(5):776-82. <https://doi.org/10.1111/cid.12511>
- [3] Papaspyrikados P, Chen C-J, Singh M, Weber H-P, Gallucci GO. Success criteria in implant dentistry: A systematic review. *J Dent Res* 2012; 91(3):242-8. <https://doi.org/10.1177/0022034511431252>
- [4] Albrektsson T, Buser D, Sennerby L. Crestal bone loss and oral implants. *Clin Implant Dent Relat Res* 2012; 14(6):783-91. <https://doi.org/10.1111/cid.12013>
- [5] Albrektsson T, Zarb G, Worthington P, Eriksson AR. The long-term efficacy of currently used dental implant a review and proposed criteria of success. *Int J Oral Maxillofac Implants* 1986; 1(1):11-25.
- [6] Takuma T, Oishi K, Manabe T, Yoneda S, Nagata T. Buccal bone resorption around posterior implants after surgery: A 1-year prospective study. *Int J Oral Maxillofac Implants* 2014; 29(3):634-41. <https://doi.org/10.11607/jomi.3018>
- [7] Degidi M, Nardi D, Daprile G, Piattelli A. Buccal bone plate in the immediately placed and restored maxillary single implant: A 7-year retrospective study using computed tomography. *Implant Dent* 2012; 21(1):62-6. <https://doi.org/10.1097/ID.0b013e31823fce9f>
- [8] ArRejaie A, Al-Harbi F, Alagel AS, Hassan KS. Platelet-rich plasma gel combined with bovine-derived xenograft for the treatment of dehiscence around immediately placed conventionally loaded dental implants in humans: Cone beam computed tomography and three-dimensional image evaluation. *Int J Oral Maxillofac Implants* 2016; 31(2):431-8. <https://doi.org/10.11607/jomi.3859>
- [9] Kwon JY, Kim YS, Kim CW. Assessing changes of peri-implant bone using digital subtraction radiography. *J Korean Acad Prostodontic* 2001; 39(3):273-81.
- [10] Mallya S, Tetradis S. Cone-Beam Computed Tomography: Anatomy. In: White SC, Pharoah MJ (Eds.) *Oral Radiology: Principles and Interpretation*. 7th ed. St Louis: Elsevier / Mosby, 2014. p. 214-220.
- [11] Cortes ARG, Gomes AFAM, MJAPS, Arita ES. Evaluation of linear tomography and cone beam computed tomography accuracy in measuring ridge bone width for planning implant placement. *Braz J Oral Sci* 2012; 11(2):116-9.
- [12] Salvi GE, Lang NP. Diagnostic parameters for monitoring peri-implant conditions. *Int J Oral Maxillofac Implants* 2004; 19(Suppl):116-27.
- [13] Joshi D. Long term facial alveolar bone changes associated with endosseous implants in the anterior maxilla. [Thesis]. Louisville: University of Louisville, 2016. Available at: <https://pdfs.semanticscholar.org/e272/167062c885cc76e1f9df1fcf99f81e6f63f9.pdf>. [Accessed on December 18, 2018].
- [14] Esau T, Puryer J, McNally L, O'Sullivan D. Patient understanding and recall of risks and complications of dental implant treatment following informed consent. *Faculty Dent J* 2016; 7(1):16-22. <https://doi.org/10.1308/rcsfdj.2016.16>
- [15] Kamburoğlu K, Murat S, Kılıç C, Yüksel S, Avsever H, Farman A, Scarfe WC. Accuracy of CBCT images in the assessment of buccal marginal alveolar peri-implant defects: Effect of field of view. *Dentomaxillofac Radiol* 2014; 43(4):20130332. <https://doi.org/10.1259/dmfr.20130332>
- [16] Fienitz T, Schwarz F, Ritter L, Dreiseidler T, Becker J, Rothamel D. Accuracy of cone beam computed tomography in assessing peri-implant bone defect regeneration: A histologically controlled study in dogs. *Clin Oral Implants Res* 2012; 23(7):882-7. <https://doi.org/10.1111/j.1600-0501.2011.02232.x>

- [17] French D, Larjava H, Ofec R. Retrospective cohort study of 4591 straumann implants in private practice setting, with up to 10-year follow-up. Part 1 : Multivariate survival analysis. *Clin Oral Implants Res* 2015; 26(11):1345-54. <https://doi.org/10.1111/clr.12463>
- [18] Aimetti M, Ferrarotti F, Mariani GM, Ghelardoni C, Romano F. Soft tissue and crestal bone changes around implants with platform-switched abutments placed nonsubmerged at subcrestal position: A 2-year clinical and radiographic evaluation. *Int J Oral Maxillofac Implants* 2015; 30(6):1369-77. <https://doi.org/10.11607/jomi.4017>
- [19] Moraschini V, Poubel LAC, Ferreira VF, Barboza ES. Evaluation of survival and success rates of dental implants reported in longitudinal studies with a follow-up period of at least 10 years: A systematic review. *Int J Oral Maxillofac Surg* 2015; 44(3):377-88. <https://doi.org/10.1016/j.ijom.2014.10.023>
- [20] Veltri M, Ekestubbe A, Abrahamsson I, Wennström JL. Three-dimensional buccal bone anatomy and aesthetic outcome of single dental implants replacing maxillary incisors. *Clin Oral Implants Res* 2016; 27(8):956-63. <https://doi.org/10.1111/clr.12664>
- [21] Vera C, Kok IJ De, Chen W, Reside G, Tyndall MSD, Cooper LF. Evaluation of post-implant buccal bone resorption using cone beam computed tomography: A clinical pilot study. *Int J Oral Maxillofac Implants* 2012; 27(5):1249-57.
- [22] Correa LR, Spin-Neto R, Stavropoulos A, Schropp L, da Silveira HE, Wenzel A. Planning of dental implant size with digital panoramic radiographs, CBCT-generated panoramic images, and CBCT cross-sectional images. *Clin Oral Implants Res* 2014; 25(6):690-5. <https://doi.org/10.1111/clr.12126>
- [23] Ji TJ, Kan JY, Rungcharassaeng K, Roe P, Lozada JL. Immediate loading of maxillary and mandibular implant-supported fixed complete dentures: A 1- to 10-year retrospective study. *J Oral Implantol* 2012; 38(Spec No):469-76. <https://doi.org/10.1563/AAID-JOI-D-11-00027>
- [24] Jemt T, Karouni M, Abitbol J, Zouiten O, Antoun H. A retrospective study on 1592 consecutively performed operations in one private referral clinic. Part II: Peri-implantitis and implant failures. *Clin Implant Dent Relat Res* 2017; 19(3):413-22. <https://doi.org/10.1111/cid.12481>
- [25] Jemt T. A retro-prospective effectiveness study on 3448 implant operations at one referral clinic: A multifactorial analysis. Part II: Clinical factors associated to peri-implantitis surgery and late implant failures. *Clin Implant Dent Relat Res* 2017; 19(6):972-9. <https://doi.org/10.1111/cid.12538>
- [26] Melo MD, Shafie H, Obeid G. Implant survival rates for oral and maxillofacial surgery residents: A retrospective clinical review with analysis of resident level of training. *J Oral Maxillofac Surg* 2006; 64(8):1185-9. <https://doi.org/10.1016/j.joms.2006.04.014>