



Environmental quality of an estuary in Amazon delta using immunohistochemical and morphological analyses of gill as biomarkers

Caroline da Silva Montes^{1*}, Maria Auxiliadora Pantoja Ferreira¹, Simone do Socorro Damasceno Santos² and Rossineide Martins Rocha¹

¹Laboratório de Ultraestrutura Celular, Centro de Ciências Biológicas, Universidade Federal do Pará, Campus Universitário do Guamá, Rua Augusto Corrêa, 1, 66075-900, Belém, Pará, Brazil. ²Laboratório de Fertilização in vitro, Centro de Ciência Biológicas, Universidade Federal do Pará, Belém, Pará, Brazil. *Author for correspondence. E-mail: Carolsmontes@yahoo.com.br

ABSTRACT. In this study, histological, ultrastructural, and immunohistochemical observations of the gill tissue of two fish species (*Plagioscion squamosissimus* and *Lithodoras dorsalis*) were used as biomarkers to assess the ecological conditions of an estuary in the Amazon delta, by relating the health status of the fishes to environmental quality. The gill tissue was analyzed both qualitatively and semi-quantitatively. Marked differences in the type and severity of lesions were verified between species and among study sites. A variety of severe damages were confirmed histologically in specimens from the two impacted areas (B and C), including aneurysms, epithelial lifting, and intense hyperplasia. Electron microscopy and immunohistochemical analyses also revealed injuries in the gill tissue of specimens from these two areas. While, on area A only few specimens showed mild changes in gill tissues and rare marking of apoptosis. These results confirm the urgent need for the more effective control of the discharge of pollutants into the estuary as well as more effective urban planning, given the close proximity of a major industrial complex to residential areas.

Keywords: histology, TUNEL, teleost, Barcarena, industrial effluents.

Qualidade ambiental de um estuário no delta amazônico utilizando análises imunohistoquímicas e morfológicas de brânquias como biomarcadores

RESUMO. Neste estudo foram utilizados biomarcadores histológicos, ultraestruturais e imunohistoquímicos em tecidos brânquiais de duas espécies de peixes, *Plagioscion squamosissimus* e *Lithodoras dorsalis*, para avaliar a situação ecológica em um estuário amazônico relacionando a saúde do peixe com a qualidade ambiental. O tecido branquial foi analisado qualitativamente e semiquantitativamente. Foram verificadas diferenças entre as espécies selecionadas e as áreas de estudo, no que se refere ao tipo e severidade das lesões no tecido branquial. Foi detectada uma variedade de alterações histopatológicas severas somente nos peixes capturados nas áreas B e C, tais como: Aneurisma, elevação epitelial e intensa hiperplasia. As análises de microscopia eletrônica e de imunohistoquímica confirmaram danos mais prejudiciais nas brânquias apenas nestas áreas de estudo. Enquanto que na área A poucos peixes apresentaram alterações leves nos tecidos e pouca marcação de apoptose. Estes resultados confirmam a necessidade de um efetivo controle dos dejetos de poluentes assim como um planejamento urbano eficaz nesta região, uma vez que esta área possui um complexo industrial importante próximo à área urbana.

Palavras-chave: histologia, TUNEL, teleósteos, Barcarena, efluentes industriais.

Introduction

The main causes of the degradation of aquatic systems are siltation and the dumping of pesticides and domestic and industrial waste, activities that may cause highly detrimental changes in the physical, chemical and biological characteristics of water (VAN SICKLE et al., 2006; KANU; ACHI, 2011). Effective control of these problems require the continuous monitoring of environmental quality and for this, the biological responses (biomarkers) of

aquatic organisms may provide a valuable measure of impacts, and can be used to compare change in water quality between sites and over time (PICADO et al., 2007; ABDEL-MONEIM et al., 2012).

However, assessing the adverse effects of pollutants on the environment through ecological studies of populations and communities tends to be extremely complex, and may require long periods of exposure before measurable effects arise, as well as being influence by multiple external factors. Given this, the effective analysis of initial responses to contaminants at

the molecular (FERNANDES et al., 2008) or cellular (PEREIRA et al., 2013) may provide important and rapid insights into impacts, accelerating diagnoses in time to prevent further ecological damage (BURGER et al, 2007). Biomarkers as tools to assess the effects of environmental pollution are valid for the cost - benefit and the good results (VAN DER OST et al., 2007; VIARENGO et al., 2007). It is a powerful environmental management tool that is capable of demonstrating early signs of pollutants, allowing making a projection of the effects of stressors in the environment in order to avoid them (PEAKALL; WALKER, 1994). In this context, immuno-histochemical and histological biomarkers are excellent tools for the assessment of environmental impacts.

This study investigated the occurrence of morphological and immunohistochemical alterations in the branchial tissue of two fish species – *Plagioscion squamosissimus* (Heckel, 1840), a carnivore, and *Lithodoras dorsalis* (Valenciennes, 1840), a detritivore – which were used as biomarkers for environmental impacts. The two species are among the most abundant fishes in the Amazon delta and constitute an important fishery resource for the local populations. However, they have distinct feeding behavior and gill structure, permitting a comparative perspective. Feeding ecology is reflected in gill morphology (ROY; MUNSHI, 1996; KUMARI et al., 2009), which may result in contrasting responses to exposure to pollutants. While biomarkers are widely used in studies of environmental assessment, their use in the Amazon

region is incipient, and the present study represents an important step in the application of this approach for the monitoring of the region's aquatic ecosystems.

Material and methods

The study area has a long history of anthropogenic impacts and includes a principal city, Barcarena, which has a busy shipping complex. Three areas of the estuary were selected (Figure 1), based on the findings of previous research: A – the control site, located on Onças island is more than 50 km from the impacted area and sources of pollution ($1^{\circ}26'21.26''$ S, $48^{\circ}32'29.52''$ W); B – Vila do Conde shipping terminal ($1^{\circ}34'28''$ S, $48^{\circ}47'13.9''$ W) and C – Capim Island ($1^{\circ}33'24.9''$ S, $48^{\circ}51'12.24''$ W). Both treatment sites are located in the vicinity of major industrial installations, as well as the shipping complex, through which cargoes such as fuel oil, caustic soda, and fertilizers, are transported.

The sampling of this study were licensed and funded by the federal government agency, the CNPq (National Council for Scientific and Technological Development), by the announcement "CT-HYDRO - IGRH 01/2007". The specimens' collection occurred during two months in 2010 – March, representing the rainy season, and September, the dry season. In amazon region there are only two defined seasonal periods, thereby these months represent each period.

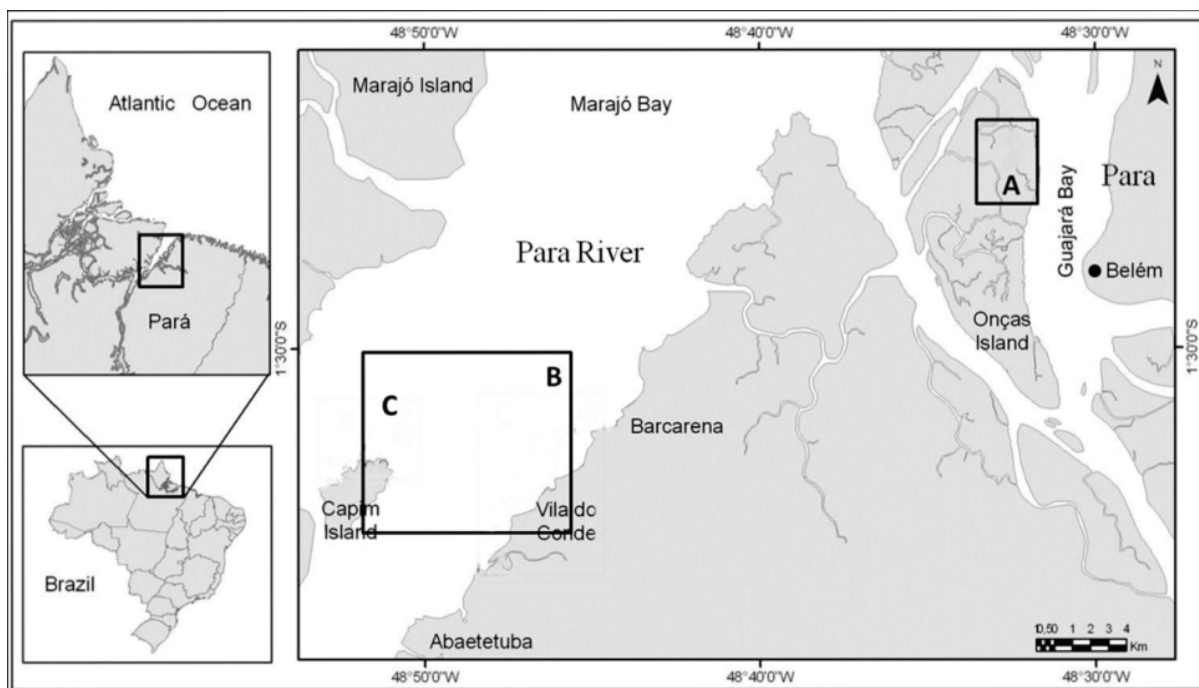


Figure 1. Study area in the Amazon estuary, Brazil, showing the points at which the specimens were collected in the present study: A – Control, B – Vila do Conde shipping terminal, and C – Capim Island.

During specimen collection, the salinity, pH, temperature (°C), and the dissolved oxygen, nitrite and nitrate concentration (mg L^{-1}) of the water were measured. Temperature and pH were measured *in situ* using a mercury thermometer and an Orion model 210 pH-meter, dissolved oxygen levels were determined in the field by the Winkler method. Surface water samples were collected using a Van Dorn-type bottle. The samples were processed (filtered and cooled) and taken to the laboratory for the quantification of nitrites and nitrates using standard procedures (APHA, AWWA, WEF, 1998).

A total of 336 juvenile specimens were collected – 176 *P. squamosissimus* and 160 *L. dorsalis*. The specimens were captured using gill nets, and were transported immediately to the laboratory, where they were measured (weight and length), and then immobilized by pinching the spinal medulla near the brain, and inspected externally and internally for major lesions. The *P. squamosissimus* specimens had a mean weight of 132.8 g and length of 26.26 cm, while those of *L. dorsalis* had a mean weight of 317.2 g and length of 28.25 cm. The second right gill arch of each animal was removed and fixed in the solution appropriate to each analysis. Gill fragments were dissected, washed in saline buffer and fixed immediately in Bouin, 4% paraformaldehyde and Karnovsky solution (paraformaldehyde 75% and glutaraldehyde 25%) for 24h.

Transmission electron microscopy and immunohistochemical analysis

The gill fragments fixed in Karnovsky solution were post-fixed with 1% osmium tetroxide, dehydrated in an ethanol gradient, critical-point-dried, and sputter-coated with a 10 nm-thick layer of gold for analysis in a LEO 910 scanning electron microscope (SEM). The other samples fixed in 4% paraformaldehyde were processed using routine histological procedures, and embedded in paraffin. The slides were processed by the TUNEL technique using Basic TACS.XL Apoptosis detection kit, treated in proteinase K, immersed in 3% hydrogen peroxide, and incubated with TdT (*Terminal Deoxynucleotidyl Transferase*) in a humid chamber at 37°C. The samples were then immersed in blocking buffer, Stop solution, anti-BrdU and strep-HRP at 37°C, then incubated in DAB solution, stained with hematoxylin and eosin (HE), and photographed using an optical microscope (Carl Zeiss Axiostar Plus 1169-151). The immunohistochemical and ultrastructural assays were classified qualitatively.

Histological analysis

The samples fixed in Bouin were dehydrated in increasing concentrations of alcohol, cleared in xylene, embedded in paraffin, stained with HE (hematoxylin and eosin), and analyzed and photographed under an optical microscope (Carl Zeiss Axiostar Plus 1169-151). The histological analyses were evaluated semi-quantitatively based on Poleksic and Mitrovic-Tutundzic (1994), in which a histological alteration index (HAI) is calculated for each specimen according to different types of tissue alterations. The alterations were grouped in three stages according to the degree of deterioration of the tissue: I (does not affect the functioning of the organ), II (severe, affects normal body functions), and III (very severe and irreversible). The HAI values were calculated from the sum of the alterations observed in each specimen, using the formula: $HAI = \sum I + 10 \times \sum II + 100 \times \sum III$. The HAI is divided into five categories: 0–10 = normal tissue; 11–40 = slight to moderate damage; 41–80 = moderate to severe damage; 81–120 = severe damage; and greater than 120 = irreparable damage.

Statistical analysis

The HAI values were compared among sites using the nonparametric Kruskal-Wallis test. Statistical differences were considered to be significant at $p < 0.05$. The analyses were run in Statistica V 6.0. The multivariate correspondence analysis was run in the PAST software.

Results

Temperature, pH, dissolved oxygen, and nitrite and nitrate concentrations fluctuated only slightly during the course of the study period, and did not vary significantly between seasons or among areas. Water temperatures ranged from 29 to 31°C, pH from 4 to 6, and dissolved oxygen concentrations from 4 mg L^{-1} to 7 mg L^{-1} , while nitrite and nitrate concentrations were 0.15–0.55 mg L^{-1} and 0.20–3.12 mg L^{-1} , respectively.

The normal macroscopic morphology was observed in all the specimens studied, although there were differences in the morphology of the gill rake, which was much sparser in *L. dorsalis* in comparison with *P. squamosissimus*.

The histological analyses revealed fundamental differences in the gill tissue of the specimens captured in area A (control) in comparison with

the other areas (B and C). The control specimens (from area A) were healthy, with gills characterized by two rows of primary lamellae supporting secondary lamellae lined with simple squamous epithelium layer, composed of pillar, mucus, and chloride cells (Figure 2A and B). The mean HAI was below 10 in both species during both seasons (Table 1), indicating that the gill tissue could be considered normal (type I).

The multivariate correspondence analysis shows the spatial differentiation of the specimens in relation to different types of histological lesions, and show that the specimens from area A were well separated from type III lesions in both seasons. The gill tissue of the specimens collected in areas B and C was characterized by a number of histological alterations, including lamellar fusion, elevation of the epithelium, and aneurysms and all the specimens had HAI values of over 100, with the specimens from area C presenting the most severe damage, with type III

lesions (Figure 2C and D). A seasonal pattern was also found. During the dry season, *L. dorsalis* presented more lesions, especially of type II, while *P. squamosissimus* was more affected during the rainy season (Figure 4).

Electron microscopy and immunohistochemical assays also found evidence of differences between areas. The gills of the specimens from area A presented superficial squamous cells, a few undifferentiated goblet mucus cells, and normal chloride cells (Figure 3A and B). By contrast, the tissue from the B and C specimens presented extensive damage in gill architecture in all the lamellae, hyperplasia, and hypertrophy (Figure 3C and D). The findings of immunohistochemical analysis clearly showed that the gill tissues of fish from disturbed areas (B and C) showed strong staining for apoptosis, whereas the tissues fishes of control area (A) presented rare marking for this technique.

Table 1. Mean and standard deviation of the Histological Alteration Index (HAI) for the gill tissue of *P. squamosissimus* and *L. dorsalis* captured in the study area: A: Control; B - Vila do Conde Shipping Terminal; C - Capim Island.

Species	Dry season			Wet season		
	A	B	C	A	B	C
<i>L. dorsalis</i>	2.23 ± 14.7	155.7 ± 54.0	169.5 ± 50.1	1.45 ± 2.9	160.5 ± 61.2	162.5 ± 39.1
<i>P. squamosissimus</i>	2.6 ± 3.57	151.43 ± 47.63	159.5 ± 55.1	1.45 ± 3.74	172.5 ± 54.63	181.5 ± 50.1

¹Different letters in the same line denote a significant difference ($p < 0.05$) between values.

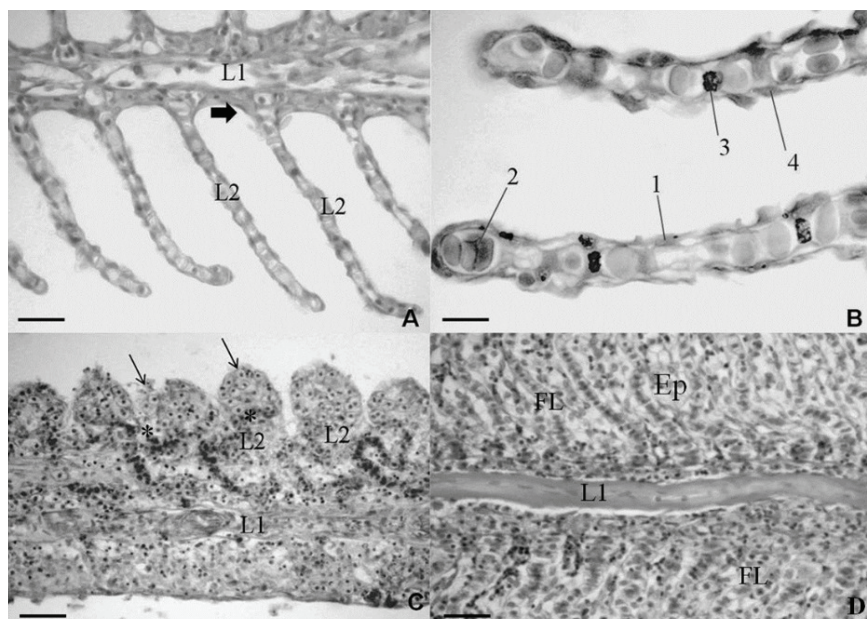


Figure 2. Photomicrography of the gills of *L. dorsalis* and *P. squamosissimus* stained with hematoxylin and eosin: (A) Control showing normal gill structure with primary (L1) and secondary lamella (L2) with a single layer of squamous cells (thick arrow) of slender appearance. Scale bar = 25 μ m; (B) Detail of a normal secondary lamella showing all cell types: 1 - squamous cell, 2 - erythrocytes, 3 - inter-lamellar cells and 4 - pillar cells. Scale bar = 20 μ m; (C) Altered gill tissue with hypertrophy (thin arrows) and early aneurysm (*) Scale bar = 50 μ m. (D) Altered gill tissue with hyperplasia causing severe lamellar fusion (FL) and elevation of the epithelium (Ep). Scale bar = 50 μ m.




Figure 3. Scanning electron microscopy (SEM) of the gills of *L. dorsalis* and *P. squamosissimus*: (A) Normal gill structure with primary (L1) and secondary lamella (L2) with slender appearance. (B) Modified gill tissue showing hypertrophy of the secondary lamellae (thin arrow). (C) Modified gill tissue showing intense hyperplasia, which has caused severe lamellar fusion (FL). (D) Detail of a gill filament showing an early stage of cell proliferation (Pc).

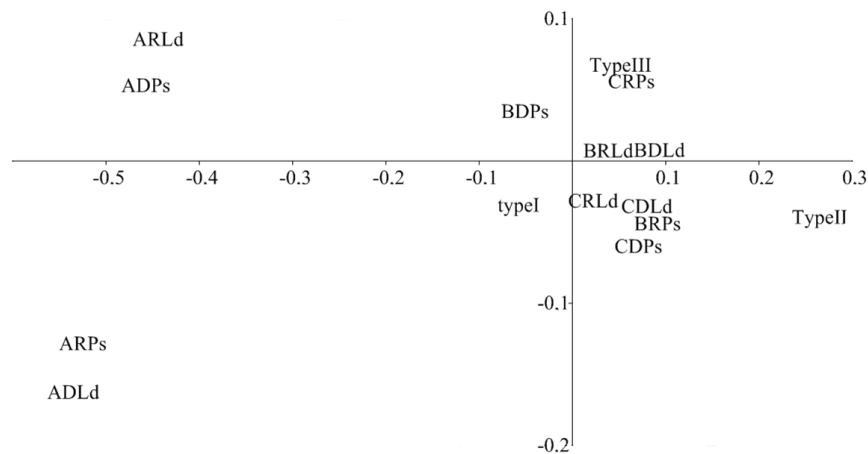


Figure 4. Multivariate diagnosis by correspondence analysis, where **ARLd** = A: (area A); R: (Rainy season); Ld: (*L. dorsalis*), **ADLd** - A: (area A); D: (Dry season); Ld: (*L. dorsalis*), **BRLd** - B: (area B); R: (Rainy season); Ld: (*L. dorsalis*), **BDLd** - B: (area B); D: (Dry season); Ld: (*L. dorsalis*), **CRLd** - C: (area C); R: (Rainy season); Ld: (*L. dorsalis*), **CDLd** - C: (area C); D: (Dry season); Ld: (*L. dorsalis*), **ARPs**: A: (area A); R: (Rainy season); Ps: (*P. squamosissimus*), **ADPs** - A: (area A); D: (Dry season); Ps: (*P. squamosissimus*), **BRPs** - B: (area B); R: (Rainy season); Ps: (*P. squamosissimus*), **BDPs** - B: (area B); D: (Dry season); Ps: (*P. squamosissimus*), **CRPs** - C: (area C); R: (Rainy season); Ps: (*P. squamosissimus*), **CDPs** - C: (area C); D: (Dry season); Ps: (*P. squamosissimus*).

Discussion

Industrial plants for the production of aluminum, fertilizer, and kaolin have been installed in the vicinity of the study area in the town of Barcarena, Brazil. The environmental impacts resulting from these industries were exacerbated by the construction of the Vila do Conde shipping terminal. The tailings from the industrial processing

of kaolin are also discharged close this area. After the kaolin processing plant was installed, local public-health agencies began to receive complaints from adjacent communities concerning changes in the characteristics of the water, reduced fishery stocks, and the occurrence of skin irritations after contact with river water. Studies in this estuary have found high concentrations of metals, especially iron and

aluminum (LIMA et al., 2011). These elements represent hazardous conditions to the health of the local population, which uses the estuary for recreation, transportation, and as a domestic water source.

Fish are often at the top of aquatic food chain and tend to concentrate metals from the environment (RUANGSOMBOON; WONGRAT, 2006). While the present study did not verify metal concentrations, the observable biological responses found in the aquatic organisms appear to provide sufficient evidence for the understanding of the harmful effects of contaminants in the study area.

The measurement of physical and chemical variables is an important approach in studies of water quality, given their potential effects on the distribution of pollutants in the environment and the vulnerability of animals to biological, physiological or behavioral alterations (OUYANG et al., 2006). The physical and chemical parameters of the water recorded in the present study satisfied the criteria established in current Brazilian legislation (CONAMA No. 357/2005, for fresh water, class 1) for water destined for human consumption following simple treatment. Despite this, the specimens from areas B and C presented major ultrastructural, immuno-histochemical, and structural alterations in their gill tissue, which indicates that the use of biomarkers, such as the analysis proposed in the present study, is a more effective approach to the assessment of water quality.

Fish gills have been used for the analysis of biological responses in many recent studies, both *in situ* (GREENFIELD et al., 2008; FASULO et al., 2010; COSTA et al., 2011; VASANTHI et al. 2013) and *ex situ* (SIMONATO et al., 2008; REISER et al., 2010; AGAMY, 2012; SINHA et al., 2014). This research has been very effective because it is able to provide a systematic link between fish health and the environment. Most specimens from area A presented slight modifications of the gill tissue, such as early stages of hypertrophy and hyperplasia, being considered to be mild to moderate alterations, whereas the specimens from areas B and C presented more pronounced and severe alterations, such as: epithelial lifting, aneurysm, rupture of the epithelial layer, and advanced hyperplasia. The lifting of the lamellar epithelial cells may be caused by the increased incidence of edemas, that is, as a defense mechanism, given that the displacement of the epithelial layer reduces the vulnerability of the surface layer, thus mitigating the toxic effects of pollutants (SCHWAIGER et al., 2004; GOMES

et al., 2012). Sonne et al. (2014) observed several serious injuries in the gills of common sculpin (*Myoxocephalus scorpius*) collected in a mining area in Maarmorilik, West Greenland. They realized that the areas with higher concentrations of lead (Pb) and zinc (Zn) in seawater, sediments and surrounding biota, presented many fishes with tissues damages, especially the fusion of secondary gill lamellae and chronic necrosis. Thus it is reasonable to assume that the combined effects of exposure to metals or other xenobiotics may cause the severe gill lesions found on fishes from areas B and C. The histological alteration index (HAI) was higher for the specimens from areas B and C, reflecting the high frequency of severe alterations observed in their gill tissue, such as aneurysms, which result in the collapse of the pillar cells. These cells are the most resistant of the gill tissue (MARTINEZ et al., 2004; EVANS et al., 2005). Bernet et al. (2004) recorded a similar pattern in brown trout (*Salmo trutta*). While these histological alterations are not related to specific toxins, they may nevertheless reflect the level of impact on the environment as a whole.

Lithodoras dorsalis presents gill morphology differentiated to be detritivore related to feeding habit (KUMARI et al., 2009). These animals showed the worst injuries during the dry season, possibly indicating that the pollutants become more concentrated in the sediments during this part of the year, leading to greater exposure in detritivorous fishes, such as *L. dorsalis*. Nascimento et al. (2012) obtained similar findings in a study of a second detritivorous fish, *Hypostomus auroguttatus*. This may indicate that detritivorous fishes are better suited for use as bio indicators of the water quality of aquatic ecosystems in the Amazon delta. The severe morphological changes observed in gill tissue of the fish from area B and C were determinant in the structural change and possibly the functioning of the organ. Accordingly, these results show a potential risk to the long-term aquatic community, since the species requires them to survive under the action of sub-lethal effects of environmental contaminants.

Scanning electron microscopy and the immunohistochemical data further reinforced the differences among areas, as recorded by Araújo et al. (2001) in *Poecilia vivipara* exposed to chemical pollutants. Alterations in tissue structure are symptoms of disorders at the molecular level within target cells, and the identification of these molecular changes is the key to the development of ultrastructural and immuno-histochemical biomarkers able to detect early responses in organisms exposed to xenobiotics (MOORE; SIMPSON, 1992).

Apoptosis is characterized by a series of morphological and biochemical events resulting from the activation of the physiological mechanisms that precede cell death, which may include cell shrinkage and the blistering of the membrane (AU et al., 2004). The TUNEL technique found no evidence of apoptosis in the gill tissue of the specimens from the control area (A), in stark contrast with those collected in areas B and C, which exhibited numerous signs of apoptosis in the gill tissue, especially in the secondary lamellae.

A study by Krumshnabel et al. (2010) with rainbow trout exposed to cadmium (Cd) in order to induce cellular response to apoptosis or necrosis concluded that under conditions of chronic exposure, fish cells follow the apoptosis path, because the organism can develop defense mechanisms. Whereas under acute conditions exposure, cells cause necrosis, since the individual does not have time enough to defend against high toxic concentration of chemical compound. These findings are consistent with those of Frenzilli et al. (2004), who evaluated the immuno-histochemical responses in fish gills in degraded environments, and reinforce the conclusion that the animals are adapting to situations of risk from the molecular to the tissue level in this industrial area.

Conclusion

This study showed that morphological and immunohistochemical biomarkers in native fish species of the Amazon region can provide excellent tools for the assessment of the quality of aquatic ecosystems. The analyses showed that the biological parameters analyzed can provide a systematic evaluation of the environmental quality of specific areas, and that the target species may represent valuable models for biomarker studies. The responses recorded in the specimens from impacted systems may reflect detrimental effects on a much wider scale. For an effective diagnosis of water quality, then, it is essential to analyze pollutant concentrations in both the fish and the water.

Acknowledgements

We are especially grateful to FAPESPA for granting a scholarship and CNPq for their financial support to the research.

References

ABDEL-MONEIM, A. M.; AL-KAHTANI, M. A.; ELMENSHAWY, O. M. Histopathological biomarkers in gills and liver of *Oreochromis niloticus* from polluted

wetland environments, Saudi Arabia. **Chemosphere**, v. 88, n. 8, p. 1028-1035, 2012.

AGAMY, E. Histopathological liver alterations in juvenile rabbit fish (*Siganus canaliculatus*) exposed to light Arabian crude oil, dispersed oil and dispersant. **Ecotoxicology and Environmental Safety**, v. 75, n. 1, p. 171-179, 2012.

APHA/AWWA/WEF-American Public Health Association; American Water Works Association; Water Environmental Federation. In: GREENBERG, A. H.; CLESCERI, L. S.; EATON, A. D. (Ed.). **Standard methods for the examination of the water and wastewater**. Washington, D.C.: APHA, 1998.

ARAÚJO, E. J. A.; MORAIS, J. O. R.; SOUZA, P. R.; SABÓIA-MORAIS, S. M. T. Efeitos de poluentes químicos cumulativos e mutagênicos durante o desenvolvimento ontogenético de *Poecilia vivipara* (Cyprinodontiformes, Poeciliidae). **Acta Scientiarum. Biological Science**, v. 23, n. 2, p. 391-399, 2001.

AU, D. W. T. The application of histo-cytopathological biomarkers in marine pollution monitoring: a review. **Marine Pollution Bulletin**, v. 48, n. 9-10, p. 817-834, 2004.

BERNET, D.; SCHMIDT-POSTHAUS, H.; WAHLI, T.; BURKHARDT HOLM, P. Evaluation of two monitoring approaches to assess effects of waste water disposal on histological alterations in fish. **Hydrobiologia**, v. 524, n. 1, p. 53-66, 2004.

BURGER, J.; FOSSIB, C.; McCLELLAN-GREENC, P.; ORLANDO, E. F. Methodologies, bioindicators, and biomarkers for assessing gender-related differences in wildlife exposed to environmental chemicals. **Environmental Research**, v. 104, n. 1, p. 135-152, 2007.

COSTA, P. M.; CAEIRO, S.; LOBO, J.; MARTINS, M.; FERREIRA, A. M.; CAETANO, M.; VALE, C.; DELVALLS, T. A.; COSTA, M. H. Estuarine ecological risk based on hepatic histopathological indices from laboratory and in situ tested fish. **Marine Pollution Bulletin**, v. 62, n. 1, p. 55-65, 2011.

EVANS, D.H.; PIERMARINI, P. M.; CHOE, K. P. The multifunctional fish gill: dominant site of gas exchange, osmoregulation, acidbase regulation, and excretion of nitrogenous waste. **Physiological Reviews**, v. 85, n. 1, p. 97-177, 2005.

FASULO, S.; MAUCERI, A.; MAISANO, M.; GIANNETTO, A.; PARRINO, V.; GENNUSO, F.; D'AGATA, A. Immunohistochemical and molecular biomarkers in *Coris julis* exposed to environmental contaminants. **Ecotoxicology and Environmental Safety**, v. 73, n. 5, p. 873-882, 2010.

FERNANDES, C.; FONTAÍNHAS-FERNANDES, A.; FERREIRA, M.; SALGADO, M. A. Oxidative stress response in Gill and liver of *Liza saliens*, from the Esmoriz-Paramos coastal lagoon, Portugal. **Archives of Environmental Contamination and Toxicology**, v. 55, n. 2, p. 262-269, 2008.

FRENZILLI, G.; SCARCELLI, V.; DEL BARGA, I.; NIGRO, M.; FORLIN, L.; BOLOGNESI, C.; STURVE, J. DNA damage in eelpout (*Zoarces viviparus*) from Göteborg harbor. **Mutation Research/Fundamental**

- and **Molecular Mechanisms of Mutagenesis**, v. 552, n. 1-2, p. 187-195, 2004.
- GOMES, I. D.; NASCIMENTO, A. A.; SALES, A.; ARAÚJO, F. G. Can fish gill anomalies be used to assess water quality in freshwater Neotropical systems?. **Environmental Monitoring Assessment**, v. 184, n. 9, p. 5523-5531, 2012.
- GREENFIELD, B. K.; TEH, S. J.; ROSS, J. R. M.; HUNT, J.; ZHANG, G. H.; DAVIS, J. A.; ICHIKAWA, G.; CRANE, D.; HUNG, S. S. O.; DENG, D. F.; TEH, F. C.; GREEN, P. G. Contaminant concentrations and histopathological effects in Sacramento splittail (*Pogonichthys macrolepidotus*). **Archives of Environmental Contamination and Toxicology**, v. 55, n. 2, p. 270-281, 2008.
- KANU, I.; ACHI, O. K. Industrial effluents and their impact on water quality of receiving rivers in Nigeria. **Journal of Applied Technology in Environmental Sanitation**, v. 1, n. 1, p. 75-86, 2011.
- KRUMSHNABEL, G.; EBNER, H. L.; WESS, W. M.; VILLUNGER, A. Apoptosis and necroptosis are induced in rainbow trout cell lines exposed to cadmium. **Aquatic Toxicology**, v. 99, n. 1, p. 73-85, 2010.
- KUMARI, U.; YASHPAL, M. S.; MITTAL, S.; MITTAL, A. K. Surface ultrastructure of gill arches and gill rakers in relation to feeding of an Indian major carp, *Cirrhinus mrigala*. **Tissue and Cell**, v. 41, n. 5, p. 318-325, 2009.
- LIMA, M. O.; SANTOS, E. C. O.; JESUS, I. M.; MEDEIROS, A. C.; FAIAL, K. C. F.; ALVES, C. N. Assessment of surface water in two Amazonian rivers impacted by industrial wastewater, Barcarena City, Pará State (Brazil). **Journal of Brazilian Chemistry Society**, v. 22, n. 8, p. 1493-1504, 2011.
- MARTINEZ, C. B. R.; NAGAE, M. Y.; ZAIA, C. T. B. V.; ZAIA, D. A. M. Morphological and physiological acute effects of lead in the neotropical fish *Prochilodus lineatus*. **Brazilian Journal of Biology**, v. 64, n. 4, p. 797-807, 2004.
- MOORE, M. N.; SIMPSON, M. G. Molecular and celular pathology in environmental impact assessment. **Aquatic Toxicology**, v. 22, n. 4, p. 313-322, 1992.
- NASCIMENTO, A. A.; ARAÚJO, F. G.; GOMES, I. D.; MENDES, R. M. M.; SALES, A. Fish gills alterations as potential biomarkers of environmental quality in a eutrophized tropical river in South-Eastern Brazil. **Anatomia Histologia Embryologia**, v. 41, n. 3, p. 209-216, 2012.
- OUYANG, Y.; NKEDI-KIZZA, P.; WU, Q. T.; SHINDE, D.; HUANG C. H. Assessment of seasonal variations in surface water quality. **Water Research**, v. 40, n. 20, p. 3800-3810, 2006.
- PEAKALL, D. B.; WALKER C. H. The role of biomarkers in environmental assessment (3): vertebrates. **Ecotoxicology**, v. 3, n. 3, p. 173-179, 1994.
- PEREIRA, S.; PINTO, A. L.; CORTES, R.; FONTAINHAS-FERNANDES, A.; COIMBRA A. M.; MONTEIRO, S. M. Gill histopathological and oxidative stress evaluation in native fish captured in portuguese northwestern rivers. **Ecotoxicology and Environmental Safety**, v. 90, p. 157-166, 2013.
- PICADO, A.; BEBIANNO, M. J.; COSTA, M. H.; FERREIRA A.; VALE C. Biomarkers: a strategic tool in the assessment of environmental quality of coastal Waters. **Hydrobiologia**, v. 587, n. 1, p. 79-87, 2007.
- POLEKSIC, V.; MITROVIC-TUTUNDZIC, V. Fish gills a monitor of sublethal and choronic effects of pollution. In: MULLER, R.; LLOYD, R. (Ed.). **Sublethal and chronic effects of pollutants of freshwater fish**. Oxford: FAO Fishing News Books, 1994. p. 339-352.
- REISER, S.; SCHOROEDER, J. P.; WUERTZ, S.; KLOAS, W.; HANEL, R. Histological and physiological alterations in juvenile turbot (*Psetta maxima*, L.) exposed to sublethal concentrations of ozone-produced oxidants in ozonated seawater. **Aquaculture**, v. 307, n. 1-2, p. 157-164, 2010.
- ROY, P. K.; MUNSHI, J. S. D. Morphometrics of the respiratory system of air-breathing fishes of India. In: MUNSHI, J. S. D.; DUTTA, H. M. (Ed.). **Fish morphology**. Horizon of new research. Rotterdam: AA Balkema, 1996.
- RUANGSOMBOON, S.; WONGRAT, L. Bioaccumulation of cadmium in an experimental aquatic food chain involving phytoplankton (*Chlorella vulgaris*), zooplankton (*Moina macrocopa*), and the predatory catfish *Clarias macrocephalus* × *C. gariepinus*. **Aquatic toxicology**, v. 78, n. 1, p. 15-20, 2006.
- SCHWAIGER, J.; FERLING, H.; MALLOW, U.; WINTERMAYR, H.; NEGELE, R. D. Toxic effects of the non-steroidal anti-inflammatory drug diclofenac. Part I. Histopathological alterations and bioaccumulation in rainbow trout. **Aquatic Toxicology**, v. 68, n. 2, p. 141-150, 2004.
- SIMONATO, J. D.; GUEDES, C. L. B.; MARTINEZ, C. B. R. Biochemical, physiological, and histological changes in the neotropical fish *Prochilodus lineatus* exposed to diesel oil. **Ecotoxicology Environmental Safety**, v. 69, n. 1, p. 112-120, 2008.
- SINHA, A. K.; MATEY, V.; GIBLEN, T.; BLUST, R.; De BOECK, G. Gill remodeling in three freshwater teleosts in response to high environmental ammonia. **Aquatic Toxicology**, v. 155, p. 166-180, 2014.
- SONNE, C.; BACH, L.; SONDERGAARD, J.; RIGET, F. F.; DIETZ, R.; MOSBECH, A.; LEIFSSON, P. S.; GUSTAVSON, K. Evaluation of the use of common sculpin (*Myoxocephalus scorpius*) organ histology as bioindicator for element exposure in the fjord of the mining area Maarmorilik, West Greenland. **Environmental Research**, v. 133, n. 1, p. 304-311, 2014.
- VAN DER OOST, R.; BEYER, J.; VERMEULEN, N. P. E. Fish bioaccumulation and biomarkers in environmental risk assessment: a review. **Environmental Toxicology and Pharmacology**, v. 13, n. 2, p. 57-149, 2003.
- VAN SICKLE, J.; STODDARD J. L.; PAULSEN S. G.; OLSEN A. R. Using relative risk to compare the effects of aquatic stressors at a regional scale. **Environmental Management**, v. 38, n. 6, p. 1020-1030, 2006.

VASANTHI, L. A.; REVANTHI, P.; MINI, J.; MUNUSWAMY, N. Integrated use of histological and ultrastructural biomarkers in *Mugil cephalus* for assessing heavy metal pollution in Ennore estuary, Chennai. **Chemosphere**, v. 91, n. 8, p. 1156-1164, 2013.

VIARENGO, A.; LOWE, D.; BOLOGNESI, C.; FABBRI, E.; KORHLER, A. The use of biomarkers in biomonitoring: a 2-tier approach assessing the level of pollutant-induced stress syndrome in sentinel organisms. **Comparative**

Biochemistry and Physiology Part C: Toxicology and Pharmacology, v. 146, n. 3, p. 281-300, 2007.

Received on July 29, 2014.

Accepted on November 11, 2014.

License information: This is an open-access article distributed under the terms of the Creative Commons Attribution License, which permits unrestricted use, distribution, and reproduction in any medium, provided the original work is properly cited.