

EFFECTS OF PNEUMOPERITONEUM AND TRENDELENBURG POSITION ON INTRAOCULAR PRESSURE (IOP) IN ISOFLUORANE ANESTHETISED CATS

EFEITOS DO PNEUMOPERITÔNIO E DA POSIÇÃO DE TRENDELENBURG SOBRE A PRESSÃO INTRAOCULAR (PIO) EM GATOS ANESTESIADOS COM ISOFLURANO

Arilton Teodoro de SOUZA¹; Débora de Oliveira GARCIA¹; Lilian Toshiko NISHIMURA¹; Marcos Lúcio MAGALHÃES¹; Ewaldo MATTOS-JUNIOR¹; Daniel PAULINO-JUNIOR¹; Adriana Torrecilhas JORGE¹; Cristiane dos Santos HONSHO^{1*}

1. Postgraduate Program in Veterinary Science at the University of Franca – UNIFRAN, Franca, SP, Brazil.
cristiane.honsho@unifran.edu.br

ABSTRACT: The aim of this study was to determine whether a pneumoperitoneum of 10 mmHg combined or not with the Trendelenburg position could lead to significant changes in intraocular pressure (IOP), ocular pressure perfusion (OPP), and cardiorespiratory variables; as well as determine whether a correlation exists between IOP and mean arterial blood pressure (MAP), and/or partial pressure of carbon dioxide in arterial blood (PaCO₂) in cats. Animals were allocated in two groups (n=7/group): GC (without inclination) and GTREN (Trendelenburg position). The variables were recorded before (baseline) and during 30 minutes (T5-T30) after insufflation. In GTREN, a reduction in heart rate was observed at T5 and in respiratory rate at T5 and T15. There was an increase in IOP at T5-T30 in comparison to baseline. There was a reduction in potential of hydrogen in arterial blood in both groups at all times in comparison to baseline. Partial pressure of carbon dioxide in arterial blood was increased at T15-T30 in GC and at T5-T30 in GTREN. In conclusion, the pneumoperitoneum of 10mmHg CO₂ did not significantly affect IOP or OPP in cats anaesthetised with isoflurane and kept under spontaneous ventilation. However, induced pneumoperitoneum combined with Trendelenburg position resulted in an increase in IOP in cats subjected to the same anaesthetic conditions, but did not affect OPP.

KEYWORDS: Intra-abdominal pressure. Body position. Ocular alterations. Pressure. Videolaparoscopy. Videosurgery.

INTRODUCTION

Video-assisted procedures provide several benefits to conventional surgeries, one of which is being minimally invasive (CASE et al., 2015), but require the establishment of pneumoperitoneum and/or Trendelenburg position, can cause cardiac output reduction and increase of PaCO₂ (LEME et al., 2002; PEDROSO et al., 2007).

Several studies have analysed the influence of Trendelenburg position on the increase in IOP in several species (AWAD et al., 2009; HONSHO et al., 2013), including the loss of vision in humans subjected to this position for long periods (AWAD et al., 2009; KUMAR; VYAKARNAM, 2013). However, little has been reported of its effects on the IOP in cats.

The combination of pneumoperitoneum and Trendelenburg position can lead to physiological alterations like increase of MAP, PaCO₂, and IOP that can result in ischemic lesions of the optical

nerve associated with blindness (KUMAR; VYAKARNAM, 2013; BASSO et al., 2014) especially in the presence of alterations that could influence the ocular pressure perfusion (OPP) such as pre-existing cardiorespiratory diseases, hypervolemia or haemodilution (MOLLOY, 2011).

This study aimed to evaluate if a pneumoperitoneum of 10 mmHg combined or not with the Trendelenburg position could lead to significant changes in IOP, OPP, and cardiorespiratory variables; as well as determine whether a correlation exists between IOP and MAP, and/or PaCO₂ in cats.

MATERIAL AND METHODS

Fourteen (3 males and 11 females) healthy young adult cats of mixed breed and weighing 2.8 ± 0.9 kg were used in this study. The animals were obtained from the São Francisco Veterinary Hospital, Mogi Mirim – SP, Brazil and included in

the study following a verbal and written consent by the owners. The animals were subjected to clinical examination and laboratory analysis. The study took place at the University of Franca, Franca/SP, Brazil. An eight-hour fasting was implemented prior to the study.

The animals were allocated in random order into two groups (n=7), Control (GC - 180° dorsal decubitus - no inclination) and Trendelenburg (GTREN - dorsal decubitus at 20° Trendelenburg position (head-down tilt). All groups were subjected to an induced pneumoperitoneum of 10 mmHg with carbon dioxide (CO₂). The inclination angle was obtained using a protractor.

Induction to anesthesia was performed with isoflurane in concentration previously established in pilot study (inspired fraction = 3,6%) using an induction box. After appropriate *mandibular relaxation*, the trachea was *intubated* with a Magill endotracheal tube and connected to Mapleson's D breathing system. Anesthesia was maintained with isoflurane (diluted in 100% oxygen at 100 mL/kg/min) in concentration determined by stage of anaesthesia based on rotation of the ocular globe, HR and MAP. All animals' receive intravenous Ringer Lactate solution (5 mL/kg/hour) during the observation period.

A *Veress* needle was inserted in the umbilical region and the *linea alba* and connected to the insufflator, generating a CO₂ pneumoperitoneum of 10 mmHg at 1 L/min.

Intraocular pressure (right and left) was determined by applanation tonometry using Tono-Pen Avia™ (Reichert Inc., NY, USA) after instillation of 0.5% proparacaine anaesthetic eye drops (Anestalcon – Alcon Lab. Brasil Ltda, São Paulo, Brazil). Analysis took place between 1 and 6 pm and the equipment was calibrated according to the manufacturer's recommendations prior to the start of the study. At least three measurements were recorded, with a 5% error margin. Readings were taken by the same experienced professional, with animals in dorsal decubitus and the head positioned at the level of the thoracic vertebrae. OPP was considered as the difference between IOP and MAP.

Heart rate (HR, bpm – beats per minute) was determined using a digital electrocardiograph (TEB, ECGPC, São Paulo, Brazil) in which the R-R interval during 1 minute. Mean arterial blood pressure (MAP - mmHg – millimetres of mercury) was evaluated using the catheter percutaneous inserted in left or right medial tarsal artery and connected to a system filled with 0.1% heparin solution (50 IU/mL). Pressure was measured

intermittently using a monitor (Dash 4000, GE HealthCare, UK), which was calibrated against a mercury column before use. Prior to measurement, the system was zeroed using the air-saline junction at the point of the shoulder in dorsal recumbent animals in the xiphoid process as reference points. Rectal temperature (RT, °C) was determined by a clinical thermometer (Termômetro Clínico BD, BD, MG, Brazil) and *f* (bpm – breaths per minute) determined by the number of chest movements observed in 1 minute.

Arterial blood gas analysis [pHa, PaCO₂, PaO₂ (mmHg), HCO₃⁻, BE (mmol/L) and SaO₂ (%) were determined by heparinised samples (0.5 mL) collected from the catheter in the tarsal artery used to measure arterial pressure and immediately analysed using a blood pH and gas analyser (Cobas b 121 Roche®, Basileia, Switzerland).

The variables were recorded before any medication (T0), immediately before insufflation (TBINS), and at 5 (T5), 15 (T15), and 30 minutes after insufflation (T30). Following data collection, the animals underwent ovariectomy or orchiectomy.

Data are expressed as mean ± standard deviation. Comparisons within the groups at the different times were performed using ANOVA and Bonferroni post-hoc test. Comparison between the groups at the different times was performed by paired t-test. Analysis was carried out using the statistical program GraphPad PRISM v. 5 (GraphPad Software, Inc, La Jolla, CA, USA). Significance was considered at 5% (P≤0.05).

RESULTS

The time TBINS was considered baseline for statistical analysis and comparison of variables within the groups. As there were no significant differences in IOP between the right and left eyes, the data from both were grouped together. The mean inspired fraction of isoflurane was 1.6 ± 0.2%. Mean values of the HR, *f*, RT, MAP, CVP, blood gas analysis and OPP are presented in Table 1.

In GTREN, there was a significant (P=0.035) reduction in HR at T5. Mean *f* in GTREN was significantly (P=0.007) lower at T5 and T15. In GTREN mean *f* was significantly lower than in GC at T5 (P=0.003) and T15 (P=0.040). There was a significant reduction in RT in GC (P<0.0001) and GTREN (P<0.0001) at T5-T30. In GTREN, RT was significantly lower than GC at T15 (P=0.036) and T30 (P=0.007). In GC, there was a significant (P=0.039) increase in MAP at T15.

Table 1. Mean \pm SD of heart rate (HR), respiratory rate (f), rectal temperature (RT), mean arterial pressure (MAP), central venous pressure (CVP), potential hydrogen in arterial blood (pHa), partial pressure of carbon dioxide in arterial blood (PaCO₂), partial pressure of oxygen in arterial blood (PaO₂), oxygen saturation of arterial blood (SaO₂), bicarbonate (HCO₃⁻) and base excess (BE) in cats anaesthetised with isoflurane and kept under spontaneous ventilation, and subjected to induced pneumoperitoneum of 10 mmHg alone (GC) or combined with 20° Trendelenburg position (GTREN) at different times of evaluation.

Variable	Group	T0	TBINS	T5	T15	T30	P(ANOVA)
HR (bpm)	GC	177 \pm 5	150 \pm 3	153 \pm 2	148 \pm 2	140 \pm 1	0.255
	GTREN	184 \pm 8	157 \pm 2	139 \pm 3*	142 \pm 3	147 \pm 3	0.035
f (bpm)	GC	43 \pm 12	29 \pm 9	25 \pm 8	27 \pm 10	23 \pm 11	0.299
	GTREN	53 \pm 24	23 \pm 8	14 \pm 7*	17 \pm 5*	18 \pm 7	0.007
RT (°C)	GC	38.2 \pm 0.9	37.6 \pm 0.7	36.9 \pm 0.72*	37 \pm 0.7*	36.5 \pm 0.6*	0.0001
	GTREN	37.7 \pm 0.6	37 \pm 0.7	36.2 \pm 0.4*	36.1 \pm 0.3*	35.7 \pm 0.4*	0.0001
MAP (mmHg)	GC	-	65 \pm 9	78 \pm 15	75 \pm 11*	72 \pm 6	0.039
	GTREN	-	75 \pm 21	70 \pm 22	73 \pm 30	75 \pm 22	0.540
CVP (cmH ₂ O)	GC	-	7 \pm 4	4 \pm 3	5 \pm 3	5 \pm 5	0.353
	GTREN	-	2 \pm 2	2 \pm 4	1 \pm 4	0.28 \pm 3.81	0.200
pHa	GC	-	7.29 \pm 0.06	7.23 \pm 0.09*	7.20 \pm 0.1*	7.18 \pm 0.09*	0.0002
	GTREN	-	7.31 \pm 0.08	7.19 \pm 0.08*	7.18 \pm 0.08*	7.18 \pm 0.09*	0.0003
PaCO ₂ (mmHg)	GC	-	39 \pm 7	48 \pm 16	53 \pm 16*	54 \pm 15*	0.002
	GTREN	-	37 \pm 7	53 \pm 10*	56 \pm 13*	55 \pm 13*	0.0002
PaO ₂ (mmHg)	GC	-	359 \pm 51	397 \pm 80	364 \pm 71	353 \pm 83	0.204
	GTREN	-	304 \pm 145	404 \pm 58	381 \pm 37	352 \pm 9	0.128
SaO ₂ (%)	GC	-	99 \pm 0	99 \pm 0	99 \pm 0	99 \pm 0	0.063
	GTREN	-	99 \pm 1	99 \pm 0	98 \pm 0	99 \pm 0	0.329
HCO ₃ ⁻ (mmol/L)	GC	-	18 \pm 1	19 \pm 2	19 \pm 2	19 \pm 1.8	0.343
	GTREN	-	18 \pm 0.7	20 \pm 1*	20 \pm 1.6*	20 \pm 1.6*	0.002
BE (mmol/L)	GC	-	-7.7 \pm 1.6	-7.9 \pm 1.8	-9.9 \pm 4.8	-8.8 \pm 1.8	0.202
	GTREN	-	-7.0 \pm 1.7	-8 \pm 2.2	-8.3 \pm 2.2*	-8.3 \pm 2.1*	0.0001
OPP (mmHg)	GC	-	45 \pm 9	56 \pm 13	53 \pm 10	52 \pm 6	0.210
	GTREN	-	57 \pm 21	58 \pm 21	38.9 \pm 21	45 \pm 22	0.292

SD: Standard deviation.; bpm: beats per minute – HR or breaths per minute - f ; - Not available; * Significant difference in comparison to baseline (TBINS). Significance was considered at $P \leq 0.05$.

There was a significant reduction in pHa in GC ($P=0.0002$) and GTREN ($P=0.0003$) at T5-T30. In GC, PaCO₂ was significantly ($P=0.002$) increased at T15 and T30 while in GTREN it was significantly ($P=0.0002$) higher than TBINS at all times. In GTREN, HCO₃⁻ was significantly ($P=0.002$) higher at T5-T30. There were a significant difference in BE in GTREN at T15 and T30 ($P=0.0001$)

In GTREN, IOP was significantly ($P<0.0001$) higher at T5, T15, and T30

comparatively to baseline. In GTREN this parameter was significantly ($P=0.005$) higher at T30 than in GC (Figure 1).

There was a weak positive correlation between IOP and MAP ($r = 0.459$) but no significant correlation was observed between PaCO₂ and IOP ($r = - 0.05$). No significant variation was observed in others parameters analysed.

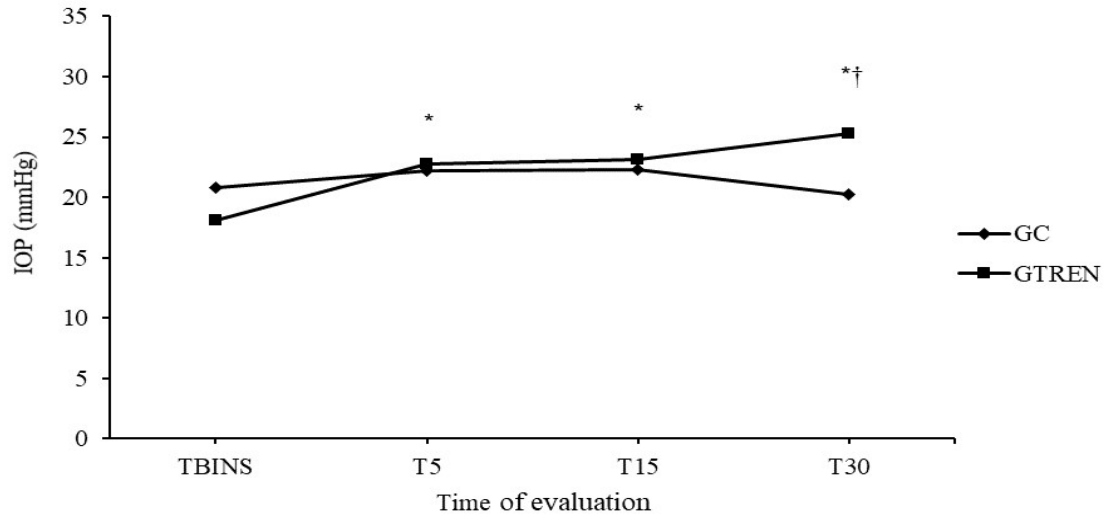


Figure 1. Mean values of the intraocular pressure (IOP) in cats submitted to pneumoperitoneum alone (GC) and combined with Trendelenburg position (GTREN) in different time of evaluation (TBINS: before insufflation, five, ten and third minutes after insufflation T5, T10 and T15, respectively). *Significantly different from TBINS within the same treatment ($p < 0.0001$). †Significantly different from other group at the same time point ($p = 0.010$).

DISCUSSION

The present study hypothesized that pneumoperitoneum, alone or combined with o Trendelenburg position, could lead to significant changes in IOP. The 30-minute observation period adopted in this study was based on the average time reported for elective video-laparoscopic procedures in animals (CASE et al., 2015). Video-laparoscopic procedures must begin with the patient at 180° and the Trendelenburg position used only when strictly necessary, and never at an angle greater than 45° (BRUN, 2015).

The use of mechanical ventilation in video-surgery procedures is common (PEDROSO et al., 2007), however, there is a possibility of respiratory acidosis, as a result of the pneumoperitoneum diaphragmatic compression and potencilized by the respiratory depressant action of the inhaled anesthetic. The decision to keep the animals under spontaneous ventilation was based on the lack of significant clinical alterations reported in cats subjected to induced pneumoperitoneum under this type of ventilation (ANDRADE JUNIOR, 2009; CASE et al., 2015), nevertheless the data of this study showed a temporal respiratory depress with moderate respiratory acidosis.

Studies in cats have reported the use intra-abdominal pressure (IAP) of 6-12 mmHg (HONSHO et al., 2013; PINTO FILHO et al., 2014; CASE et al., 2015); the use of IAP of 10 mmHg was based in a previous study reported is sufficient for

an abdominal procedure in cats (NORMANDO et al., 2006).

Isoflurane did not cause significant changes in the HR of cats kept under spontaneous ventilation for 90 minutes (HIKASA et al., 1996). In isoflurane anesthetized cats and induced CO₂ pneumoperitoneum (6 and 12 mmHg), observed an increase in HR in the first 15 minutes (ANDRADE JUNIOR, 2009). An increase in HR is often observed as a compensatory mechanism to the reduction in cardiac deficit; however, the results from the present study did not follow this tendency, probably due to a different compensatory mechanism (ALMEIDA et al., 2003).

In patients submitted to pneumoperitoneum, it is common to observe an increase in f (LEME et al., 2002) due to the reduction in pulmonary complacency and increase in PaCO₂ (NORMANDO et al., 2006; LEME et al., 2002). Andrade Junior (2009) reported that respiratory rate remained unchanged in cats subjected to induced pneumoperitoneum of 6 and 12 mmHg; contrary to the observed in this study, in which a reduction in f was observed in GTREN. This reduction could be due to vagal stimulation, as HR also decreased at the same time in this group.

Reduction in cardiac deficit and venous return, hormonal action and, induced by anesthetic drugs are the main factors involved in changes in arterial pressure (ALMEIDA et al., 2003). In spontaneously breathing cats anesthetized with isoflurane (1.5%) during 90 minutes, did not occur significant changes in MAP (HIKASA et al., 1996).

An increase in MAP has been reported in humans (PEDROSO et al., 2007) and rats during induced pneumoperitoneum (BOTTER et al., 2005). In the present study, as a similar report by Andrade Junior (2009), MAP was increased in control group, probably as a consequence of the pneumoperitoneum.

Pneumoperitoneum reduces venous return and increase CVP, consequently, there is an increase in episcleral venous pressure (LENTSCHENER et al, 1998; AWAD et al., 2009; MONDZELEWSKI et al., 2015), which associated with high free CO₂ in the abdominal cavity results in an increase in IOP (LENTSCHENER et al, 1998; AWAD et al., 2009; HOSHIKAWA et al., 2014). This raise in IOP can be aggravated by time and by the Trendelenburg position, as observed in this study, in which pneumoperitoneum alone did not significantly affect IOP but significant changes were observed in animals subjected to Trendelenburg position (AWAD et al., 2009; MONDZELEWSKI et al., 2015). In rabbits and humans submitted to pneumoperitoneum and/or trendelenburg position were noted increase in the IOP (LENTSCHENER et al., 1998; AWAD et al., 2009).

The mean values of IOP observed in this study were within the normal range for cats, the increase in IOP in GTREN suggests that from this time onwards the variations in IOP would have been more significant had this variable been analysed for longer. Thus, further studies in cats are needed to determine the behaviour of this and other variables for longer periods of time, since the period during which patients are kept in Trendelenburg position and the increase in IOP are determining factors in the occurrence and severity of visual changes in these patients (LENTSCHENER et al, 1998; AWAD et al., 2009; HOSHIKAWA et al., 2014.).

Changes in OPP are of clinical significance, as if increased for long periods of time it can cause ischemia of the optic nerve leading to blindness (TANI et al., 2014), as reported in humans following video-laparoscopic procedures (KUMAR; VYAKARNAM, 2013). In the present study, neither of the groups showed alterations in OPP, demonstrating that even though IOP increased due to the Trendelenburg position, it was not enough to significantly affect OPP.

An increase in PaCO₂ is expected in video-assisted procedures, as it is related to the absorption of free CO₂ (ALMEIDA et al., 2003; LEMOS et al., 2003; BOTTER et a., 2005; AWAD et al., 2009) in the abdomen, the difficulty in breathing caused by the intra-abdominal pressure (LEME et al., 2002; BOTTER et a., 2005; NORMANDO et al., 2006).

The regulation of blood pH occurs by ventilation and metabolic mechanisms; through the elimination of CO₂ and re-absorption of bicarbonate, respectively. Therefore, a disruption in the elimination of CO₂ leads to increases in [HCO₃⁻] (DiBARTOLA, 2011). In the present study, these effects were evident in animals from GTREN, in which respiratory acidosis with activating compensatory components was present, although it was incapable of controlling pH. Both groups showed an increase in PaCO₂; but in GTREN it was significantly increased in all times of evaluation, suggesting that the Trendelenburg position can intensify the changes caused by the pneumoperitoneum.

Hypoxemia (PaO₂ < 60 mmHg) it's a common disorder in airless patients (BOTTER et al., 2005). PaO₂ unchanged in both groups, it can be suggested that even though the pneumoperitoneum and the Trendelenburg position were unable to significantly affect the availability of PaO₂, but the animals received 100% oxygen and, others ventilation variables were not analyzed; therefore, it was not possible to evaluate whether hypoxaemia occurred.

A previous study has demonstrated correlation between IOP and PaCO₂ (TALIERI et al., 2005). However, in the present study this correlation was not observed. Furthermore, there was a poor correlation between IOP and MAP, corroborating with Ozcan et al. (2004), and thus suggesting that gravity was the main cause of the increase in IOP in the present study.

It was evident that the Trendelenburg position caused significant changes in IOP, even though its values were within the physiological range. It also led to important changes in pH and PaCO₂, suggesting that the combination of induced pneumoperitoneum and Trendelenburg position should not be used in circumstances similar to those of this study. However, these results must be interpreted with caution to practice clinical application, due to the limited number of animals used, ventilation, and haemodynamic variables that could have provided a more accurate interpretation of the results.

It can be concluded that an induced pneumoperitoneum of 10mmHg CO₂ did not significantly affect IOP or OPP in cats anaesthetised with isoflurane and kept under spontaneous ventilation. However, induced pneumoperitoneum combined with Trendelenburg position resulted in an increase in IOP in cats subjected to the same anaesthetic conditions, but did not affect OPP. No

correlation was observed between MAP and IOP, and PaCO₂ hardly influenced the later.

Bioethics And Committee Approval Biossecurity

Ethics Committee for the Use of Animals (CEUA-UNIFRAN, Franca-SP, Brazil) has approved the methods employed in this study (Protocol n. 036/13).

ACKNOWLEDGEMENT

This study was financed in part by the Coordenação de Aperfeiçoamento de Pessoal de Nível Superior (CAPES 1267979), and Fundação de Amparo à Pesquisa do Estado de São Paulo (FAPESP 2014/09250-2)

RESUMO: O objetivo deste estudo foi determinar se o pneumoperitônio de 10 mmHg associado, ou não, à posição de Trendelenburg poderia levar a alterações significativas na Pressão Intraocular (PIO), Pressão de Perfusão Ocular (PPO) e variáveis cardiorrespiratórias, bem como determinar se havia correlação entre a PIO e a Pressão Arterial Média (PAM) e/ou Pressão Parcial de Dióxido de Carbono no Sangue Arterial (PaCO₂) em gatos. Os animais foram alocados em dois grupos (n = 7/grupo): GC (sem inclinação) e GTREN (posição de Trendelenburg). As variáveis foram registradas antes (linha de base) e durante 30 minutos (T5-T30) após a insuflação. No GTREN, foi observada redução na frequência cardíaca em T5 e, na frequência respiratória, em T5 e T15. Houve aumento da PIO no T5-T30 comparativamente ao valor basal. Houve redução no Potencial de Hidrogênio no sangue arterial em ambos os grupos em todos os momentos comparativamente à linha de base. A Pressão Parcial de Dióxido de Carbono no sangue arterial aumentou em T15-T30 no GC e em T5-T30 no GTREN. Concluiu-se que o pneumoperitônio de 10mmHg CO₂ não afetou significativamente a PIO ou a PPO em gatos anestesiados com isoflurano e mantidos sob ventilação espontânea. No entanto, o pneumoperitônio induzido combinado à posição de Trendelenburg resultou em aumento da PIO em gatos submetidos às mesmas condições anestésicas, mas não afetou a PPO.

PALAVRAS-CHAVE: Pressão Intra-abdominal. Posição corporal. Alterações oculares. Pressão. Videolaparoscopia. Videocirurgia.

REFERENCES

- ALMEIDA, A. V.; GANEM, E. M.; CARRARETTO, A. R.; VIANNA, P. T. G. Alterações hemodinâmicas durante o pneumoperitônio em cães ventilados com volume e pressões controlados. *Revista Brasileira de Anestesiologia*, v. 53, n. 6, p. 756-766, 2003. <https://doi.org/10.1590/S0034-70942003000600007>.
- ANDRADE JUNIOR, P. S. C. Avaliação do pneumoperitônio com CO₂ em gatos (*Felis catus*) anestesiados com isoflurano: parâmetros cardiorrespiratórios. 2009. 57f. Dissertação (Mestrado em Ciência Animal), Universidade Estadual do Norte Fluminense. http://www.uenf.br/Uenf/Downloads/PGANIMAL_3897_1260794578.pdf. Last accessed October 16, 2017.
- AWAD, H.; SANTILLI, S.; OHR, M.; ROTH, A.; YAN, W.; FERNANDEZ, S.; ROTH, S.; PATEL, V. The effects of steep Trendelenburg positioning on intraocular pressure during robotic radical prostatectomy. *Anesthesia and Analgesia*, v. 109, p. 473-478, 2009. <https://doi.org/10.1213/ane.0b013e3181a9098f>.
- BASSO, P. C.; RAISER, A. G.; BRUN, M. V.; MÜLLER, D.C.M.; LUKARSEWSKI, R.; SERAFINI, G.M.C.; FREITAS, G.C.; DUTRA, L.H.; MARCONATO, F. Ovariosalpingohisterectomy in bitches: comparison of pain, cardiopulmonary, pressure and arterial blood gas analysis of the conventional approaches, by NOTES hybrid and NOTES pure. *Arquivo Brasileiro de Medicina Veterinária e Zootecnia*, v. 66, p. 1329-1338, 2014. <http://dx.doi.org/10.1590/1678-6671>.
- BOTTER, F. C. S.; TAHA, M. O.; FAGUNDES, D. J.; FAGUNDES, A. T.; NEGRINI. The role of pneumoperitoneum in the respiratory and hemodynamic evaluation in anaesthetized rats, with or without intubation. *Revista do Colégio Brasileiro de Cirurgias*, v. 32, n. 5, p. 261-266, 2005. <https://doi.org/10.1590/S0100-69912005000500008>.

- BRUN, M. V. Equipe cirúrgica e ambiente operatório In: BRUN, M. V. Videocirurgia em pequenos animais, Rio de Janeiro, Rio de Janeiro: Roca, 2015, p.98.
- CASE, J. B.; BOSCAN, P. L.; MONNET, E. L.; NIYOM, S. R.; IMHOFF, D. J.; WALLACE, M. L.; SMEAK, D. D. Comparison of surgical variables and pain in cats undergoing ovariohysterectomy, laparoscopic-assisted ovariohysterectomy, and laparoscopic ovariectomy. *Journal of American Animal Hospital Association*, v. 51, n. 1, p. 1-7, 2015. <https://doi.org/10.5326/JAAHA-MS-5886>.
- DIBARTOLA, S. P. *Fluid, Electrolyte, and Acid-Base Disorders in Small Animal Practice*, 4th ed. St. Louis, USA: Elsevier Saunders, 2011. p. 231–252. <https://doi.org/10.1016/B978-1-4377-0654-3.00016-0>.
- HIKASA, Y.; KAWANABE, H.; TAKASE, K.; OGASAWARA, S. Comparison of sevoflurane, isoflurane and halothane anesthesia in spontaneously breathing cats. *Veterinary Surgery*, v. 25, p. 234-243, 1996. <https://doi.org/10.1111/j.1532-950X.1996.tb01407.x>.
- HONSHO, C. S.; MATTOS-JUNIOR, E.; TAVARES, D. C.; QUARTERONE, C.; MORAES, C. B. L. Efeitos do procedimento de videocirurgia sobre a pressão ocular (PO) em gatos. *Enciclopédia Biosfera*, v.9, n. 16, p. 941-951, 2013. <http://www.conhecer.org.br/enciclop/2013a/agrarias/efeitos%20do%20procedimento.pdf>. Last accessed October 16, 2017.
- HOSHIKAWA, Y.; TSUTSUMI, N.; OHKOSHI, K.; SERIZAWA, S.; HAMADA, M.; INAGAKI, K.; TSUZUKI, K.; KOSHIMIZU, J.; ECHIZEN, N.; FUJITANI, S.; TAKAHASHI, O.; DESHPANDE, G. A. The effect of steep trendelenburg positioning on intraocular pressure and visual function during robotic-assisted radical prostatectomy. *British Journal of Ophthalmology*, v. 98, n. 3, p. 305-382, 2014. <https://doi.org/10.1136/bjophthalmol-2013-303536>.
- KUMAR, G.; VYAKARNAM, P. Postoperative vision loss after colorectal laparoscopic surgery. *Surgery, Laparoscopy and Endoscopy Percutaneous Technics*, v. 23, n. 2, p. E87-E88, 2013. <https://doi.org/10.1097/SLE.0b013e318277d2ae>.
- LEME, M. C.; NATALINI, C. C.; BECK, C. A. C.; BRUN, M. V.; CONTESINI, E. A.; LIMA, S. D. A.; STEDILE, R. Pneumoperitônio com dióxido de carbono associado a três posições para laparoscopia em cães. *Ciência Rural*, v. 32, n. 2, p. 281-287, 2002. <http://dx.doi.org/10.1590/S0103-84782002000200016>.
- LEMONS, S. L. S.; VINHA, J. M.; SILVA, I. S.; NOVAES, P. A. C.; OLIVEIRA, M. F.; PAULA, G. B.; REBELO, C. C.; MARINHO, M. L. Effects of CO₂ and air pneumoperitoneum on blood gas changes in pigs. *Acta Cirúrgica Brasileira*, v. 18, n. 5, p. 445-451, 2003. <http://dx.doi.org/10.1590/S0102-86502003000500010>.
- LENTSCHENER, C.; LEVEQUE, J. P.; MAZOIT, J. X.; BENHAMOU, D. The effect of pneumoperitoneum on intraocular pressure in rabbits with alpha-chymotrypsin induce glaucoma. *Anesthesia and Analgesia*, v. 86, p. 1283-1288, 1998. <https://doi.org/10.1097/00000539-199806000-00029>.
- MOLLOY, L. B. Implications for postoperative visual loss: steep trendelenburg position and effects on intraocular pressure. *Journal American Association of Nurse Anesthetists*, v. 79, p. 115–121, 2011.
- MONDZELEWSKI, T. J.; SCHMITZ, J. W.; CHRISTMAN, M. S.; DAVIS, K. D.; LUJAN, E.; L'ESPERANCE, J. O.; AUGE, B. K. Intraocular pressure during robotic-assisted laparoscopic procedures utilizing steep trendelenburg positioning. *Journal of Glaucoma*, v. 24, n. 6, p. 399-404, 2015. <https://doi.org/10.1097/IJG.0000000000000302>.
- NORMANDO, V. M. F.; BRITO, M. V. H.; ARAÚJO JÚNIOR, F. A. ALBUQUERQUE, B. C. M. Repercussões do pneumoperitônio na amplitude da excursão diafragmática em suínos. *Jornal Brasileiro de Pneumologia*, v. 32, n. 1, p. 216-223, 2006. <https://doi.org/10.1590/S1806-37132006000100006>.

OZCAN, M.S.; PRAETEL, C.; BHATTI, M. T.; GRAVENSTEIN, N.; MAHLA, M. E.; SEUBERT, C. N. The effect of body inclination during prone positioning on intraocular pressure in awake volunteers: a comparison of two operating tables. *Anesthesia and Analgesia*, v. 99, n. 4, p. 1152-1158, 2004. <https://doi.org/10.1213/01.ANE.0000130851.37039.50>.

PEDROSO, A. M. G.; MARUBAYASHI, L.; GORI, R.; PEDROSO, M. A.; LUPINACCI, R. A. Relevant Aspects of anesthesia in laparoscopic colorectal surgery. *Revista Brasileira de Coloproctologia*, v. 27, n. 3, p. 284-287, 2007. <http://dx.doi.org/10.1590/S0101-98802007000300006>.

PINTO FILHO, S. T. L.; OLIVEIRA, M. T.; SOUZA, F. W.; DALMOLIN, F.; HARTMANN, H.; COUTINHO JÚNIOR, A. S.; SCHUSTER, L. A. H.; BECK, C. A. C.; SANTOS, F. R. B.; FERANTI, J. P. S.; BRUN, M. V. Uretrostomia pré-púbica videoassistida em um felino com estenose uretral. *Semina: Ciências Agrárias*, v. 35, n. 1, p.381-386, 2014. <http://dx.doi.org/10.5433/1679-0359.2014v35n1p381>.

TALIERI, I. C.; HONSHO, C. S.; NUNES, N.; SOUZA, A. P.; DUQUE, J. C. Behavior of intraocular pressure according to cardiorespiratory and hemodynamic effects induced by desflurane in dogs subjected to experimental hypovolemia. *Arquivo Brasileiro de Oftalmologia*, v. 68, n. 4, p. 521-526, 2005. <https://doi.org/10.1590/S0004-27492005000400018>

TANI, T.; NAGAOKA, T.; NAKABAYASHI, S.; YOSHIOKA, T.; YOSHIDA, A. Autoregulation of retinal blood flow in response to decreased ocular perfusion pressure in cats: comparison of the effects of increased intraocular pressure and systemic hypotension. *Investigative Ophthalmology and Visual Science*, v. 55, n. 1, p. 360-367, 2014. <https://doi.org/10.1167/iovs.13-12591>