Intracranial Mature Teratoma: A Case Report

Relato de caso: teratoma maduro intracraniano

Paulo Moacir Mesquita Filho[1] Fernanda de Carli[2] Moises Augusto de Araújo[1] Gregori Manfroi[2] Bruna Bley Isbert[2] Daniela Schwingel[3] Luciano Bambini Manzato[1]

[1] Department of Neurosurgery, Hospital da Cidade de Passo Fundo, Passo Fundo, RS, Brazil
[2] Academic League of Neurology and Neurosurgery Service, Passo Fundo, RS, Brazil
[3] Medical School, Faculdade Meridional (IMED), Passo Fundo, RS, Brazil

Address for correspondence Paulo Moacir Mesquita Filho, MD, Department of Neurosurgery, Hospital da Cidade de Passo Fundo, Tiradentes Street, 295, ZIP Code 99010-260, Passo Fundo, RS, Brazil (e-mail: pmesquitafilho@hotmail.com).

Arq Bras Neurocir 2016;35:344–348.

Abstract

Teratomas are the most common type of Germ Cell Tumors (GCTs). GCTs are classified as extragonadal, if there is no evidence of a primary tumor in neither the testicles, nor in the ovaries. Intracranial Mature Teratomas are tumors with a very low incidence, and clear male predominance. We present the case of a 21 year-old female patient, with a history of two seizures 15 days prior to admission, without any abnormalities upon physical examination. The Magnetic Resonance Imaging (MRI) performed at the admission evidenced an expansive, heterogeneous lesion in the frontal lobe, hypointense on T1-weighted images, hyperintense on T2-weighted images, and restriction on the diffusion imaging and ADC-mapping. The patient underwent microsurgical resection, and it was possible to achieve a near-total resection. During surgery, a well-defined capsule was identified, which was removed after adequate debulking. Tissues resembling hair were taken from inside the lesion. The patient recovered well, without any neurological deficits, and no further intervention was necessary. The authors aim to describe this rare pathology and their option for a surgical approach.

Keywords
- brain neoplasm
- germ cell tumor
- neurosurgery

Resumo

Os teratomas são o tipo mais comum de Tumores de Células Germinativas (TCG). TGC são classificados como extragonadais, quando não há evidências de um tumor primário em nos testículos, ou nos ovários. Os Teratomas Maduros Intracranianas são tumores com uma incidência muito baixa, e com uma predileção pelo sexo masculino. Nós apresentamos o caso de uma paciente, feminina, 21 anos de idade, com história de dois episódios de convulsões tônico-clônicas generalizadas, 15 dias antes da admissão, sem nenhum déficit focal ao exame físico. A Ressonância Magnética realizada na chegada mostrou uma lesão sólida, expansiva, grande e heterogênea, hipointensa em T1, e hiperintensa em T2, com restrição a difusão e ADC-*mapping*. Foi realizado uma cirurgia, e foi possível obter uma ressecção quase total. Havia uma cápsula bem definida, a qual foi removida após adequada redução do volume tumoral. Dentro da lesão foi encontrado tecido semelhante a cabelo. A paciente se recuperou bem, e foi dado alta sem novos déficits neurológicos, não foi realizado mais nenhuma intervenção, e ela está sendo acompanhada regularmente. Os autores visam descrever essa patologia rara e sua opção por uma abordagem cirúrgica.

Palavras-chave
- neoplasia cerebral
- tumor células germinativas
- neurocirurgia

received
October 28, 2015
accepted
January 19, 2016
published online
March 31, 2016

DOI http://dx.doi.org/10.1055/s-0036-1580738.
ISSN 0103-5355.

Copyright © 2016 by Thieme-Revinter Publicações Ltda, Rio de Janeiro, Brazil

License terms

Introduction

Teratomas are the most common type of Germ Cell Tumors (GCTs).[1] GCTs are classified as extragonadal, if there is no evidence of a primary tumor in neither the testicles, nor the ovaries. The term "Teratoma" refers to a neoplasm that differentiates into somatic-type cell population (typically including cell populations that would normally derive from ectoderm, endoderm, and mesoderm) that can be typical of either adult or embryonic development. The component tissues in a teratoma range from immature to well differentiated, and are foreign to the anatomic site in which they are found. Most, but not all, teratomas are benign. (1) Primary intracranial GCTs are a unique class of rare tumors that frequently affect children and young adults. (2) We report the case of a young female patient who presented with a large intracranial teratoma, and review the literature about this singular pathology.

Case Report

We report the case of a 21-year-old female patient, presenting with two generalized seizures, 15 days prior to admission. The patient was referring, for over 5 years, headache, and during the prior month, she started with nausea and vomiting, and developed diplopia. The patient had no history of previous pathologies, and was using only analgesics and oral contraceptives. The physical and neurological examination were uneventful.

The Magnetic Resonance Imaging (MRI) performed at the admission evidenced dysgenesis of corpus callosum, with splitting of lateral ventricles and deformity of ventricular system (colpocephaly). In the frontal lobe, an expansive, large, heterogeneous, and solid lesion was identified. The lesion was hypointense on T1-weighted images, hyperintense on T2-weighted images, with restriction on the diffusion imaging and ADC-mapping. In the topography of the corpus callosum, there was a different and smaller mass, with characteristics of fat tissue. Trespassing the mass, there was a coarse dilated structure, resembling a large vessel, with other small vascular structures suggesting arterio-venous malformation (AVM). Nevertheless, angiography showed only a hypertrophy of the anterior cerebral artery (ACA), with an azygos pattern, excluding the possibility of an AVM (►**Fig. 1**).

We performed surgery, achieving a near-total resection. There was a well-defined capsule, which we removed after adequate debulking. Tissue resembling hair was taken from inside the lesion. The fat tissue attached to the corpus callosum was not approached, especially due to the possibility of an arterial injury of a variant ACA. Histological examination confirmed the diagnosis of Mature Teratoma (MT). The patient recovered well, with no neurological deficits. No further treatment was performed, and she is receiving regular follow-up.

Discussion

In the World Health Organization classification system, intracranial GCTs are divided into germinomas and non-germinomatous GCTs (NGGCTs).[2] NGGCTs include embryonal carcinomas, endodermal sinus tumors (also known as yolk-sac tumors), choriocarcinomas, teratomas (immature and mature), and mixed tumors (with more than one element present). Germinomas comprise 60 to 65% of all pediatric intracranial GCTs. Approximately 25% of NGGCTs are mixed and contain more than one histologic component.[3,4]

The reported incidences of intracranial GCTs among children with a brain tumor are higher in the Far East than in the West, and there is a wide difference among countries: Canada (3.3%),[5] France (3.5%),[6] United States of America (4.1%),[7] Japan (10.3%),[7] Korea (11.2%),[8] and Taiwan (14%),[9] suggesting that genetic and/or environmental factors are responsible for the tumorigenesis of GCTs. Even though the incidence of these tumors is still low, their relative proportions among brain tumors appear to be increasing year-on-year worldwide.[8,10] In North America and Europe, intracranial GCTs represent 0.5–3% of pediatric central nervous system (CNS) tumors.[11] Intracranial teratomas are the most prevalent congenital tumors, comprising 28–50% of CNS tumors and ~0.5% of all intracranial tumors.[12,13] The incidence of intracranial GCT reaches a peak during the second decade of life, with a median age at diagnosis of 10 to 12 years. There is a male preponderance of 2:1 to 3:1, especially with tumors in the pineal region.[3,4]

Intracranial GCTs arise almost exclusively in midline locations. The two most frequent sites are the pineal gland and the suprasellar regions, with pineal tumors occurring nearly twice as often as suprasellar GCTs. They can also arise in the basal ganglia, thalamus, cerebellum and, as in the present case, cerebral hemispheres.[14,15] In 5–10% of cases, patients present with tumors at both pineal and suprasellar locations.[3,4] Tumor seeding or multiple tumor nodules along the lateral and third ventricles are observed in 10% of patients.[16] Furthermore, the distribution of intracranial GCTs, in terms of tumor site and histology, depends on age.

Teratomas are classified pathologically into mature, immature, and malignant subtypes.[17–19] Mature teratomas (MTs) are composed of well-differentiated elements, whereas immature teratomas contain components resembling fetal tissues.[20] Intracranial MTs are tumors with a very low incidence (0.2%) and clear male predominance (5:1).[18] These lesions are believed to be originated from an abnormal distribution of germ cells, during the third to fourth week of gestation.[17,18,20] Teratomas have two peaks in their age distribution: 10% occur before 5 years of age, whereas 48% occur between 5 and 14 years of age. Some consider that the first peak of incidence is due to sequestration of blastocyst cells, before differentiation has occurred.[21,22] The clinical scenario of patients with intracranial GCTs depends on the location of the tumor. Delays in diagnosis are common, especially symptoms due to endocrinopathy (e.g., delayed vertical growth, diabetes insipidus), associated with delays greater than 12 months and higher incidences of disseminated disease at diagnosis.[23]

A MT may have two distinct regions: a lipid and a more solid or fluid one.[24] Components of MTs reported in previous

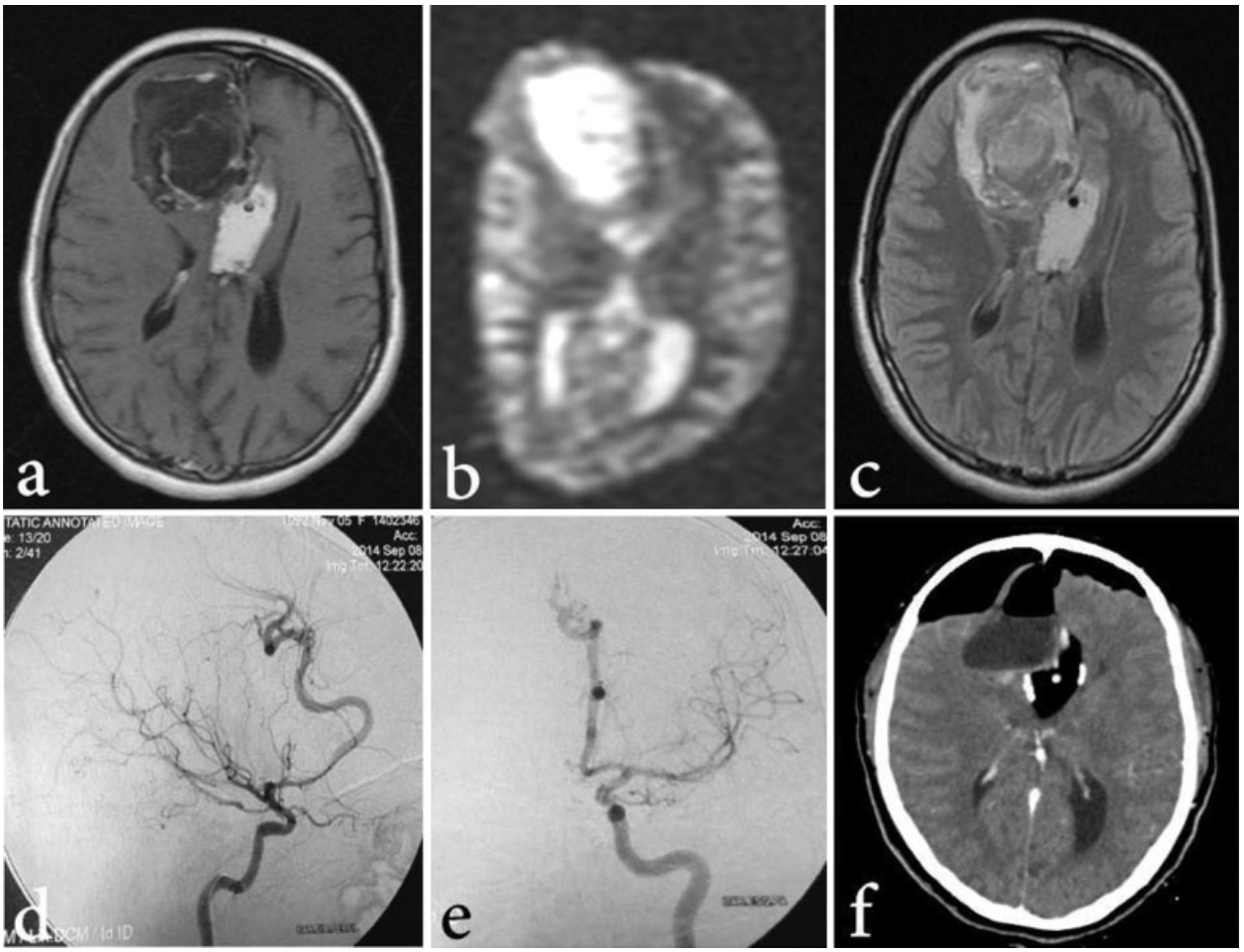

Fig. 1 (a) T1-weighted MRI, evidencing a large heterogeneous mass in the right frontal lobe and corpus callosum, dysgenesis of corpus callosum and distortion of the ventricular system. (b) Restriction in the diffusion imaging and ADC-mapping, compatible with teratoma. (c) T2-weighted MRI, evidencing the hyperintense heterogeneous mass. (d) Lateral angiography showing hypertrophy of the anterior cerebral artery, with an azygos pattern. (e) Antero-posterior angiography confirming the azygos pattern of the anterior cerebral artery. (f) Post-operative CT scan, evidencing total resection of the solid component in the frontal lobe, and the remaining lipoma in the corpus callosum topography.

reports are diverse and include immature mesenchymal tissue, cuboidal, and columnar epithelium with goblet cells, islands of immature cartilage, bands of striated and non-striated muscles, glioneuronal tissue, retinal tissue, and adipose tissue (►**Fig. 2**).[25] Ijiri et al described a spinal mature teratoma in an adult patient, the components of which consisted of bone, cartilage, adipose tissue, and blood vessels and all of them were from only one germ layer, the mesoderm.[26]

CT and MRI are helpful to estimate the nature of the lesion and may show components of mixed density that include fat and soft tissue, cartilage, and calcified tissues, such as bone and teeth.[25] MRI is the preferred imaging technique for diagnosis and staging, although computed tomography (CT) is also very sensitive in detecting suprasellar and pineal GCTs. On MRI, intracranial GCTs appear isointense or hypointense on T1-weighted sequences and hyperintense on T2-weighted sequences.[27] These tumors typically show homogeneous enhancement with gadolinium, or heterogeneous enhancement if cysts are present. This appearance is, however, nonspecific. The diagnosis of teratoma can be suggested if foci of fat are present within the lesion.[28] The high signal from fat on MRIs, especially on T1-weighted images, makes the identification of lipid droplets easy, particularly within the cerebral sulci, fissures, perimedullary subarachnoid space, and central canal of the spinal cord.[24] Nevertheless, imaging characteristics of the histologic subtypes are similar, and MRIs cannot reliably distinguish germinomas from NGGCTs.[27] The differential diagnosis include astrocytoma, choroid plexus papilloma, ependymoma, and primitive neuroectodermal tumor (PNET).[28]

Histologic examination is the mainstay to establish a definitive diagnosis of an intracranial GCT, and to ascertain the histologic subtype. A tissue sample should be obtained, unless surgery cannot be performed safely. Biopsy is mandatory for patients with normal analysis of CSF, serum α-fetoprotein (AFP), and chorionic gonadotropin (β-hCG), since a pure germinoma or a MT must be distinguished from other lesions, including pineal PNET, ependymoma, craniopharyngioma, Langerhans cell histiocytosis, low-grade glioma, hamartoma, and metastatic disease from extra-cranial tumors.[16]

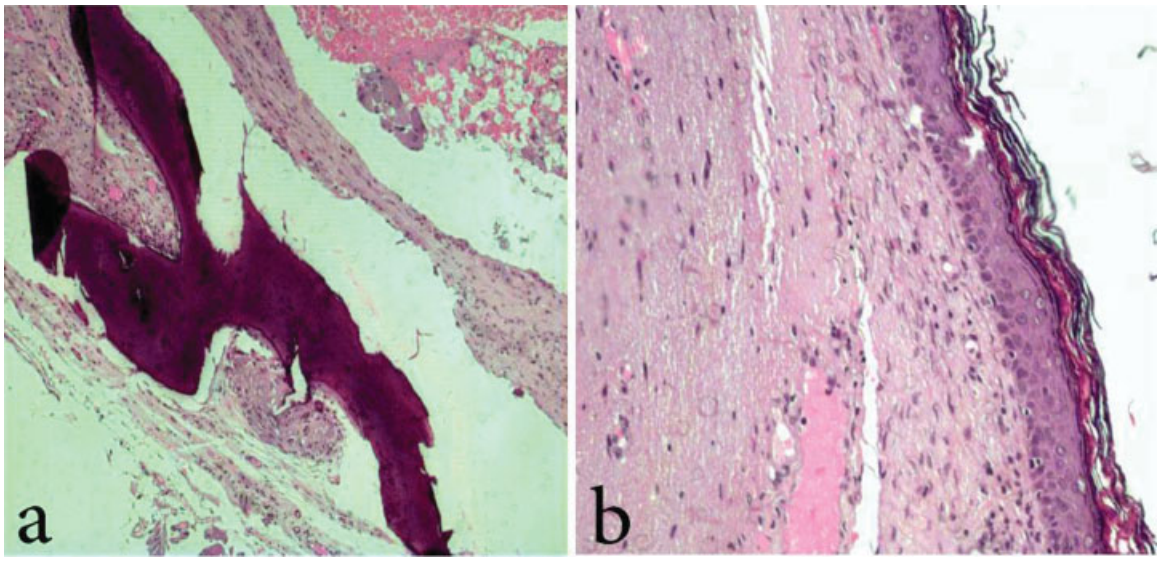

Fig. 2 Hematoxylin and eosin (H&E) stained sections of the tumor resection. (a) Bony tissue among brain parenchyma (H&E 50x). (b) Intraparenchymal cystic area lined with keratinized stratified squamous epithelium.

Regarding therapy, the distinction between germinomas and NGGCTs is critical, since patients with germinomas have a better prognosis and require less intensive methods than those with NGGCTs.[29] Unlike immature teratomas, MTs are benign and radioresistant, and malignant transformation is very rare. Surgical resection is the main treatment for intracranial MTs, and the content of the cyst must be aspirated carefully to avoid aseptic meningitis.[30,31] Gross total resection at diagnosis is indicated for patients with MT, confirmed by histology and normal tumor markers, since surgery is curative and no further interventions are required.[27,31,32] Immediate neurosurgical intervention is indicated when there is worsening in neurological status from mass effect or obstructive hydrocephalus.

MTs have been reported to have survival rates up to 93% at 10 years. However, a phenomenon of tumor recurrence has been reported, known as "growing teratoma syndrome." In this syndrome, the recurrent tumor is presumed to be refractory to chemotherapy or radiation. This entity, however, usually refers to those who had a previous malignant tumor.[19]

Conclusion

Teratomas are unusual intracranial tumors, with a wide variance in terms of age at presentation, location, and histological subtypes, and should be differentiated from other GCTs. It is important to consider obtaining tissue to establish a histologic diagnosis for patients with a suspected intracranial GCT, unless the morbidity of the procedure outweighs the benefit. Although these tumors may present similar clinical manifestations and radiological features, their treatment responses and prognosis differ greatly, justifying histological analysis to tailor the therapy.

References

1 Gershenson DM, Goff B, Pappo AS, Garcia RL, Falk SJ. Ovarian germ cell tumors: Pathology, clinical manifestations, and diagnosis [Internet]. Available from: http://www.uptodate.com/contents/ovarian-germ-cell-tumors-pathology-clinical-manifestations-and-diagnosis
2 Louis DN, Ohgaki H, Wiestler OD, et al. The 2007 WHO classification of tumours of the central nervous system. Acta Neuropathol 2007;114(2):97–109
3 Jennings MT, Gelman R, Hochberg F. Intracranial germ-cell tumors: natural history and pathogenesis. J Neurosurg 1985;63(2):155–167
4 Hoffman HJ, Otsubo H, Hendrick EB, et al. Intracranial germ-cell tumors in children. J Neurosurg 1991;74(4):545–551
5 Felix I, Becker LE. Intracranial germ cell tumors in children: an immunohistochemical and electron microscopic study. Pediatr Neurosurg 1990–199116(3):156–162
6 Bauchet L, Rigau V, Mathieu-Daudé H, et al; Société Française de Neurochirurgie Pédiatrique; Société Française de Neurochirurgie; Société Française de Neuropathologie; Association des Neuro-Oncologues d'Expression Française. Clinical epidemiology for childhood primary central nervous system tumors. J Neurooncol 2009;92(1):87–98
7 Ostrom QT, Gittleman H, Liao P, et al. CBTRUS statistical report: primary brain and central nervous system tumors diagnosed in the United States in 2007-2011. Neuro-oncol 2014;16(Suppl 4):iv1–iv63
8 Cho K-T, Wang K-C, Kim S-K, Shin S-H, Chi JG, Cho B-K. Pediatric brain tumors: statistics of SNUH, Korea (1959-2000). Childs Nerv Syst 2002;18(1–2):30–37
9 Wong T-T, Ho DM, Chang K-P, et al. Primary pediatric brain tumors: statistics of Taipei VGH, Taiwan (1975-2004). Cancer 2005;104(10):2156–2167
10 Rickert CH, Paulus W. Epidemiology of central nervous system tumors in childhood and adolescence based on the new WHO classification. Childs Nerv Syst 2001;17(9):503–511
11 Echevarría ME, Fangusaro J, Goldman S. Pediatric central nervous system germ cell tumors: a review. Oncologist 2008;13(6):690–699
12 Isaacs H Jr. Perinatal (congenital and neonatal) neoplasms: a report of 110 cases. Pediatr Pathol 1985;3(2–4):165–216
13 Tobias S, Valarezo J, Meir K, Umansky F. Giant cavernous sinus teratoma: a clinical example of a rare entity: case report. Neurosurgery 2001;48(6):1367–1370, discussion 1370–1371

14 Kim DI, Yoon PH, Ryu YH, Jeon P, Hwang GJ. MRI of germinomas arising from the basal ganglia and thalamus. Neuroradiology 1998;40(8):507–511
15 Tamaki N, Lin T, Shirataki K, et al. Germ cell tumors of the thalamus and the basal ganglia. Childs Nerv Syst 1990;6(1):3–7
16 Su JM, Loeffler JS, Wen PY, Gajjar A, Eichler AF. Intracranial germ cell tumors [Internet]. Available from: http://www.uptodate.com/contents/intracranial-germ-cell-tumors
17 Thakran A, Rao S, Sreenivas M, Khurana N. Massive congenital intracranial immature teratoma: an autopsy report. Indian J Pathol Microbiol 2012;55(2):272–274
18 Sanyal P, Barui S, Mathur S, Basak U. A case of mature cystic teratoma arising from the fourth ventricle. Case Rep Pathol 2013; 2013:702424
19 Sano K. Pathogenesis of intracranial germ cell tumors reconsidered. J Neurosurg 1999;90(2):258–264
20 Zhao J, Wang H, Yu J, Zhong Y, Ge P. Cerebral falx mature teratoma with rare imaging in an adult. Int J Med Sci 2012; 9(4):269–273
21 Sweiss RB, Shweikeh F, Sweiss FB, Zyck S, Dalvin L, Siddiqi J. Suprasellar mature cystic teratoma: an unusual location for an uncommon tumor. Case Rep Neurol Med 2013;2013; 180497
22 Saada J, Enza-Razavi F, Delahaye S, Martinovic J, Macaleese J, Benachi A. Early second-trimester diagnosis of intracranial teratoma. Ultrasound Obstet Gynecol 2009;33(1):109–111
23 Sethi RV, Marino R, Niemierko A, Tarbell NJ, Yock TI, MacDonald SM. Delayed diagnosis in children with intracranial germ cell tumors. J Pediatr 2013;163(5):1448–1453
24 Oh JS, Im SB, Kim BT, Shin WH. Surgical findings of a lumbar mature teratoma accompanying the preoperative intracranial dissemination of Fatty droplets. J Korean Neurosurg Soc 2009; 46(4):409–412
25 Kamoshima Y, Sawamura Y, Iwasaki M, Iwasaki Y, Sugiyama K. Metachronous mature teratoma in the corpus callosum occurring 12 years after a pineal germinoma. J Neurosurg 2008;109(1): 126–129
26 Ijiri K, Hida K, Yano S, Iwasaki Y. Huge intradural ossification caused by a mature spinal teratoma: case report. Neurosurgery 2009;64(6):E1200–E1201, discussion E1201
27 Sawamura Y, de Tribolet N, Ishii N, Abe H. Management of primary intracranial germinomas: diagnostic surgery or radical resection? J Neurosurg 1997;87(2):262–266
28 Nejat F, Kazmi SS, Ardakani SB. Congenital brain tumors in a series of seven patients. Pediatr Neurosurg 2008;44(1):1–8
29 Ogino H, Shibamoto Y, Takanaka T, et al. CNS germinoma with elevated serum human chorionic gonadotropin level: clinical characteristics and treatment outcome. Int J Radiat Oncol Biol Phys 2005;62(3):803–808
30 O'Grady J, Kobayter L, Kaliaperumal C, O'Sullivan M. 'Teeth in the brain' - a case of giant intracranial mature cystic teratoma. BMJ Case Rep 2012;2012:1–4
31 Matsutani M, Sano K, Takakura K, et al. Primary intracranial germ cell tumors: a clinical analysis of 153 histologically verified cases. J Neurosurg 1997;86(3):446–455
32 Matsutani M; Japanese Pediatric Brain Tumor Study Group. Combined chemotherapy and radiation therapy for CNS germ cell tumors—the Japanese experience. J Neurooncol 2001;54(3):311–316