

Laparoscopic Resection of Retroperitoneal Presacral Schwannoma: A Case Report

Ressecção laparoscópica de schwannoma retroperitoneal pré-sacral: relato de caso

Melina Luisa Ruoso¹ Luiza Scussel Feranti¹ Paulo César Andriguetto²
Leonardo Dudeque Andriguetto² Solena Ziemer Kusma Fidalski¹ Luiz Roberto Aguiar³

¹ Faculty of Medicine, Pontifícia Universidade Católica, Curitiba, PR, Brazil

² Department of General Surgery, Hospital Santa Cruz, Curitiba, PR, Brazil

³ Department of Neurosurgery, Hospital Santa Cruz, Curitiba, PR, Brazil

Address for correspondence Melina Luisa Ruoso, Faculdade de Medicina da Pontifícia Universidade Católica, Rua João Carlos de Souza Castro, 428 Casa 4, Guabirubá – Curitiba, PR – 81.520-290, Brazil (e-mail: melruoso@gmail.com).

Arq Bras Neurocir 2018;37:326–329.

Abstract

Keywords

- schwannoma
- laparoscopic surgery
- presacral space
- retroperitoneal space

Resumo

Palavras-chave

- schwannoma
- cirurgia laparoscópica
- espaço pré-sacral
- espaço retroperitoneal

Retroperitoneal presacral schwannomas are uncommon and are usually diagnosed accidentally. We present here the case of a 23-year-old woman diagnosed with an expansive pelvic lesion during a routine gynecological examination. The precise location of the tumor, as well as its relation to adjacent structures, was determined through magnetic resonance imaging (MRI). The patient underwent laparoscopic lesion resection and the diagnosis was confirmed by immunohistochemistry. An MRI performed 2 months after surgery confirmed complete lesion resection.

Schwannomas pré-sacrais retroperitoneais são incomuns e geralmente diagnosticados acidentalmente. O caso apresentado envolve uma mulher de 23 anos, que teve o diagnóstico de lesão expansiva pélvica estabelecido em consulta ginecológica de rotina. A ressonância magnética ajudou a determinar a localização precisa do tumor e suas relações com estruturas adjacentes. A paciente foi submetida à ressecção da lesão por técnica laparoscópica e o diagnóstico de Schwannoma foi confirmado histopatologicamente e por imunohistoquímica. O exame de ressonância magnética realizado dois meses após a cirurgia confirmou a ressecção completa do tumor.

Introduction

Schwannomas (that is, tumors formed by Schwann cells) are very rare, and only 0.3 to 3.2% of them are malignant. Schwannomas are usually located in the head or spine,^{1,2} and only ~ 3 to 3.2% can be found in presacral regions.³

The retroperitoneal presacral region is where uterine growth occurs during pregnancy; thus, it is a region that favors mass development. Tumors in this region are often asymptomatic and are discovered casually during routine gynecological

exams. The recommended treatment is surgical removal of the tumor and of the capsule, and recent studies have reported the use of laparoscopic surgery⁴ for this procedure. Retroperitoneal presacral tumors are complex and require the collaboration of professionals from several areas (such as general surgery, gynecology, neurosurgery and urology).³

In this study, we present the case of a 23-year-old female patient with a retroperitoneal presacral schwannoma and discuss in detail the surgical technique used and the clinical outcome.

received
July 24, 2018
accepted
October 22, 2018

DOI <https://doi.org/10.1055/s-0038-1676528>.
ISSN 0103-5355.

Copyright © 2018 by Thieme Revinter Publicações Ltda, Rio de Janeiro, Brazil

License terms



Case Report

History and Physical Exam

This was a 23-year-old female patient with a retroperitoneal presacral tumor diagnosed during a routine gynecological exam. For the previous 2 years, the patient had suffered from severe abdominal pain during menstruation, which was suspected to be due to endometriosis. A pelvic ultrasound revealed a solid nodule in the retrouterine region measuring 42 × 36 mm.

A magnetic resonance imaging (MRI) with abdominal and pelvic contrast revealed a heterogeneous nodular image with predominant hyposignal in T1 and predominant hypersignal in T2 (with hyposignal in the central foci), involving the right S2 nerve root immediately after emerging from the sacral foramen, with no signs of hemorrhage or adipose tissue, and with heterogeneous central enhancement. The lesion diverted the upper third of the rectum contralaterally, with a preserved adipose cleavage plane measuring 39 × 43 × 38 mm. Diagnosis was that of a possible giant schwannoma. The patient was admitted to the department of neurosurgery, referring the abdominal pain that had triggered the investigation, as well as pain in the lumbar region and lower limbs, in addition to lower limb paresthesia. She underwent a lumbosacral spine contrast-enhanced MRI immediately before the surgery, which confirmed the solid, roughly oval expansive lesion with well-defined contours and signal intensity and a heterogeneous enhancement projecting into the pelvis that altered bone structure. The lesion was ~ 46 × 43 × 39 mm (► Fig. 1).

Surgery

We chose to perform laparoscopic surgery with the aid of the ultrasonic aspirator. The patient was submitted to pure intravenous general anesthesia and orotracheal intubation,

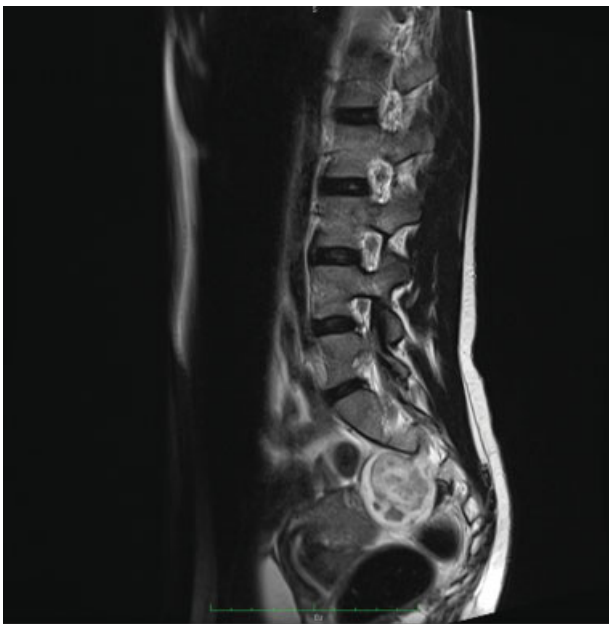

Fig. 1 Lumbosacral spine contrast-enhanced magnetic resonance imaging. (A) Sagittal T2-weighted image showing tumor location in the presacral region.

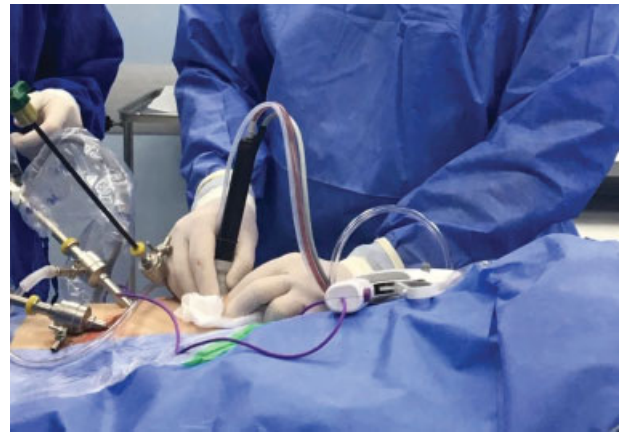

Fig. 2 Laparoscopic surgical route showing the distribution of the trocars, as well as the ultrasonic aspirator during the infraumbilical paraincision.

with mean arterial pressure (MAP) and bispectral index (BIS) monitoring. A 1-cm infraumbilical incision was made to introduce the first trocar (10 mm). The second trocar (5 mm) was inserted into the left iliac fossa, and the third (10 mm) into the right flank (► Fig. 2). An initial inspection of the region showed a bulge in the right iliac region displacing the rectum to the left, posterior to the uterus.

The uterus was fixed with stitches to the anterior abdominal wall and the mesorectum was dissected in the right iliac region. The tumor was located in the retroperitoneal plane; it originated from the sacral region and occupied a large portion of the retrorectal pelvic region. We dissected and incised part of the capsule, allowing access to the inside of the lesion, which appeared friable and sandy. We conducted a paraincision by inserting a long tip of the ultrasonic aspirator into the abdominal cavity. The lesion volume was reduced considerably through debulking using aspiration at 40% ultrasonic power. It was thus possible to identify the tumor pedicle originating from the root of S2, which was then ligated and coagulated, allowing for complete tumor resection. Next, we conducted the hemostasis check and closed the planes.

The macroscopic pathology exam revealed a solid lesion measuring 40 × 30 × 20 mm. When it was cut, we observed a capsule with yellowish tissue, with a finely granular, firm and friable interior. The histological sections stained with hematoxylin-eosin revealed tissue fragments with architectural and cellular characteristics consistent with a diagnosis of fusocellular neoplasia. Immunohistochemistry confirmed the diagnosis of mixed peripheral nerve sheath tumor, with a schwannoma/neurofibroma pattern (► Fig. 3). Positive S100 protein suggested the lesion was benign.

Postoperative Care

The patient did not present any postoperative complications. On the first postoperative day, she reported mild pain at the surgical site, accompanied by paresthesia in the right lower limb. On the second postoperative day, she also reported paresthesia in the perianal region. The patient was discharged on the third postoperative day, at which time the symptoms had improved.

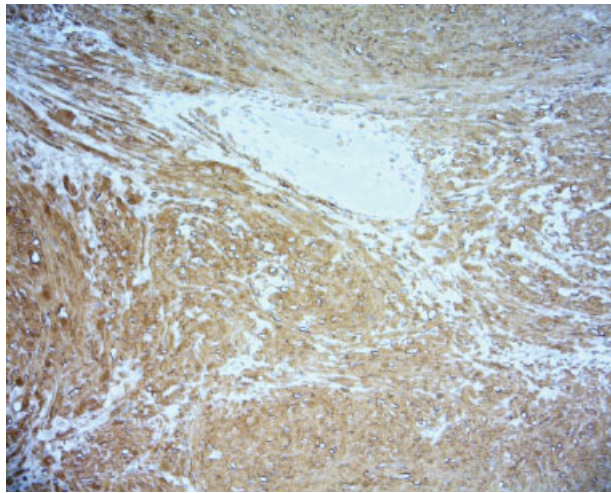


Fig. 3 Immunohistochemistry for S100-positive protein confirming diagnosis of mixed peripheral nerve sheath tumor with a schwannoma/neurofibroma pattern.

At the 30-day follow-up, the patient was in good general condition. She reported pain in the right gluteal region and some improvement of the paresthesia, which was accompanied by a slight motor deficit in the right lower limb. At that time, the patient underwent a lumbosacral spine contrast-enhanced MRI to check for the presence of residual lesion tissue, root lesions and/or local fibrosis. Imaging revealed that the tumor had been completely removed (► **Fig. 4**).

At the 5-month evaluation, the patient reported difficulty in performing certain movements and altered sensitivity in the lower right limb. Muscle flexibility and strength had returned to presurgical levels, and paresthesia in the perianal region had resolved.

Discussion

Schwannomas are very rare benign sacral tumors that can occur at any level of the spinal cord but are most frequently found in the lumbar region,^{5,6} as was the case of the patient presented here. Because of their size and proximity to the sacral nerve roots, these tumors require a team approach involving neurosurgeons and general surgeons.^{7,8} The surgical team was composed of one neurosurgeon and two general surgeons with a long experience in the laparoscopic approach. Several studies have suggested that presacral schwannomas with a large retroperitoneal presacral component should be accessed anteriorly,⁹ so the approach was correctly indicated in this case.

Retroperitoneal presacral schwannomas are difficult to diagnose preoperatively. While ultrasonography, computed tomography (CT) and MRI can reveal information about tumor size, location and neighboring tissues, they cannot confirm diagnosis. In a review of 82 retroperitoneal schwannomas, only 15.9% of tumors were identified preoperatively using these imaging techniques.^{10,11}

Late discovery of presacral tumors is common because of their slow-growing nature and nonspecific symptoms. Thus, at

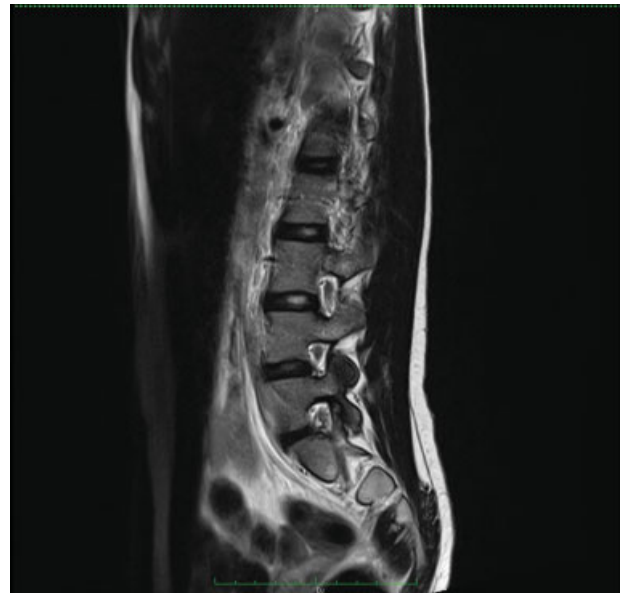

Fig. 4 Lumbosacral spine contrast-enhanced T2-weighted magnetic resonance imaging (A) showing the lesion's total excision.

the time of diagnosis, these tumors tend to be considerably large.⁸ The most frequent neurological sign associated with these tumors is decreased sensitivity in the lower limbs.⁹ In the case presented here, the tumor was very large and the patient's only symptom at the time of diagnosis was pain. Presacral schwannomas are more frequently observed among women.³ Because the patient presented in this case report was young, we chose to use videolaparoscopy, which avoids leaving a large scar on the anterior abdominal wall. In addition, videolaparoscopy offers a safe and efficient way of approaching benign schwannomas with better visualization, especially in narrow anatomical spaces.¹ A recent publication suggested using intramuscular access as an alternative technique for resecting pelvic schwannomas, but this method involved a relatively longer surgical time and difficulty with hemostasis.¹²

Compared with laparotomy, videolaparoscopy has a lower risk of intra and postoperative bleeding, a lower risk of infection, and a shorter postoperative hospital stay.

The goal of treating presacral tumors is their complete resection, and in this case, we found the ultrasonic aspirator to be very useful to this end. It reduces the tumor volume and consequently the tension on adjacent structures (uterus and appendages, pelvic vessels, bladder) while avoiding excessive manipulation of the adjacent area. The aspirator is mainly used for rapid debulking of the tumor's center without causing movement in the surrounding tissue. It avoids the thermal injury caused by cautery and avoids overcrowding the surgical field. The aspirated tissue can be submitted to anatomopathological examination, including immunohistochemistry, with little cellular distortions.¹³

The ultimate goal of the surgical treatment is complete tumor excision without neurological sequelae, which is possible in most cases⁶. Here, we were able to perform complete tumor excision, which resulted in mild neurological sequelae that evolved well over the 5 months following surgery. Benign

tumors in this location do not present a risk of distant metastases, have low recurrence rates and have an excellent prognosis.⁹

This case was challenging, and the techniques utilized proved successful. We will continue to search for new emerging techniques and improvements to our methods

Conflict of Interest

The authors declare that they have no conflicts of interest to report.

References

- 1 Rajkumar JS, Ganesh D, Anirudh JR, Akbar S, Kishore CM. Laparoscopic excision of retroperitoneal schwannoma. *J Clin Diagn Res* 2015;9(11):PD05–PD07
- 2 Petrucciani N, Sirimarco D, Magistri P, Antolino L, Gasparrini M, Ramacciato G. Retroperitoneal schwannomas: advantages of laparoscopic resection. Review of the literature and case presentation of a large paracaval benign schwannoma (with video). *Asian J Endosc Surg* 2015;8(01):78–82
- 3 Jankowski R. Presacral schwannoma. Case description. *J Med Sci* 2015;4(84):264–270
- 4 Descazeaud A, Coggia M, Bourriez A, Goëau-Brissonnière O. Laparoscopic resection of a retroperitoneal schwannoma. *Surg Endosc*. 2003 Mar; 17(03):520 Epub 2002 Dec 20
- 5 Possover M. Laparoscopic management of sacral schwannoma for intractable vulvo-coccygodynia: Report of three Cases and Review of Literature. *Possover Int Med Cent*. 2012:1–7
- 6 Piek J. Giant schwannoma of the cauda equina without neurological deficits—case report and review of the literature. *Wien Klin Wochenschr* 2010 Nov; 122(21–22):645–648 Epub 2010 Oct 22
- 7 Kagaya H, Abe E, Sato K, Shimada Y, Kimura A. Giant cauda equina schwannoma. A case report. *Spine (Phila Pa 1976)* 2000 Jan 15;25(02):268–272
- 8 Klimo P, Rao G, Schmidt RH, Ph D, Schmidt MH. Nerve Sheath Tumors Involving the Sacrum: Case Report and Classification Scheme. *Medscape*. 2017. p. 3–10.
- 9 Chandhanayingyong C, Asavamongkolkul A, Lektrakul N, Muangsomboon S. The management of sacral schwannoma: report of four cases and review of literature. *Sarcoma* 2008;2008:845132 doi: 10.1155/2008/845132
- 10 Ferreira C, Reis F, Correia T, Cerqueira M, Carvalho LF, Couto e Castro J, Macedo-Dias J, Prisco R. Exérese laparoscópica de um schwannoma retroperitoneal: um caso clínico e revisão da literatura. *Acta Urológica Portuguesa* 2015;32(02):86–90
- 11 Jatal S, Pai VD, Rakhi B, Saklani AP. Presacral schwannoma: laparoscopic resection, a viable option. *Ann Transl Med* 2016;4(09):176–176<http://atm.amegroups.com/article/view/10226/11055> [Internet]
- 12 Osa Emohare MBBS, Molly Stapleton PA-C, Alejandro Mendez M. A minimally invasive pericoccygeal approach to resection of a large presacral schwannoma: case report. *J Neurosurg* 2015;23(July):81–85
- 13 Singh V, Banerji A. Ultrasonic surgical aspirator in neurosurgery. In: Ramamurthi R, Sridhar K, Vasudevan M, editors. *Textbook of operative neurosurgery*. 1 ed. New Dehli - India: B.I Publicatios Pvt Ltd; 2005:55–8