

Noninvasive follicular thyroid neoplasm with papillary-like nuclear features (NIFTP): A case report.

*Correspondence:

stephanie.romero.ulloa@gmail.com

Av. Pedro J. Menéndez Gilbert and Atahualpa Chávez (next to the Atahualpa citadel) Apt. Postal 090505. Surgery Service. National Oncological Institute "Dr. Juan Tanca Marengo"-SOLCA- Guayaquil - Ecuador. Telephone [593] (04) 371-8300 Ext 2218

Conflict of interests: The authors declare not to have any interest conflicts.

Received: January 18, 2022

Accepted: March 28, 2022

Published: April 9, 2022

Editor: Dr. Evelyn Valencia Espinoza.

Bibliographic letterhead:

Romero S, Abad H, Ruiz J, Leone M, Huamán F. Non-invasive follicular thyroid neoplasm with papillary-like nuclear features (NIFTP): A case report. Rev. Oncol. Ecu 2022;32(1):112-121.

DOI: <https://doi.org/10.33821/605>

Copyright Romero S, et al. This article is distributed under the terms of [Creative Commons Attribution License BY-NC-SA 4.0](https://creativecommons.org/licenses/by-nc-sa/4.0/), which allows the use and redistribution citing the source and the original author.

Stephanie Romero Ulloa¹ , **Hamilton Abad Gualpa**², **Juan Carlos Ruiz Cabezas**³ , **Mario Leone Pignataro**¹ , **Fuad Huaman Garaicoa**³

1. Surgery Service. National Oncology Institute "Dr. Juan Tanca Marengo. SOLCA, Guayaquil-Ecuador.
2. Endocrinology Service. National Oncology Institute "Dr. Juan Tanca Marengo. SOLCA, Guayaquil-Ecuador.
3. Pathological Anatomy Service. National Oncology Institute "Dr. Juan Tanca Marengo. SOLCA, Guayaquil-Ecuador.

Abstract

Introduction: In recent decades, there has been an increase in the incidence of differentiated thyroid cancer, especially microcarcinomas, whose behavior is usually indolent, with overdiagnosis and unnecessary exhausting therapies with tremendous economic implications.

Objective: To describe a thyroid neoplasm with low malignant potential whose treatment is purely surgical and conduct a bibliographic review.

Clinical case: A 36-year-old male underwent surgery for a thyroid nodule classified as Bethesda VI, where the postsurgical histopathology showed a noninvasive follicular thyroid neoplasm with papillary-type nuclear characteristics (NIFTP). The evolution was favorable; he did not need the substitution of levothyroxine or radioactive iodine.

Discussion: Noninvasive follicular variants of PTC have a meager malignant potential, so the ATA classified it as a low-risk neoplasm whose treatment is purely surgical, changing its name to NIFTP.

Conclusion: NIFT has an excellent prognosis, and hemithyroidectomy is sufficient in most cases.

Keywords:

MESH: Thyroid Cancer, Papillary; Thyroidectomy; Thyroid Nodule; Case Reports.

DOI: 10.33821/605

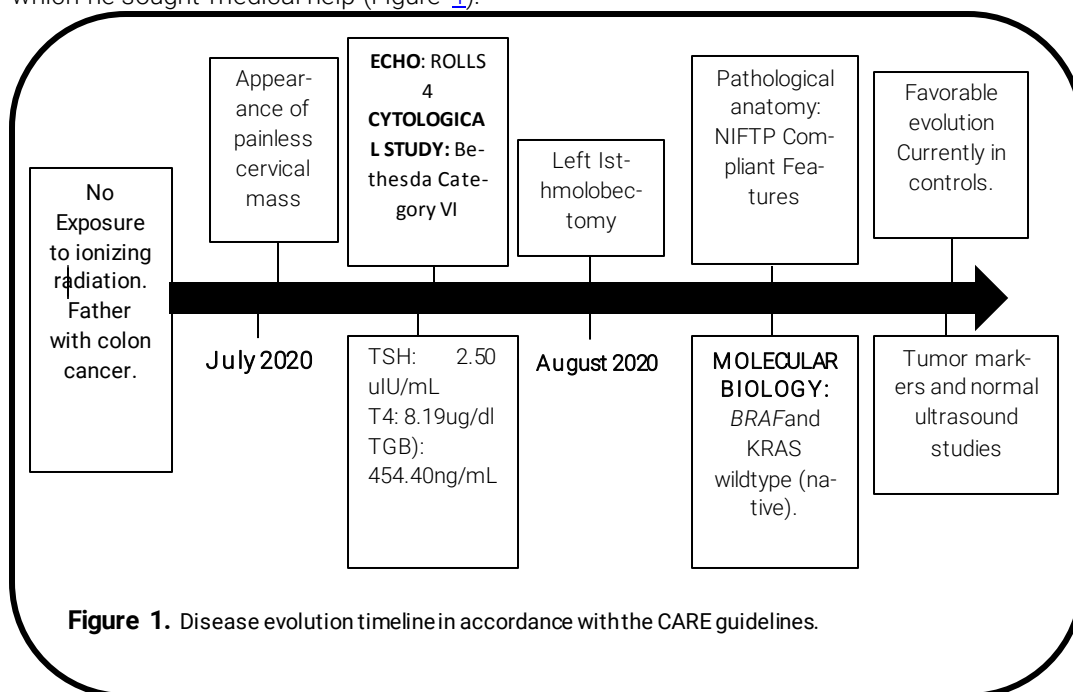
Introduction

The follicular variant of papillary thyroid cancer (PTC) is probably the most common [1, 2]. According to the 2017 World Health Organization (WHO) endocrine tumor classification, the follicular variant is subtyped as infiltrating or encapsulated [3]. Before the WHO-2017 sort, the encapsulated follicular variant without evidence of vascular invasion was considered the non-invasive variant [4, 5]; it is now known that this variant has a shallow malignant potential, which is why it was renamed noninvasive follicular thyroid neoplasia with papillary nuclear features (NIFTP) [6].

On the other hand, there has been an increase in the incidence of differentiated thyroid cancer in the last decade, especially papillary thyroid microcarcinoma, which is a papillary carcinoma less than or equal to one centimeter in size with a good prognosis and in which metastases and deaths are exceptional [7]. It is essential to differentiate between these two entities since NIFT requires surgical treatment, and microcarcinoma must be treated conventionally. A case with complete diagnostic analysis is presented: cytology, pathology, and molecular study.

Clinical case

He is a 36-year-old man with no personal medical or surgical history and no history of exposure to ionizing radiation or drug use. In his family history, he mentions that his father had colon cancer. The patient manifested ten days of evolution of a painless cervical mass, for which he sought medical help (Figure 1).



Neck ultrasound revealed the following characteristics: nodule in the left thyroid lobe, markedly hypoechoic, solid, with regular borders, 31 x 23 mm. Color Doppler showed increased central and peripheral vascularization. The ultrasound study was cataloged as TIRADS 4 (Figure 2) for which he suggested fine-needle aspiration (FNA).

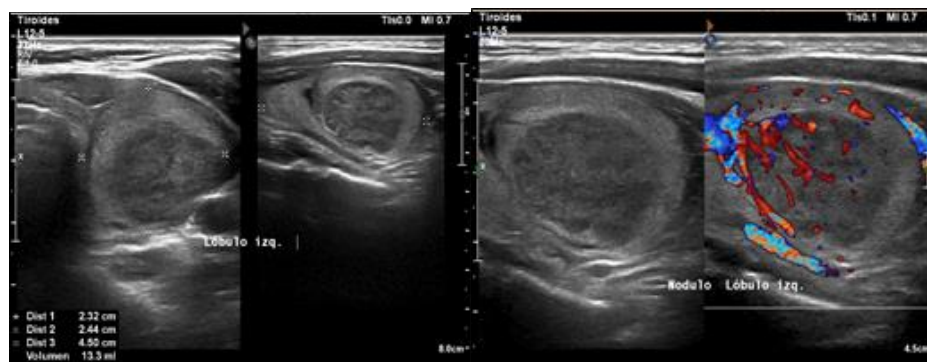


Figure 2. Thyroid ultrasound. Left thyroid nodule (31 x 23 mm), with increased vascularization.

Laboratory studies showed thyroid-stimulating hormone (TSH): 2.50 μ U/ml, T4: 8.19 μ g/dl, thyroglobulin (TGB): 454.40 ng/ml. The cytopathological study reported findings corresponding to Bethesda category VI (positive for malignancy). Likely CPT (Figure 3).

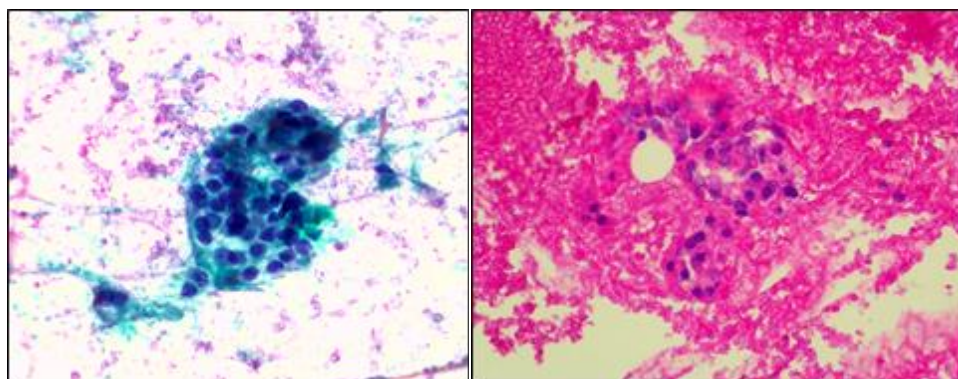


Figure 3. FNA. Cytopathological study. Papanicolaou and H&E stain (spread and block): Colloid material including thyroid follicular cells with nuclear changes consistent with loose chromatin, nuclear membrane reinforcement, and clefts, distributed sparsely and in small three-dimensional groups or flaps. Multinucleated giant cells are evident. Few lymphocytes and some neutrophils accompany.

Due to the size, ultrasound characteristics, and cytopathological findings, a left isthmolobectomy was performed. Within the intraoperative study of the piece, a solid encapsulated nodule of 28 x 27 x 17 mm was observed, with a frozen diagnosis of a follicular neoplasm, deferred for a comprehensive study of the capsule. No lymphadenopathy was found.

In the deferred evaluation of the specimen, a follicular cell neoplasm is described, with nuclear characteristics of a papillary carcinoma type and growth in a follicular pattern. No signs of capsular or vascular invasion were observed, for which an NIFTP was diagnosed (Figure 4). A molecular biology study was requested for the BRAF and KRAS genes, resulting in both wild-types (native) genes.

Evolution

The patient evolved favorably after surgery did not need levothyroxine substitution, and did not receive radioactive iodine. During the controls carried out, the patient recovered without complications.

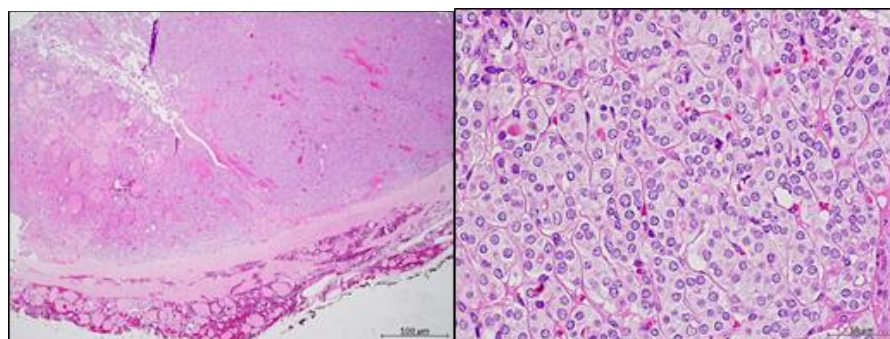


Figure 4. H&E staining. Follicular cell neoplasm, with nuclear characteristics of a papillary carcinoma type, and growth in a follicular pattern. No signs of capsular or vascular invasion are observed.

Discussion

The exposed clinical case represents a complete diagnostic analysis, with cytological, pathological, and molecular studies, which confer the diagnosis of NIFTP. His surgical intervention was conservative, without the need for other treatments, with a favorable evolution. Supported by the current clinical evidence of the low malignant potential of these entities, only annual postsurgical controls were recommended.

Follicular variant PTC is the most prevalent, recognized by its composition of neoplastic follicles instead of papillae but maintaining conventional papillary nuclear characteristics.

In the past, this variant was subdivided into infiltrative, encapsulated with invasion, and encapsulated noninvasively. In 2015, Nikiforov reported that the latter had a low risk of adverse outcomes and recurrence during follow-up, similar to follicular adenomas (FA) [8]; therefore, the ATA classified it as a low-risk neoplasm. Due to its shallow malignant potential, the term cancer was removed from its definition, changing its name to "noninvasive follicular thyroid neoplasm with papillary nuclear features," or NIFTP.

The distinction between NIFTPs and CPTs cannot be made reliably on cytological preparations due to the low risk of malignancy demonstrated for all categories of the Bethesda system, except the "nondiagnostic" type [9]. Being the postoperative anatomopathological study necessary for the diagnosis by evaluating a complete specimen.

Histological features of NIFTPs

Major Criteria

- Encapsulation or clear demarcation.
- No vascular or tumor capsule invasion.
- Follicular growth pattern with less than 1% papillae.
- Whether there are solid, trabecular, or insular patterns, the total must be less than 30% of the tumor volume.
- no bodies of psammoma.
- Core characteristics of CPT in NIFTPs (Table 1); the score must be 2 or 3.

Table 1. Nuclear Characteristics of Papillary Thyroid Carcinoma.

Size and shape	nuclear enlargement	Overlap	Crowding	Elongation
Irregularities of the nuclear membrane	irregular contours	Grooves	Pseudoinclusions	
Characteristics of chromatin	Rinsed with margin	glassy nuclei		

To qualify for NIFTP, core characteristics from at least two of the three categories must be expressed at a meaningful level.

Minor Criteria:

- dark colloid.
- Irregularly shaped follicle.
- "Spray sign."
- Follicles cleft by stroma.
- Giant multinucleated cells within the follicles•

Regarding molecular analyses, the most frequent mutations in NIFTP cases are RAS activating mutations and, less frequently, BRAF mutations [11, 12].

BRAF, TERT, RET/PTC, and RAS mutations are strongly associated with thyroid cancer. Thus, the risk of malignancy with a BRAF mutation approaches 100%, while the risk of malignancy with RAS mutations ranges from 40 to 72 additional % [13, 14]. Therefore, NIFTP is not

expected to display molecular alterations associated with classic PTC, such as BRAF V600E mutations.

Most patients with a pattern interpreted as suspicious or malignant on cytology require thyroid surgery. The choice of lobectomy versus total thyroidectomy will depend on the size of the tumor, among other reasons concerning each patient.

Under current ATA guidelines, NIFTP treatment is exclusively surgical and does not require radioactive iodine ablation. Thyroxine treatment is given if necessary, and monitoring is based on the occasional determination of tumor markers and cervical ultrasound to detect recurrence [15, 16].

Conclusions

Although there is growing evidence that follicular encapsulated variant PTC behaves very indolently, most patients are still treated as if they had conventional thyroid cancer. Therefore, in this case, we seek to emphasize the importance of distinguishing between these entities, excluding the stigma of a "cancer" diagnosis and reducing the morbidity and high costs associated with unnecessary aggressive treatment.

Editor's note

Revista Oncología Ecu remains neutral with respect to jurisdictional claims on published maps and institutional affiliations.

Abbreviations

PCT: Paillar thyroid cancer.

Administrative information

Additional Files

The authors declare none.

Acknowledgments

Does not apply.

Author contributions

Stephanie Romero Ulloa: conceptualization, validation, visualization, methodology, project management, writing proofreading and editing, data curation, formal analysis, fundraising, research, resources, software, writing -original draft.

Hamilton Abad Gualpa: conceptualization, validation, visualization, methodology, project management, writing: review and editing, data curation, formal analysis.

Juan Carlos Ruiz Cabezas: conceptualization, formal analysis, acquisition of funds, research, resources, software, writing -original draft.

Mario Leone Pignataro: conceptualization, validation, visualization, methodology, project management, writing: review and editing, data curation, formal analysis.

Fuad Huamán Garaicoa: conceptualization, validation, visualization, methodology, project management, writing: review and editing, data curation, formal analysis.

All authors read and approved the final version of the manuscript.

Financing

The authors financed the expenses incurred in this investigation.

Availability of data and materials

Data availability is available upon request to the corresponding author. No other materials were reported.

Statements**Ethics committee approval**

Does not apply.


Consent to publication

Consent for publication was obtained from the patient.


Conflicts of interest


The authors declare that they have no conflicts of competence or interest.


Author Information

Stephanie Romero Ulloa: Place of Work: National Cancer Institute "Dr. Juan Tanca Marengo. SOLCA, Guayaquil – Ecuador. Biographical data: Medical degree from the University of Guayaquil, Ecuador. She is currently in the third year of Medical Residency in Postgraduate Internal Medicine at SOLCA Guayaquil. e-mail: stephanie.romero.ul-loa@gmail.com  ORCID <https://orcid.org/0000-0001-6186-0475>

Hamilton Abbot Gualpa. Place of Work: National Oncology Institute "Dr. Juan Tanca Marengo. SOLCA, Guayaquil – Ecuador. Biographical data: Doctor of Medicine from the State University of Belgorod in Russia, Specialist in Endocrinology from the State Medical Academy of Voronezh "Burdenko" in Russia.

Juan Carlos Ruiz Heads. Place of Work: National Oncology Institute "Dr. Juan Tanca Marengo. SOLCA, Guayaquil – Ecuador. Biographical data: Doctor of Medicine and Surgery from the Santiago de Guayaquil Catholic University, Specialist in Molecular Biology from Guayaquil  ORCID: <https://orcid.org/0000-0003-2425-8754>

Mario Leone Pignataro. Place of Work: National Oncology Institute "Dr. Juan Tanca Marengo. SOLCA, Guayaquil – Ecuador. Biographical data: Doctor of Medicine and Surgery from the University of Guayaquil, Specialist in Oncological Surgery  ORCID <https://orcid.org/0000-0002-1640-948X>

Fuad Huamán Garaicoa Place of Work: National Oncology Institute "Dr. Juan Tanca Marengo. SOLCA, Guayaquil – Ecuador; ISAIN Institute of Integral Health of the Catholic University of Santiago de Guayaquil – Ecuador. Biographical data: Doctor of Medicine and Surgery. Specialist in Pathological Anatomy. Master in Medical Molecular Biology.  ORCID: <https://orcid.org/0000-0002-0541-761X>

References

1. Jung CK, Little MP, Lubin JH, Brenner AV, Wells SA Jr, Sigurdson AJ, Nikiforov YE. The increase in thyroid cancer incidence during the last four decades is accompanied by a high frequency of BRAF mutations and a sharp increase in RAS mutations. *J Clin Endocrinol Metab*. 2014 Feb;99(2): E276-85. DOI: 10.1210/jc.2013-2503. Epub 2013 Nov 18. PMID:[24248188](#); PMCID: PMC3913801.
2. Faquin WC, Wong LQ, Afrogheh AH, Ali SZ, Bishop JA, Bongiovanni M, Puztaszeri MP, VandenBussche CJ, Gourmaud J, Vaickus LJ, Baloch ZW. Impact of reclassifying noninvasive follicular variant of papillary thyroid carcinoma on the risk of malignancy in The Bethesda System for Reporting Thyroid Cytopathology. *Cancer Cytopathol*. 2016 Mar;124(3):181-7. DOI:10.1002/cncy.21631. Epub 2015 Oct 12. PMID:[26457584](#).
3. Rosai J, Albores Saavedra J, Ascoli S, et al. Papillary thyroid cancer. In: WHO Classification of Tumors of Endocrine Organs, 4th, Lloyd RV, Osamura RY, Klöppel G, Rosai J (Eds), International Agency for Research on Cancer, Lyon 2017. p.65
4. Daniels GH. What if many follicular variant papillary thyroid carcinomas are not malignant? A review of follicular variant papillary thyroid carcinoma and a proposal for a new classification. *Endocr Pract*. 2011 Sep-Oct;17(5):768-87. DOI: 10.4158/EP10407.RA. PMID:[21940284](#).
5. Ganly I, Wang L, Tuttle RM, Katabi N, Ceballos GA, Harach HR, Ghossein R. Invasion rather than nuclear features correlates with outcome in encapsulated follicular tumors: further evidence for the reclassification of the encapsulated papillary thyroid carcinoma follicular variant. *Hum Pathol*. 2015 May;46(5):657-64. DOI: 10.1016/j.humpath.2015.01.010. Epub 2015 Feb 4. PMID:[25721865](#); PMCID: PMC4981329.
6. Haugen BR, Sawka AM, Alexander EK, Bible KC, Caturegli P, Doherty GM, et al. American Thyroid Association Guidelines on the Management of Thyroid Nodules and Differentiated Thyroid Cancer Task Force Review and Recommendation on the Proposed Renaming of Encapsulated Follicular Variant Papillary Thyroid Carcinoma Without Invasion to Noninvasive Follicular Thyroid Neoplasm with Papillary-Like Nuclear Features. *Thyroid*. 2017 Apr;27(4):481-483. DOI: 10.1089/thy.2016.0628. Epub 2017 Feb 21. PMID:[28114862](#).
7. Nozaki M. [Combined use of bucolome and pyrazolone derivatives (1). Pharmacological activities and blood concentration]. *Nihon Yakurigaku Zasshi*. 1975 Sep;71(6):609-29. Japanese. PMID:[281](#).
8. Nikiforov YE, Seethala RR, Tallini G, Baloch ZW, Basolo F, Thompson L et al. Nomenclature Revision for Encapsulated Follicular Variant of Papillary Thyroid Carcinoma: A Paradigm Shift to Reduce Overtreatment of Indolent Tumors. *JAMA Oncol*. 2016 Aug 1;2(8):1023-9. DOI: 10.1001/jamaoncol.2016.0386. PMID:[27078145](#); PMCID: PMC5539411.
9. Layfield LJ, Baloch ZW, Esebua M, Kannuswamy R, Schmidt RL. Impact of the Reclassification of the Non-Invasive Follicular Variant of Papillary Carcinoma as Benign on the Malignancy Risk of the Bethesda System for Reporting Thyroid Cytopathology: A Meta-Analysis Study. *Acta Cytol*. 2017;61(3):187-193. DOI: 10.1159/000469654. Epub 2017 Apr 27. PMID:[28445876](#).
10. Lloyd RV, Asa SL, LiVolsi VA, Sadow PM, Tischler AS, Ghossein RA, ... Nikiforov, YE The evolving diagnosis of noninvasive follicular thyroid neoplasm with papillary-like nuclear features (NIFTP). *Hum Pathol* 2018, 74, 1–4.
11. Lee SE, Hwang TS, Choi YL, Kim WY, Han HS, Lim SD, Kim WS, Yoo YB, Kim SK. Molecular Profiling of Papillary Thyroid Carcinoma in Korea with a High Prevalence of BRAFV600E Mutation. *Thyroid*. 2017 Jun;27(6):802-810. DOI: 10.1089/thy.2016.0547. Epub 2017 Apr 21. PMID:[28293988](#).

12. Jiang XS, Harrison GP, Datto MB. Young Investigator Challenge: Molecular testing in noninvasive follicular thyroid neoplasm with papillary-like nuclear features. *Cancer Cytopathol.* 2016 Dec;124(12):893-900. DOI:10.1002/cncy.21802. Epub 2016 Nov 28. PMID:[27893191](#).
13. Steward DL, Carty SE, Sippel RS, Yang SP, Sosa JA, Sipos JA, et al. Performance of a Multigene Genomic Classifier in Thyroid Nodules With Indeterminate Cytology: A Prospective Blinded Multicenter Study. *JAMA Oncol.* 2019 Feb 1;5(2):204-212. DOI: 10.1001/jamaoncol.2018.4616. Erratum in: *JAMA Oncol.* 2019 Feb 1;5(2): 271. PMID:[30419129](#); PMCID: PMC6439562.
14. Guan H, Toraldo G, Cerda S, Godley FA, Rao SR, McAneny D, Doherty G, Braverman L, Lee SL. Utilities of RAS Mutations in Preoperative Fine Needle Biopsies for Decision Making for Thyroid Nodule Management: Results from a Single-Center Prospective Cohort. *Thyroid.* 2020 Apr;30(4):536-547. DOI: 10.1089/thy.2019.0116. Epub 2020 Feb 20. PMID:[31996097](#).
15. Ferris RL, Nikiforov Y, Terris D, Seethala RR, Ridge JA, Angelos P, Duh QY, Wong R, Sabra MM, Fagin JA, McIver B, Bernet VJ, Harrell RM, Busaidy N, Cibas ES, Faquin WC, Sadow P, Baloch Z, Shindo M, Orloff L, Davies L, Randolph GW. AHNS Series: Do you know your guidelines? AHNS Endocrine Section Consensus Statement: State-of-the-art thyroid surgical recommendations in the era of noninvasive follicular thyroid neoplasm with papillary-like nuclear features. *Head Neck.* 2018 Sep;40(9):1881-1888. DOI:10.1002/hed.25141. Epub 2018 Jun 26. PMID:[29947030](#); PMCID: PMC6175359.
16. Baloch ZW, Harrell RM, Brett EM, Randolph G, Garber JR; AACE Endocrine Surgery Scientific Committee and Thyroid Scientific Committee. American association of clinical endocrinologists and American college of endocrinology disease state commentary: managing thyroid tumors diagnosed as noninvasive follicular thyroid neoplasm with papillary-like nuclear features. *Endocr Pract.* 2017 Sep;23(9):1150-1155. DOI: 10.4158/EP171940.DSCR. PMID:[28920749](#).

DOI: Digital Object Identifier PMID: PubMed Identifier SU: Short URL