

## Nonsurgical management of an extensive periapical lesion combined with photodynamic therapy: a case report

### *Manejo não cirúrgico de lesão periapical extensa combinada com terapia fotodinâmica: relato de caso*

Ernani Canuto Figueirêdo Júnior<sup>1\*</sup>, Thays Chalegre Ataíde<sup>2</sup>, Eucaé Miranda Missias<sup>3</sup>, Mônica Soares de Albuquerque<sup>4</sup>, Renata Correia Sotero Dália Torres<sup>3</sup>

<sup>1</sup>Postgraduate Program in Dentistry, State University of Paraíba, Campina Grande, PB; <sup>2</sup>Dentist, specialist in Endodontics, Faculty Sete Lagoas, Recife, PE; <sup>3</sup>Institute of Dentistry of Paraíba, Campina Grande, PB; <sup>4</sup>Institute of Dentistry of Paraíba, Campina Grande, PB; Department of Dentistry, University of Pernambuco, Camaragibe, PE

#### Abstract

**Introduction:** the major goal of endodontic treatment (ET) is the complete elimination and/or maximum possible reduction of bacteria and irritants in the root canal system (RCS). However, persistence of bacterial debris refractory to therapy may lead to ET failure, being necessary to realize conventional or surgical retreatment. **Objective:** this is a case report on the nonsurgical management of an extensive chronic periapical lesion in teeth 12 and 11 in an adult female patient with history of endodontic treatment failure. She presented with painless swelling and a fistula adjacent to tooth 11. **Methodology:** conventional ET combined with photodynamic therapy (PDT) was recommended, in addition to calcium hydroxide applications. Regular clinical and radiographic follow-up made over a 2-year period revealed progression of bone regeneration, without sign and symptoms, with a satisfactory outcome. **Conclusion:** this case report shows that the combination of conservative ET with PDT provided satisfactory results with the resolution of the chronic endodontic infection and bone repair of the extensive periapical lesion.

**Keywords:** Dentistry. Endodontics. Lasers. Photodynamic Therapy. Root Canal Therapy.

#### Resumo

**Introdução:** o principal objetivo do tratamento endodôntico (TE) é a eliminação completa e/ou máxima redução possível de bactérias e irritantes no sistema de canais radiculares (SCR). Porém, a persistência de detritos bacterianos refratários à terapia pode levar ao insucesso do TE, sendo necessária a realização do retratamento convencional ou cirúrgico. **Objetivo:** este relato de caso descreve o manejo não cirúrgico de uma extensa lesão periapical crônica nos dentes 12 e 11 em paciente adulta do sexo feminino com histórico de fracasso endodôntico. A mesma queixava-se de inchaço indolor, com presença de fistula adjacente ao dente 11. **Metodologia:** preconizou-se a realização do TE convencional associado à terapia fotodinâmica (PDT), com três sessões de troca de hidróxido de cálcio, concluindo-se posteriormente o tratamento. Reavaliações clínicas e radiográficas periódicas ao longo de 2 anos revelaram a progressão da consolidação óssea, com um desfecho satisfatório. **Conclusão:** este relato de caso mostra que a combinação do TE conservador associado à PDT teve resultados satisfatórios na resolução de infecção endodôntica crônica e no reparo ósseo de lesão periapical extensa.

**Palavras chave:** Odontologia. Endodontia. Lasers. Terapia fotodinâmica. Tratamento do canal radicular.

#### INTRODUCTION

The major goal of endodontic treatment (ET) is the complete elimination and/or maximum possible reduction in the number of bacteria and irritants in the root canal system (RCS) (FIGUEIRÊDO JÚNIOR et al., 2021; JURIČ et al., 2014; SAMIEI et al., 2016; SOHRABI et al., 2016; SIQUEIRA JUNIOR et al., 2017) to levels that are compatible with RCS infection control (FIGUEIRÊDO JÚNIOR et al., 2021; SAMIEI et al., 2016; SOHRABI et al., 2016) and healing of periradicular tissues (FIGUEIRÊDO JÚNIOR et al., 2021; JURIČ et al., 2014; SIQUEIRA JUNIOR et al., 2017).

Although mechanical procedures and the use of irrigating solutions are important for infection control during ET (ASNAASHARI et al., 2017; FIGUEIRÊDO JÚNIOR et al., 2021; JURIČ et al., 2014; SOHRABI et al., 2016), in some cases when the treatment is conducted with technical deficiencies or even when performed through technically acceptable standards (SIQUEIRA JUNIOR et al., 2017) they can only remove microorganisms from the most superficial dentin layers, failing to eliminate all irritants from the RCS (SOHRABI et al., 2016) and, consequently, failing to promote total disinfection of the RCS (ASNAASHARI et al., 2017; JURIČ et al., 2014; SOHRABI et al., 2016) leading to the maintenance of the infection even after performing a previous treatment (ASNAASHARI et al., 2017; FIGUEIRÊDO JÚNIOR et al., 2021; SIQUEIRA JUNIOR et al., 2017).

Thus, the quality of disinfection obtained from che-

**Correspondente/Corresponding:** \*Ernani Canuto Figueirêdo Júnior – State University of Paraíba, Postgraduate Program in Dentistry, Department of Dentistry. – End: Rua das Baraúnas, 351, Bairro Universitário, 58429-500, Campina Grande-PB, Brazil. – Phone: + 55 (83) 99643-4667. – E-mail address: ernanicfjunior@outlook.com

momechanical procedures is affected by some limitations, especially by the anatomic complexity of the RCS (AMARAL et al., 2019; FIGUEIRÊDO JÚNIOR et al., 2021; SAMIEI et al., 2016; SIQUEIRA JUNIOR et al., 2017), compromising the full decontamination of these areas by instruments and irrigating solutions (AMARAL et al., 2019; FIGUEIRÊDO JÚNIOR et al., 2021; JURÍČ et al., 2014; SIQUEIRA JUNIOR et al., 2017). This hinders the total debridement and eradication of bacteria from the RCS (AMARAL et al., 2019; ASNAASHARI et al., 2017; FIGUEIRÊDO JÚNIOR et al., 2021; JURÍČ et al., 2014; SAMIEI et al., 2016; SIQUEIRA JUNIOR et al., 2017).

Persistence of bacterial debris in the RCS and dentinal tubules of teeth with pulp necrosis or with periapical lesions that are refractory to therapy may favor the persistence of periradicular tissue inflammation, leading to ET failure (ASNAASHARI et al., 2016; ASNAASHARI et al., 2017; FIGUEIRÊDO JÚNIOR et al., 2021; SAMIEI et al., 2016; SIQUEIRA JUNIOR et al., 2017). For a more effective cleaning of the RCS during ET (SAMIEI et al., 2016; SOHRABI et al., 2016), additional methods and complementary alternatives to the use of instruments and irrigating solutions are employed to eliminate bacterial debris from the RCS (ASNAASHARI et al., 2016; ASNAASHARI et al., 2017; EDUARDO et al., 2015; FIGUEIRÊDO JÚNIOR et al., 2021; JURÍČ et al., 2014; SAMIEI et al., 2016; SIQUEIRA JUNIOR et al., 2017; SOHRABI et al., 2016;). Among these methods and alternatives is the use of laser diode by means of photodynamic therapy (PDT), as a promising antimicrobial tool during root canal treatment or retreatment (AMARAL et al., 2019; ASNAASHARI et al., 2016; ASNAASHARI et al., 2017; EDUARDO et al., 2015; FIGUEIRÊDO JÚNIOR et al., 2021; JURÍČ et al., 2014; MOREIRA et al., 2015; SAMIEI et al., 2016; SOHRABI et al., 2016; VENDRAMINI et al., 2020). Thus, the purpose of this paper was to describe the case of a patient subjected to endodontic retreatment of an extensive chronic periapical lesion through conventional endodontic treatment, combined with antimicrobial PDT, showing satisfactory outcome through the repair of the lesion, without the need for surgical management.

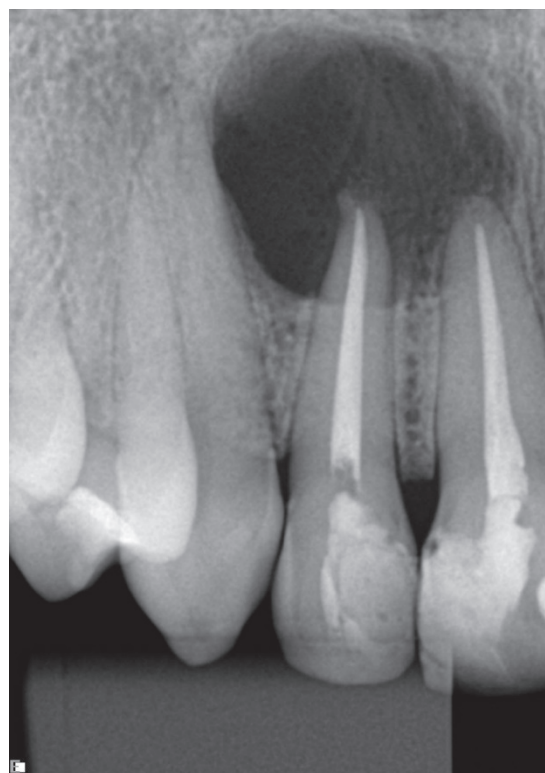## CASE REPORT

A healthy 35-year-old female patient who would undergo aesthetic rehabilitation dental procedures was referred to a private dental office in order to have a root canal retreatment of teeth 11 and 12. During anamnesis, She reported past dental history of ET of these teeth two years ago with unsatisfactory outcomes characterized by the presence of recurrent history of fistula in the region.

Extraoral examination showed non-palpable lymph nodes and no facial swelling. Intraoral examination showed swelling in the vestibular region of teeth 11 and 12, with a fistula in the alveolar mucosa adjacent to tooth 11. However, the patient reported no pain and no traumatic injury in the area. Clinical evaluation of the teeth evidenced the presence of deficient coronal restorations.

Periapical radiographic examination indicated the presence of large, clearly defined, unilocular radiolucency surrounding the apex of endodontically treated teeth 11 and 12 (Figure 1A). Based on the information collected during anamnesis and on clinical and radiographic findings, a decision was made to perform the endodontic retreatment of these teeth. Clinical and radiographic diagnoses and treatment options were debated with the patient, who agreed on endodontic retreatment as the first choice. Informed consent was obtained from the patient.

**Figure 1A** – Periapical radiographs. A) At baseline showing a radiolucent lesion associated with teeth 11 and 12;



Source: own authorship

Mepivacaine 2% containing epinephrine 1:100.000 (Dentsply, Maillefer, Ballaigues, Switzerland) was administered as local anesthetic. Thereafter, a rubber dam was applied and coronal restorations were removed. The removal of gutta percha was initially performed using ultrasound Newtron booster (Satelec, Fenton MO) and the ClearSonic insert (Helse, São Paulo, SP, Brazil), complementing with rotary file Prodesing Logic® 40.05 (Easy Equipamentos Odontológicos, Belo Horizonte, MG, Brasil). After the complete removal of gutta percha and establishment of a straight-line access, the pulp chamber was irrigated with 5 mL of 2.5% sodium hypochlorite (NaOCl) solution and the root canals were hand-instrumented using a #10 K-File (Dentsply, Maillefer, Ballaigues, Switzerland) and irrigated with 5 mL of 2.5% of NaOCl solution. After that, the canal was instrumented with a ProDesign Logic 40.05 file (Easy

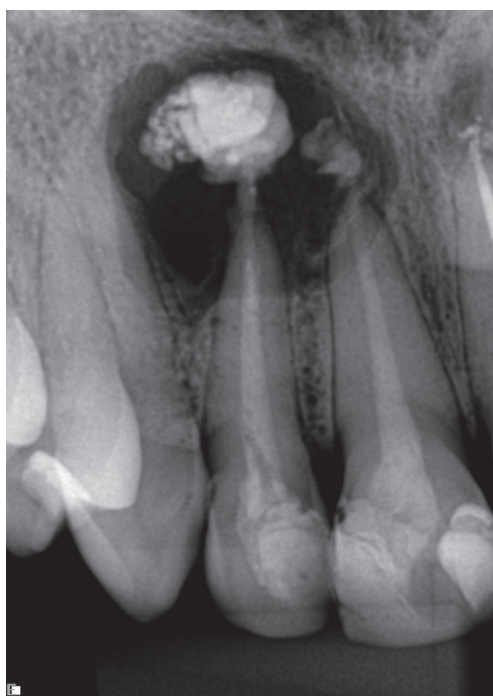Equipamentos Odontológicos, Belo Horizonte, MG, Brazil) using soft file movements up to the radiographic tooth length minus 4 mm. After reaching the desired length, odontometric measurements were made with an apical locator to confirm the actual tooth length (ATL) and actual working length (AWL). After confirmation, apical preparation was obtained with the use of hand K-files #60 and #70 (Dentsply, Maillefer, Ballaigues, Switzerland).

After AWL instrumentation, the root canals were irrigated with 2.5% NaOCl solution stirred with Easyclean file (Easy Equipamentos Odontológicos, Belo Horizonte, MG, Brazil) for 1 minute, with subsequent irrigation with 17% EDTA (ethylenediaminetetraacetic acid) solution, also stirred with Easyclean file.

After these procedures, PDT was performed as used by De Oliveira et al. (2018). To do that, the root canals were irrigated with 0.01% methylene blue solution (Chimilux®; Hypofarma, Belo Horizonte, MG, Brazil) as photosensitizer using a pre-irradiation time of 3 minutes. Subsequently, laser irradiation was performed using a red laser diode (Whitening Laser II, DMC Equipamentos Ltda., São Carlos, SP, Brazil) for 3 minutes (Parameters: wavelength = 660 nm; power = 100 mW; diameter tip = 30 mm; energy = 18 J; energy density = 660 J/cm<sup>2</sup>; continuous emission mode).

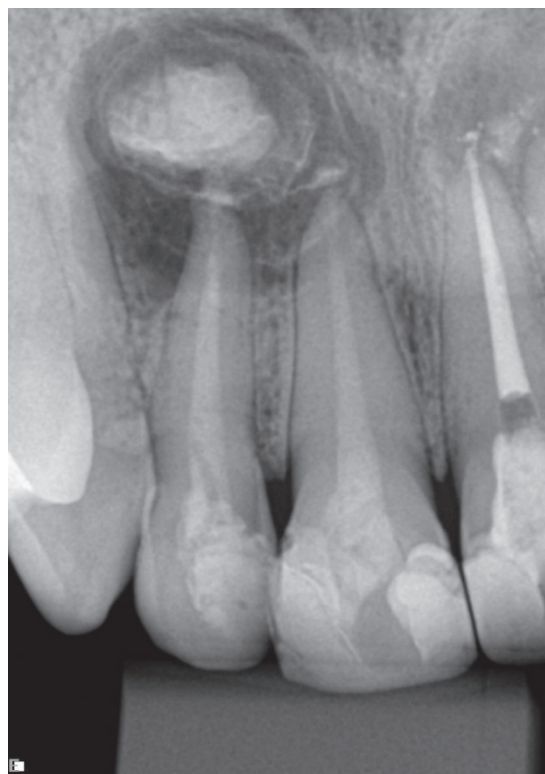The treatment was performed in multiple sessions, due the presence of exudation associated with the teeth. Thus, Ultracal®XS (Ultradent Products, Inc., US) calcium hydroxide paste was used as intracanal medicament, with two replacements (Figures 1B and 1C), aiming to control the persistent exudation verified between the return sessions.

**Figure 1B** – After instrumentation's first session with addition of intracanal medication



Source: own authorship

**Figure 1C**–After second session of replacement of intracanal medication



Source: own authorship

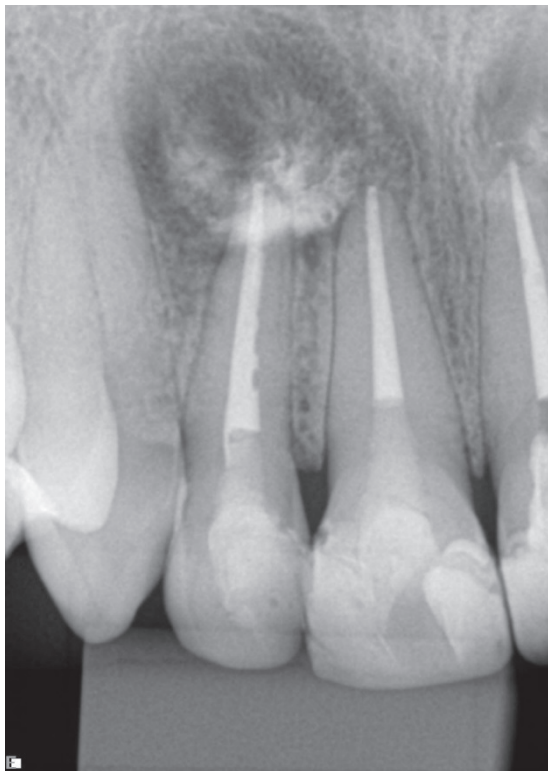
Since combined use of PDT associated with intracanal medication increases the reduction of microorganisms, SCR was irradiated prior to placement of calcium hydroxide paste, aiming to increase its antimicrobial efficiency.

After removal of intracanal medication, the root canals were abundantly irrigated interspersing 2.5% NaOCl solution and 17% EDTA solution for 1 minute to remove residual calcium hydroxide paste and were then dried with sterile absorbent paper points (Dentsply, Maillefer, Ballaigues, Switzerland).

After that, other laser irradiation was performed following the same parameters mentioned above and then the root canals were dried with sterile absorbent paper points (Dentsply, Maillefer, Ballaigues, Switzerland) and sealed with gutta-percha by the continuous wave technique, using AhPlus cement (Dentsply-DeTrey, Konstanz, Germany) (Figure 1D). Finally, shielding and coronal sealing were performed with Filtek bulk-fill resin (3M-Espe, St. Paul, MN, USA). The patient was followed up for 2 years and she did not report any signs or symptoms during that period. At the end of the follow-up period, the initial lesion showed radiographic evidence of remineralization and bone healing (Figure 1E).

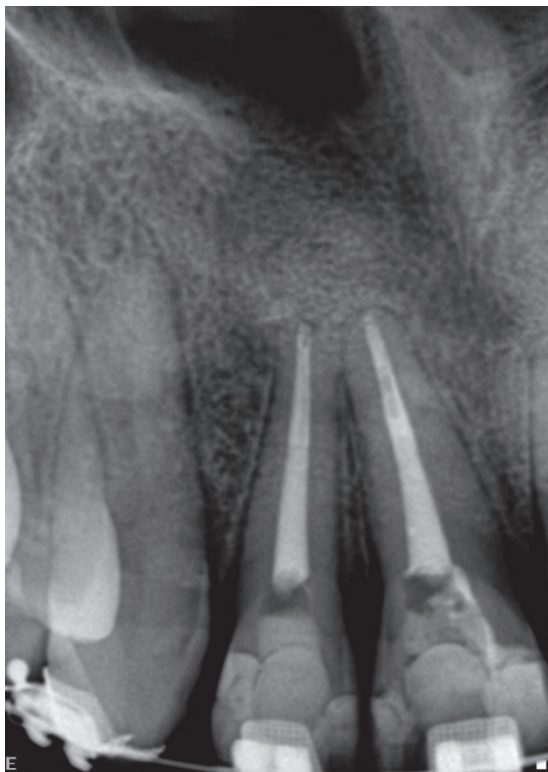

**Figure 1D** – Final periapical radiograph after root canal filling



Source: own authorship

**Figure 1E** – After 24-month follow-up of endodontic treatment.



Source: own authorship

## DISCUSSION

Microbial invasion of pulp tissues may lead to pulp necrosis and infiltration into periradicular tissues, causing periapical lesions, whose treatment consists of either nonsurgical or surgical endodontic therapy (GHORBANZADEH et al., 2017).

However, ET has some limitations that hinder treatment success. During chemomechanical preparation of the root canal, it is not uncommon to come across some difficulties and anatomic variations that may interfere with cleaning and shaping procedures, possibly resulting in bacterial persistence in the RCS (LIMA et al., 2019; SIQUEIRA JUNIOR et al., 2017).

The major cause for ET failure is the persistence of microorganisms in the RCS (AMARAL et al., 2019; ASNAASHARI; HOMAYUNI; PAYMANPOUR, 2016; JURICH et al., 2014; LIMA et al., 2019; SIQUEIRA JUNIOR et al., 2017; SOHRABI et al., 2016). As a result, microbial colonization of the SCR can lead to the occurrence of periapical abscess, granulomas or apical cysts and fistula formation occurs as a consequence of the suppurative process of a periapical abscess (ASNAASHARI, et al., 2017). In this context, the findings evidenced in the present clinical case report corroborate these aspects, since the teeth previously endodontically treated had unsatisfactory outcomes, presenting residual and permanent infection characterized by a recurrent history of fistula.

Although the teeth did not present anatomical difficulties, it is pertinent to emphasize that as described by Siqueira Junior et al. (2017), microorganisms may persist particularly in areas that cannot be accessed through chemomechanical procedures, such as curved canals, isthmuses, craters, and apical recesses and ramifications present in the RCS, besides complex anatomic structures such as lateral canals, oval-shaped canals, and C-shaped canals. These aspects end up hindering endodontic treatment, as instruments are primarily utilized in the main canal and, therefore, the cleaning and disinfection of these areas rely chiefly on the chemical effects of irrigating solutions and intracanal medicament (SIQUEIRA JUNIOR et al., 2017).

The microbiota of the RCS is characterized by polymicrobial and morphotypical diversity, with the presence of anaerobic microorganisms in cases of primary endodontic infection (AMARAL et al., 2019; ASNAASHARI; HOMAYUNI; PAYMANPOUR, 2016) and frequent association of facultative gram-positive microorganisms in teeth with endodontic treatment failure (ASNAASHARI; HOMAYUNI; PAYMANPOUR, 2016), being this last condition associated in the present clinical case report since the teeth were previously endodontically treated, presenting, however, unsatisfactory outcomes to the primary treatment.

The prognosis of endodontic retreatment is remarkably poorer than that of primary endodontic treatment due to the presence of more resistant microorganisms (MOREIRA et al., 2015; ASNAASHARI; HOMAYUNI; PAY-

MANPOUR, 2016). Among such microorganisms, *Enterococcus faecalis* is the main agent associated with cases of endodontic treatment failure, especially in persistent periradicular lesions after previous endodontic treatment (ASNAASHARI et al., 2016; ASNAASHARI; HOMAYUNI; PAYMANPOUR, 2016; LIMA et al., 2019; SAMIEI et al., 2016; SOHRABI et al., 2016; VENDRAMINI et al., 2020), being resistant to most intracanal medication and to the chemical-mechanical procedures (LIMA et al., 2019). In addition, this microorganism has capacity to form intraradicular and extraradicular biofilms that are extremely difficult to eliminate from root canals (SAMIEI et al., 2016; VENDRAMINI et al., 2020), besides shows ability to withstand adverse conditions such as variations in pH, temperature and O<sub>2</sub> concentration inside the RCS (VENDRAMINI et al., 2020).

Thus, since inadequate decontamination of the RCS may lead to ET failure and to the development of persistent periapical pathological lesions (ASNAASHARI; HOMAYUNI; PAYMANPOUR, 2016; ASNAASHARI, et al., 2017; LIMA et al., 2019; MOREIRA et al., 2015; SIQUEIRA JUNIOR et al., 2017), it is necessary to adopt strategies to handle the presence of resistant or refractory microorganisms in the RCS (ASNAASHARI; HOMAYUNI; PAYMANPOUR, 2016; ASNAASHARI, et al., 2017; FIGUEIRÊDO JÚNIOR et al., 2021; LIMA et al., 2019; MOREIRA et al., 2015; SAMIEI et al., 2016; SIQUEIRA JUNIOR et al., 2017). Among these strategies, adjuvant approaches such as PDT have been used during conventional ET and retreatment (ASNAASHARI; HOMAYUNI; PAYMANPOUR, 2016; ASNAASHARI et al., 2017; EDUARDO et al., 2015; FIGUEIRÊDO JÚNIOR et al., 2021; LIMA et al., 2019; MOREIRA et al., 2015; SIQUEIRA JUNIOR et al., 2017; VENDRAMINI et al., 2020), similarly to the present clinical case report, as well as during surgical ET (DE OLIVEIRA et al., 2018).

PDT is based on the chemical interaction that results from the use of low-power laser therapy with a photosensitive dye that is able to take up the photons, excite the electrons, and later transfer energy to tissue oxygen molecules, forming reactive oxygen species (ROS) such as singlet oxygen. The antimicrobial activity is obtained from the cytotoxic effects of free radicals on the damage caused to the cell membrane and organelles, affecting proteins, lipids, nucleic acids and other cellular microbial components, leading to cell death and selectively eradicating these microorganisms (AMARAL et al., 2019; ASNAASHARI et al., 2017; DE OLIVEIRA et al., 2018; EDUARDO et al., 2015; FIGUEIRÊDO JÚNIOR et al., 2021; JURIČ et al., 2014; LIMA et al., 2019; SAMIEI et al., 2016; VENDRAMINI et al., 2020).

Among photosensitizing agents, methylene blue has proven to be effective in PDT for root canal treatment (AMARAL et al., 2019; ASNAASHARI et al., 2016; DE OLIVEIRA et al., 2018; EDUARDO et al., 2015; FIGUEIRÊDO JÚNIOR et al., 2021; JURIČ et al., 2014; LIMA et al., 2019; SAMIEI et al., 2016) at concentrations ranging from 0.01% to 0.001% (SAMIEI et al., 2016), but the literature

also describes the use of 0.005% (AMARAL et al., 2019; EDUARDO et al., 2015).

Use of PDT in endodontics, called laser-assisted endodontics (SOHRABI et al., 2016), combines use of laser irradiation with mechanical preparation of RCS and use of chemical irrigants (FIGUEIRÊDO JÚNIOR et al., 2021; SAMIEI et al., 2016; VENDRAMINI et al., 2020). Their use represents a supplementary alternative to chemomechanical procedures often employed for RCS disinfection, complementing the effects obtained with conventional disinfection (ARNEIRO, et al., 2014; FIGUEIRÊDO JÚNIOR et al., 2021; VENDRAMINI et al., 2020). PDT has proven to be a thriving antimicrobial treatment, eradicating microorganisms in endodontic infections (ARNEIRO et al., 2014; DE OLIVEIRA et al., 2018; FIGUEIRÊDO JÚNIOR et al., 2021; GARCEZ et al., 2010; VENDRAMINI et al., 2020). In addition, combined therapy of conventional treatment and PDT it stands out for its higher antibacterial activity (ARNEIRO et al., 2014; GARCEZ et al., 2010; VENDRAMINI et al., 2020), which can be resulted from the deeper penetration of photosensitizing agents into the dentinal tubules and RCS, combined with laser application in areas that cannot be easily accessed by conventional decontamination techniques used in ET, promoting eradication of resistant microorganisms (SAMIEI et al., 2016).

PDT is indolent, easily applied, and safe for periapical tissues and is efficient in eradicating microorganisms, with a broad spectrum of antimicrobial activity. Moreover, PDT does not cause microbial resistance and is also efficient in endotoxin inactivation, thus demonstrating safety and efficiency in endodontic decontamination (DE OLIVEIRA et al., 2018; FIGUEIRÊDO JÚNIOR et al., 2021; VENDRAMINI et al., 2020).

In the present case report, PDT combined with endodontic retreatment was performed in accordance with the laser usage parameters proposed by De Oliveira et al. (2018), utilizing methylene blue at the concentration of 0.01%, as described by Asnaashari; Homayuni; Paymanpour (2016), Eduardo et al. (2015) and Oliveira et al. (2018) since this concentration is indicated according Eduardo et al. (2015), in cases where there is the presence of exudate, blood, saliva or protein fluids in the root canals and/or in the region of interest.

In addition, among the multiple sessions in this case report, calcium hydroxide was used as intracanal medication, justified by its clinical applications in endodontic therapy like antimicrobial effects as an intra-canal dressing (MOHAMMADI; DUMMER, 2011; PEREIRA et al., 2019; ZANCAN et al., 2016); beneficial effects in the control of exudate in teeth with periapical lesions associated with persisting exudation (MOHAMMADI; DUMMER, 2011; LIMA et al., 2019), as seen in this case report, due to the persistence of exudation between the sessions; and beyond their effects on mineralization process in bone repair (MOHAMMADI; DUMMER, 2011; ZANCAN et al., 2016). Thus, satisfactory results were corroborated by its stimulation of the resolution of periapical inflammation

through the elimination of residual microorganisms, as well as effects in neutralization of endotoxins according to results highlighted by Ghorbanzadeh et al. (2017)

In addition, PDT was used prior to the placement of calcium hydroxide paste, increasing the effectiveness of this intracanal medication on persistent infection, aspect reported in the literature (EDUARDO et al., 2015; GARCEZ et al., 2010), including in more severe cases such as infections where there is antibiotic-resistant microorganisms (GARCEZ et al., 2010). In this context, Garcez et al. (2010) emphasize that the increase in local pH (obtained from the use of calcium hydroxide) associates with the increase in ROS (produced through PDT) potentiates the photodynamic effect on persistent microorganisms during sessions.

Considering the presence of fistulas associated with residual and permanent infection, the use of PDT adjuvant to ET was also used since this strategy has been used showing successful results in the resolution of fistulas associated with persistent extraradicular infections such as abscesses, granulomas or apical cysts (ASNAASHARI et al., 2017; EDUARDO et al., 2015; MOREIRA et al., 2015), similarly to the present clinical case report, as well as fistulas arising from iatrogenic conditions (LIMA et al., 2019).

As previously reported by Eduardo et al. (2015), the use of PDT can contribute to the clinical success, showing remission of persistent fistulas associated with persistent endodontic infections after successive changes of intracanal medication. The findings of the present clinical case corroborated these aspects since there was remission of the fistula and after a considering follow-up period the teeth was asymptomatic, with absence of fistula and showing radiographically evidence of bone healing.

In cases of presence of fistula, the application of PDT has been reported through direct application via intracanal (ASNAASHARI et al., 2017), as performed in the present clinical case, as through its application via the fistulous tract (MOREIRA et al., 2015), or through the combined application intracanal and inside the fistula (EDUARDO et al., 2015), showing satisfactory results in both cited studies.

After a 24-month follow-up period following endodontic retreatment, the outcomes of the present case report show evidence of the efficiency of the treatment used, especially with regard to the benefits of PDT through laser-assisted endodontics, corroborating that its may be useful as adjuvant therapy for endodontic disinfection, according to different studies and evidences previously cited. Besides this, the satisfactory outcome also allowed us to corroborate that the combination of endodontic therapy and the use of PDT represents a satisfactory strategy in the remission of fistulas of endodontic origin, as reported by Asnaashari et al. (2017), Eduardo et al. (2015) and Moreira et al. (2015).

## CONCLUSION

The present case confirms the success of endodontic retreatment of an extensive periapical lesion after nonsurgical therapy. The concomitant use of PDT and intracanal medicament (calcium hydroxide) for RCS disinfection, carried out in multiple sessions, produced successful treatment outcomes after a 24-month follow-up, as shown in the radiographic images.

## REFERENCES

- AMARAL, R. R. et al. Antimicrobial Photodynamic Therapy associated with long term success in endodontic treatment with separated instruments: A case report. *Photodiagnosis photodyn. ther.*, Amsterdam, v. 26, p. 15-18, June 2019.
- ARNEIRO, R. A. et al. Efficacy of antimicrobial photodynamic therapy for root canals infected with *Enterococcus faecalis*. *J. oral sci.*, Tokyo, v. 56, n. 4, p. 277-285, Dec. 2014.
- ASNAASHARI, M. et al. Laser assisted treatment of extra oral cutaneous sinus tract of endodontic origin: A Case Report. *Lasers med. sci.*, Tehran, v. 8, Suppl 1, p.S68-S71, Summer 2017.
- ASNAASHARI, M. et al. Comparison of the antibacterial effect of 810 nm diode laser and photodynamic therapy in reducing the microbial flora of root canal in endodontic retreatment in patients with peri radicular lesions. *Lasers med. sci.*, Tehran, v.7, n. 2, p. 99-104, Spring 2016.
- ASNAASHARI, M.; HOMAYUNI, H.; PAYMANPOUR, P. The antibacterial effect of additional Photodynamic Therapy in failed endodontically treated teeth: a pilot study. *Lasers med. sci.*, Tehran, v. 7, n. 4, p. 238-242, Fall 2016.
- DE OLIVEIRA, B. P. et al. Photodynamic therapy: a novel ally for surgical endodontic treatment? Case report. *Lasers med. sci.*, Tehran, v. 9, n. 4, p. 288-290, Fall 2018.
- EDUARDO, C. P. et al. A terapia fotodinâmica como benefício complementar na clínica odontológica. *Rev. Assoc. Paul. Cir. Dent.*, São Paulo, v. 69 n. 3, p. 226-235, jul./set. 2015
- FIGUEIRÊDO JÚNIOR, E. C. et al. Terapia fotodinâmica antimicrobiana como recurso adjuvante no tratamento endodôntico em dentes infectados: análise bibliométrica e revisão de literatura. *Arch. health invest.*, Araçatuba, v.10, n.1, p.179-186, Jan. 2021.
- GARCEZ, A. S. et al. Photodynamic therapy associated with conventional endodontic treatment in patients with antibiotic-resistant microflora: a preliminary report. *J. Endod.*, Chicago, v. 36, n. 9, p. 1463-1466, Sept. 2010.
- GHORBANZADEH, S. et al. Nonsurgical management of a large periapical lesion: A case report. *Iran. endod. j.*, Tehran, v. 12, n. 2, p. 253-256, Spring 2017.
- JURIČ, I. B. et al. The antimicrobial effectiveness of photodynamic therapy used as an addition to the conventional endodontic re-treatment: a clinical study. *Photodiagnosis photodyn. ther.*, Amsterdam, v. 11, n. 4, p. 549-555, Dec. 2014.
- LIMA, S. P. et al. Photodynamic therapy as an aiding in the endodontic treatment: case report. *Rev. gaúch. odontol.*, Porto Alegre, v.67, p.e20190030, Jun. 2019
- MOHAMMADI, Z.; DUMMER, P. M. Properties and applications of calcium hydroxide in endodontics and dental traumatology. *Int. endod. j.*, Oxford, v. 44, n. 8, p. 697-730, Aug. 2011.



MOREIRA, M. S. N. A. et al. Posttreatment apical periodontitis successfully treated with antimicrobial photodynamic therapy via sinus tract and laser phototherapy: report of two cases. **Photomed. laser surg.**, Larchmont, v.33, n.10, p.524-528, Oct. 2015

PEREIRA, T. C. et al. Intratubular decontamination ability and physicochemical properties of calcium hydroxide pastes. **Clin. oral invest.**, Berlin, v. 23, n. 3, p. 1253-1262, Mar. 2019.

SAMIEI, M. et al. The antibacterial efficacy of photo activated disinfection, chlorhexidine and sodium hypochlorite in infected root canals: An in vitro study. **Iran. endod. j.**, Tehran, v. 11, n. 3, p. 179-183, Summer 2016.

SIQUEIRA JUNIOR, J. F. et al. Unprepared root canal surface areas:

causes, clinical implications, and therapeutic strategies. **Braz. oral res.**, São Paulo, v. 32, supl. 1, p. e65, Oct. 2018.

SOHRABI, K. et al. Antibacterial activity of diode laser and sodium hypochlorite in *Enterococcus Faecalis*-contaminated root canals. **Iran. endod. j.**, Tehran, v. 11, n. 1, p. 8-12, Winter 2016.

VENDRAMINI, Y. et al. Antimicrobial effect of photodynamic therapy on intracanal biofilm: a systematic review of in vitro studies. **Photodiagnosis photodyn. ther.**, Amsterdam, v. 32, n.102025, Dec. 2020.

ZANCAN, R. F. et al. Antimicrobial activity and physicochemical properties of calcium hydroxide pastes used as intracanal medication. **J. endod.**, Chicago, v. 42, n. 12, p. 1822-1828, Dec. 2016.

---

Submetido em: 03/11/2020

Aceito em:18/08/2021