

Amigdalial focus of ludwig's angina expanding to mediastinitis – A success case

Angina de ludwig de foco amigdalial evoluindo para mediastinite – Um caso de sucesso

Letícia Lima Santos¹, Igor de Andrade Lima², Rommel de Sousa Carneiro², Lucas Rodrigues Laudaes Costa³, Eudes Kennedy de Souza Júnior³

ABSTRACT

Objective: report and describe the satisfactory evolution of Ludwig's Angina due to a tonsillary infection, which evolved to mediastinitis and sept shock. The work aims to detail the clinical and diagnostic aspects of this serious illness, in addition to the therapy used in this case. **Method:** the information was obtained from the patient's medical record, as well as from the reports of the imaging tests performed. The literature review was carried out in the PUBMED database. **Final considerations:** the case studied has great importance for the medical community, since it reports a rare favorable outcome for a case of Ludwig's Angina complicated with an mediastinitis, whose mortality is described up to 50% of the cases. The surgical approach combined with early antibiotic therapy is shown to be the best approach for these cases.

Keywords: Ludwig's angina; odontogenic infection; acute airway obstruction; mediastinitis.

RESUMO

Objetivo: relatar e descrever a evolução satisfatória de uma Angina de Ludwig decorrente de uma infecção amigdaliana, que evoluiu para mediastinite e choque séptico. O trabalho visa detalhar os aspectos clínicos e diagnósticos desta grave doença, além da terapêutica empregada neste caso. **Método:** as informações foram obtidas do prontuário do paciente, bem como dos laudos dos exames de imagem realizados. A revisão da literatura foi feita na base de dados PUBMED. **Considerações finais:** o caso estudado relata um raro desfecho favorável de uma Angina de Ludwig que evoluiu para mediastinite, cuja taxa de mortalidade é de até 50% dos casos. A abordagem cirúrgica combinada com antibioticoterapia precoce se mostra ser a melhor conduta para estes casos.

Palavras-chave: Angina de Ludwig; infecção odontogênica; obstrução aguda das vias aéreas; mediastinite.

¹ Universidade José do Rosário Velano UNIFENAS, Alfenas - MG, Brazil.

² Hospital Universitário Alzira Velano, Serviço de Cirurgia Geral e Traumatologia, Alfenas - MG, Brazil.

³ Hospital Universitário Alzira Velano, Serviço de Cirurgia Geral, Alfenas - MG, Brazil.

Institution:

UNIFENAS. Endereço Rodovia MG-179, Alfenas - MG, Brazil.

* Corresponding Author:

Letícia Lima Santos

E-mail: leticialimasantos23@gmail.com

Received on: 02/17/2021.

Approved on: 05/11/2021.

INTRODUCTION

Ludwig's Angina is a diffuse polymicrobial gangrenous cellulitis in the submandibular, sublingual and submental space, potentially fatal and capable of affecting adjacent tissues¹. Odontogenic infections are the main causes of this disease, but there are also other known etiological factors, such as tonsillar abscess, osteomyelitis and mandible fracture². Clinically, Ludwig's Angina manifests with sudden onset odynophagia, pain radiating to the cervical region, neck hard on palpation and edema and protrusion of the tongue³. Progression to mediastinitis and acute airway obstruction are the most serious and death-related complications. The mortality rate is described in up to 8% of cases, however, the presence of mediastinitis increases mortality to up to 50% of the cases⁴. Therefore, early diagnosis and treatment of this condition is extremely important.

CASE REPORT

Male patient, 48 years old, drug addict and alcoholic, was admitted to the emergency room with a history of tonsillitis in treatment during a week using Azithromycin, presenting worsening of the general condition associated with dyspnea and orthopnea. Upon physical examination on admission, patient was in respiratory failure, hemodynamically stable, with painful and hyperemic bulging in the submental region, associated with subcutaneous emphysema of the upper thoracic region, extending throughout the anterior cervical region. The condition was diagnosed as Ludwig's Angina. Due to respiratory failure, orotracheal intubation with ventilatory support in the emergency room was indicated. The chest X-ray showed a more important pleural effusion on the left. The closed pleural drainage on the left was performed on the 1st day of hospitalization (IHL) and obtained content with a thick, dark appearance and a foul odor, suggesting empyema due to contiguity. The computed tomography (CT) scan of the chest performed in sequence showed a periamygdalian collection on the right, with gaseous foci and communication with emphysema from the cervical region to the mediastinum; bilateral pleural effusion; frosted glass signals and bilateral subpleural vesicles; laminar pneumothorax at the left thoracic apex (Figure 1). Empirical antibiotic therapy was then staggered for Cefepime, Clindamycin and Vancomycin. Cervical surgical drainage was indicated and the patient underwent a wide Kocher collar cervicotomy, which identified anterior cervical tissue with necrosis and fetid-looking exudate affecting cervical muscle fasciae (Figure 2). In this same approach, a tracheostomy was performed to protect the airway. The assessment of the maxillofacial team ruled out odontogenic infection, confirming the tonsillar etiology of Ludwig's Angina. In the first postoperative days, the patient developed severe septic shock, requiring high doses of vasoactive amines, associated with dialysis renal failure. The thoracic drain maintained the exit of piosserous secretion. On the 7th IHL, the patient showed clinical improvement, with reduced doses of vasoactive amines, recovery of renal function and improvement in the aspect of drained chest secretion. On the 13th IHL, guided by tracheal secretion culture, Imipenem was

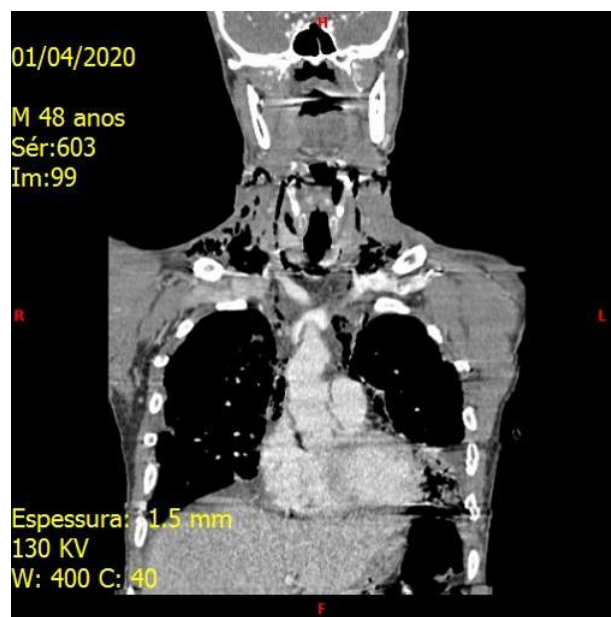


Figure 1. Changes found in computed tomography (CT) of the chest performed at the patient's hospital admission: periamygdalian collection on the right, with gaseous foci and communication with emphysema from the cervical region to the mediastinum; bilateral pleural effusion; frosted glass signals and bilateral subpleural vesicles; laminar pneumothorax at the left thoracic apex.

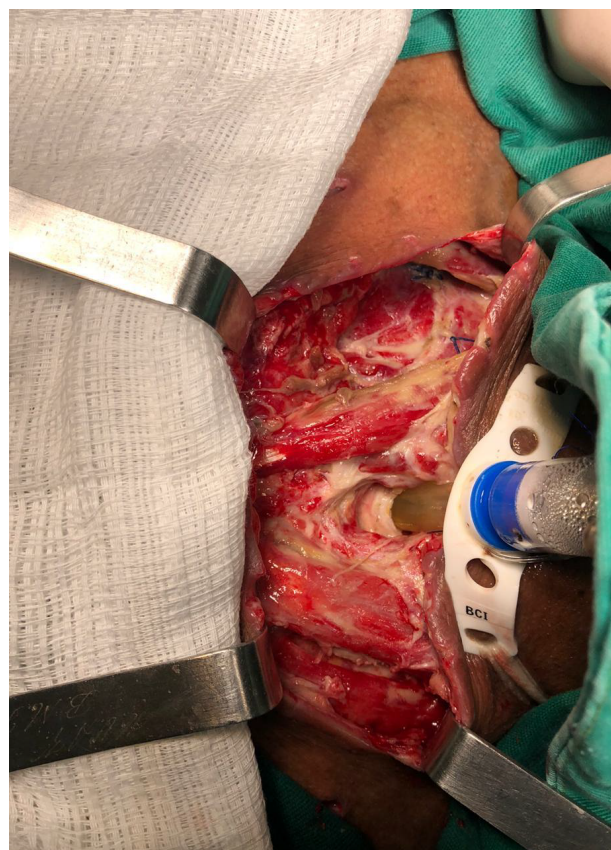

Figure 2. Cervicotomy by wide Kocher collar, showing anterior cervical tissue with necrosis and foul-smelling exudate affecting cervical muscle fasciae. Tracheostomy performed during the same surgical approach.

started and the other antibiotics were suspended. On the 15th IHL, the new chest CT showed regression of cervical and mediastinal emphysema and persistence of tonsillar abscess (Figure 3). The following day, due to the presence of local abscesses, a new cervicotomy was performed to wash the anatomical site and drain the tonsillar collection (Figure 4). On the 16th IHL, necrosis was identified in toes of the right foot and necrosis of the left forefoot, due to ischemia caused by the prolonged use of high-dose vasoactive amines. The Vascular Surgery team guided conservative conduct until the delimitation of ischemia. On the 17th IHL, new results of culture of the secretion of the tonsillar abscess indicated the need to exchange Imipenem for Polymyxin B, since there was presence of multidrug-resistant *Acinetobacter*. The patient showed significant improvement in the following days and, on the 29th IHL, antibiotics were discontinued. On the 33rd IHL, the patient was referred to the ward, remaining in a regular general state, lucid, malnourished, using BiPAP by tracheostomy and with dry necrosis of the toes bilaterally. After three weeks, left transtibial amputation and from the second to the fifth toes on the right amputation surgery was performed. The patient was hospitalized in the ward for three days after the amputation and was discharged home in good general condition, lucid, malnourished, with good oral acceptance and with a good cervicotomy scar. He performed follow-up during three months with the General Surgery team. After improving his health status and completely closing the surgical scar, he was referred for follow-up with the Vascular Surgery team to care for ischemic sequelae.

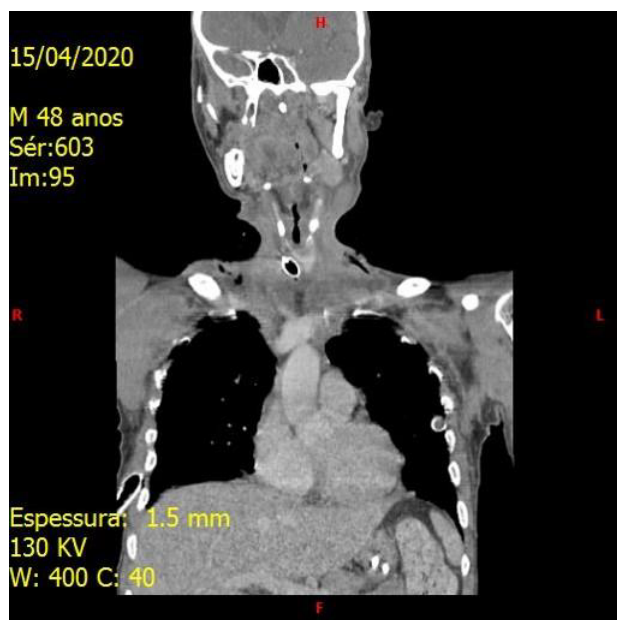


Figure 3. New chest CT showing regression of cervical and mediastinal emphysema and persistence of tonsillar abscess.

DISCUSSION

Ludwig's Angina is a gangrenous cellulitis that affects the submandibular, sublingual and submental spaces, whose ability to spread through adjacent tissues is a remarkable feature ¹. Although odontogenic infections cause 90% of the cases, other known etiologies are penetrating lesions on the floor of the

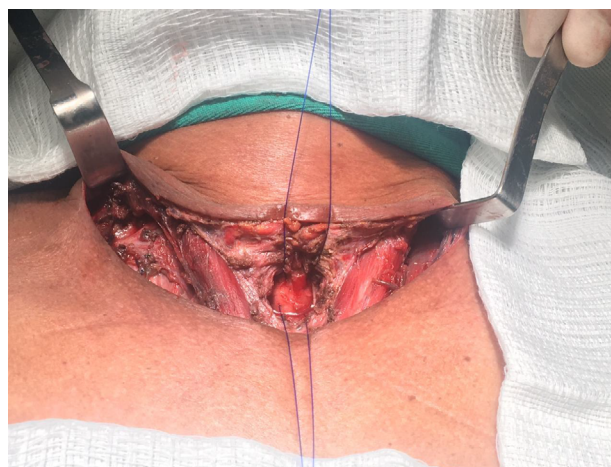

Figure 4. Aspect of the cervical cavity after performing a second cervicotomy to wash the anatomical site and drain the tonsillar collection.

mouth, tonsillar abscess, osteomyelitis, fracture of the jaw, otitis media, suppurative parotitis, tongue piercing, sialoadenitis or sialolithiasis of the submandibular glands ¹. Alcoholism, drug addiction, malnutrition, diabetes and immunosuppression states are considered aggravating factors ².

The microbiology that causes Ludwig's Angina is polymicrobial. The most involved pathogens are *Streptococcus viridans* and *Staphylococcus aureus*, however anaerobes such as *Bacteroides*, *Peptostreptococcus* and *Peptococcus* are also frequent causes of this infection ².

The typical characteristics of the disease are involvement bilaterally in more than one deep space of the cervical region; presence of gangrene or serosanguinolent infiltration, with or without pus; connective tissue, fascia and muscle involvement, but sparing glandular structures; migration to the adjacent fascia instead of the lymphatic system ².

The patient presents with sudden onset odynophagia, pain radiating to the cervical region, neck hard on palpation and edema and protrusion of the tongue ³. Tongue edema gives the appearance of a "double tongue" ⁵. Other findings of the physical examination include fever, trismus, stridor, adynamia and dyspnea ⁶.

The diagnosis of this condition is clinical, but complementary exams such as computed tomography and cervical ultrasound can be useful not only to confirm the diagnosis, but also to assess the severity of regional edema and the risk of airway involvement ⁶.

The main differential diagnoses to be ruled out are angioneurotic edema, cervical cellulitis, lingual carcinoma, lymphadenitis, peritonsillar abscess, salivary gland abscess and sublingual hematoma ².

Complications of Ludwig's angina include airway obstruction, mediastinitis, sepsis, septic shock, internal jugular vein thrombophlebitis, empyema, necrotizing fasciitis, pericardial effusion, osteomyelitis, subphrenic abscess, aspiration pneumonia and pleural effusion ⁴.

Airway obstruction and the consequent appearance of acute respiratory failure are due to progressive swelling of the tongue, inflammation of the pharynx and muscle fasciae, in addition to distension of the facial planes of the neck ². Therefore, airway management should be the first step in the treatment of patients with Ludwig's Angina, since airway involvement is the main cause of death ⁷.

Oro or nasotracheal intubation may not be possible due to the anatomical involvement of the infection, the risk of trauma to the airways, the rupture of pus in the oral cavity with bronchopulmonary aspiration, the potential risk of inducing severe laryngospasm and the presence of trismus and edema of the tongue⁸. In these cases, airway management must be done through tracheostomy⁹.

Although glucocorticoids mask the manifestations of infections, the literature shows that the benefits related to better airway patency outweigh possible harm¹⁰.

Empirical antibiotic therapy should be instituted immediately. The drugs most used in the initial approach are Penicillin, Metronidazole and Clindamycin¹. Severely immunosuppressed patients should receive additional coverage against methicillin-resistant *Staphylococcus aureus* and gram-negative¹¹. The association of intravenous antibiotic therapy with surgical intervention is related to the lower incidence of progression to airway involvement when compared to the isolated use of venous antibiotics¹².

Surgery is considered a fundamental part of the treatment of cases that are not responsive to conservative behaviors and of cases that are initially complicated. The objective is to debride the infected areas, excise the necrotic tissues and drain purulent collections and, consequently, decompress the submental, submandibular and sublingual spaces³. In addition, surgical intervention allows the collection of samples for Gram staining and cultures, as well as the placement of a drain to collect pus¹².

Anesthetic management must be adapted considering the possible complications associated with the condition⁹. For a slow anesthetic induction with inhalation agents before intubation, Sevoflurane is a good option, as it allows rapid control of anesthetic plans and cardiovascular stability, in addition to not interrupting spontaneous breathing. Benzodiazepine sedation is useful for maintaining patient comfort and providing some level of amnesia. However, patients with significant airway involvement may progress to acute airway obstruction as a result of the action of these sedatives¹³.

Postoperative care must be intense, most of the time requiring assistance in intensive care unit. In cases of extensive preoperative airway edema or in those where hardening and tissue edema is identified instead of a large purulent collection, extubation should be delayed. In these situations, the possibility of performing a tracheostomy must be analyzed¹³.

Mortality related to Ludwig's Angina has reduced dramatically with the advance of antibiotic therapy and surgical techniques². Currently, the mortality rate is described in up to 8% of cases, however, the presence of mediastinitis as a complication increases mortality to up to 50% of cases⁴. In addition, the traumatic etiology is considered a major factor that aggravates the prognosis¹⁴.

The etiology of Ludwig's Angina of the studied patient does not fit within 90% of the cases related to odontogenic infection, but it had a known infectious focus. In addition, it is important to note that the patient had factors aggravating his general condition (drug addiction and alcoholism), which may have contributed to mediastinal involvement and the need for prolonged intensive support, since the immune system and body reserves necessary for a good recovery are impaired.

The early start of empirical antibiotic therapy associated with the surgical approach was essential for the patient's

satisfactory evolution. Furthermore, airway protection was important to prevent the onset of acute respiratory failure, which would have had a negative impact on the patient's prognosis.

The complications that arose during the course - renal dysfunction and lower limb ischemia - needed to be treated together with specialized teams, given that the patient's general condition could not be affected by other factors that could negatively influence the patient's outcome.

The good evolution of this case is an exception to the rule, since the presence of mediastinitis as a complication of Ludwig's Angina raises the mortality rate considerably.

CONCLUSION

Ludwig's Angina is a potentially fatal infection of the cervical spaces. The conduct of choice recommends the early start of empirical antibiotics and the maintenance of patent and protected airways. Surgical intervention is preferable to conservative management, because, in addition to allowing the removal of devitalized tissues that can contribute to the spread of the infection, it allows the collection of samples to direct antibiotic therapy. Finally, it is recommended that all odontogenic infections and other infectious foci of the cervical region be thoroughly monitored and monitored, in order to avoid the evolution to Ludwig's Angina and its complications.

REFERENCES

1. Pak S, Cha D, Meyer C, Dee C, Fershko A. Ludwig's Angina Case Presentation. *Cureus*. 2017;9(8):8–11.
2. Parker E, Mortimore G. Ludwig's angina: A multidisciplinary concern. *Br J Nurs*. 2019;28(9):547–51.
3. Vallée M, Gaborit B, Meyer J, Malard O, Boutoille D, Raffi F, et al. Ludwig's angina: A diagnostic and surgical priority. *Int J Infect Dis*. 2020;93:160–2.
4. Miller CR, Von Crowns K, Willoughby V. Fatal Ludwig's Angina: Cases of Lethal Spread of Odontogenic Infection. *Acad Forensic Pathol*. 2018;8(1):150–69.
5. Mohamad I, Narayanan MS. "Double tongue" appearance in Ludwig's angina. *N Engl J Med*. 2019;381(2):163.
6. Li RM, Kiemeny M. Infections of the Neck. *Emerg Med Clin North Am* [Internet]. 2019;37(1):95–107. Available from: <https://doi.org/10.1016/j.emc.2018.09.003>
7. Eskander A, De Almeida JR, Irish JC. Acute Upper Airway Obstruction. *N Engl J Med*. 2019;381(20):1940–9.
8. Kangabam SD, Heisnam I. Ludwig's Angina and Anaesthetic Difficulties: a Case Report. *J Evol Med Dent Sci*. 2015;4(28):4916–9.
9. Fellini RT, Volquind D, Schnor OH, Angeletti MG, Souza OE de. Airway management in Ludwig's angina – a challenge: case report. *Brazilian J Anesthesiol (English Ed)* [Internet]. 2017;67(6):637–40. Available from: <http://dx.doi.org/10.1016/j.bjane.2014.10.010>
10. Tami A, Othman S, Sudhakar A, McKinnon BJ. Ludwig's angina and steroid use: A narrative review. *Am J Otolaryngol - Head Neck Med Surg*. 2020;(January):102411.

11. Fiaschi-taesch NM, Bs JWK, Bs FS, Bs T, Bs RW, Tanwir M, et al. Page 1 of 41 Diabetes. 2013;1–41.
12. Edetanlen BE, Saheeb BD. Comparison of Outcomes in Conservative versus Surgical Treatments for Ludwig's Angina. Med Princ Pract. 2018;27(4):362–6.
13. Dowdy RAE, Emam HA, Cornelius BW. Ludwig's angina: Anesthetic management. Anesth Prog. 2019;66(2):103–10.
14. Juncar M, Juncar RI, Onisor-Gligor F. Ludwig's angina, a rare complication of mandibular fractures. J Int Med Res. 2019;47(5):2280–7.