



Letter to the Editor

Transfusion related acute lung injury: a rare case after single Packed Red Blood Cell unit transfusion

To the Editor

We here present a rare case of Transfusion related acute lung injury (TRALI) requiring Intensive Care Unit (ICU) support after transfusion of single Packed Red Blood Cell (PRBC) unit.

TRALI is an uncommon complication of allogeneic blood transfusion, manifested typically by shortness of breath, a non-productive cough, fever, and hypotension, firstly recognized as a clinical entity in 1983 by Popovsky et al., with an estimation of antibody-mediated TRALI, occurring at a rate of 1 in 5000 transfused units and non-immune TRALI, at a rate of 1 in 1120 cellular blood components, with one incidence per 453 transfused platelet concentrates and one incidence per 4410 transfused PRBCs.^{1,2}

Present case was a 68-year-old female, with newly diagnosed Acute Myeloid leukemia with COVID-19 positive and right thigh non-healing Ulcer, having low hemoglobin (7.6 g/dl) and low platelet counts (8,000/ μ l), B positive blood group, admitted for PRBC and platelet transfusions. Patient was stable prior to transfusion however; she developed difficulty in breathing, low-grade fever, chills and cyanosis within 2 h after one unit of PRBC transfusion. A transfusion reaction was suspected and differential diagnosis of TRALI, transfusion associated circulatory overload (TACO), septic or acute hemolytic transfusion reaction was made. Patient was severely hypoxic with a SPO₂ of 68% at room air and 94% with 4 liter O₂.

Chest X-ray showed extensive bilateral pulmonary infiltrates suggestive of acute pulmonary micro vascular insult leading to interstitial and alveolar infiltrates. The chest X-ray of the patient before and after transfusion is shown in Figure 1a and b. The central venous pressure (CVP) and pulmonary capillary wedge pressure were found to be normal (4mmHg and 6mmHg respectively), thereby excluding the possibility of TACO.

The patient was managed by Inj.Avil, hydrocortisone, furosemide and O₂ support, but her symptoms did not improve. Hence she was shifted to ICU and required non-invasive

ventilator support. On evaluation she had pancytopenia and raised procalcitonin (18.70 ng/ml). Chest X ray showed bilateral opacities. The bacterial cultures from the patient and PRBC unit were negative. She responded well to the treatment, patient's pulmonary edema gradually improved and became asymptomatic in 72 h with normal Chest X ray and SPO₂ 94% at room air.

The possibility of acute hemolytic transfusion reaction was ruled out as patient and RBC unit transfused were ABO group identical, crossmatch compatible and a irregular red cell antibody screen on the patient sample and donor unit were negative. Anti-HLA and anti-granulocyte antibodies could not be done due to affordability issues of the patient and non-compliance of the donor to recall request for further laboratory workup. However, on reviewing donor card data it was found that it was young male blood donor (20 years of age) without any history of exposure in the past leading to alloimmunization. However, the possibility of presence of recipient specific antibodies in donor plasma cannot be ruled out.

In a prospective study by Sillman et al., anti HLA and/or anti granulocyte antibodies were found in the donor plasma in only 25% cases and 3.6% cases with definable specificity. Further, in at least 10-15% typical cases of TRALI, antibodies were not detected in either the recipient or in the donor. Patients with haematologic malignancies and those requiring coronary bypass surgery are at increased risk.²

In the present case, TRALI was suspected because of the rapid onset and significant degree of hypoxemia (pO₂ of 65 mm of Hg) and characteristic extensive bilateral pulmonary infiltrates post-transfusion on chest X-ray and non-cardiac pulmonary edema after the RBC transfusion. Also patient does not have any pre-existing Acute Lung Injury (ALI) or any associated risk factor for ALI.

To prevent antibody-mediated TRALI, it is recommended that transfusions containing anti-leukocyte antibodies should be avoided, e.g., fresh frozen plasma derived only from male donors should be used because of the high

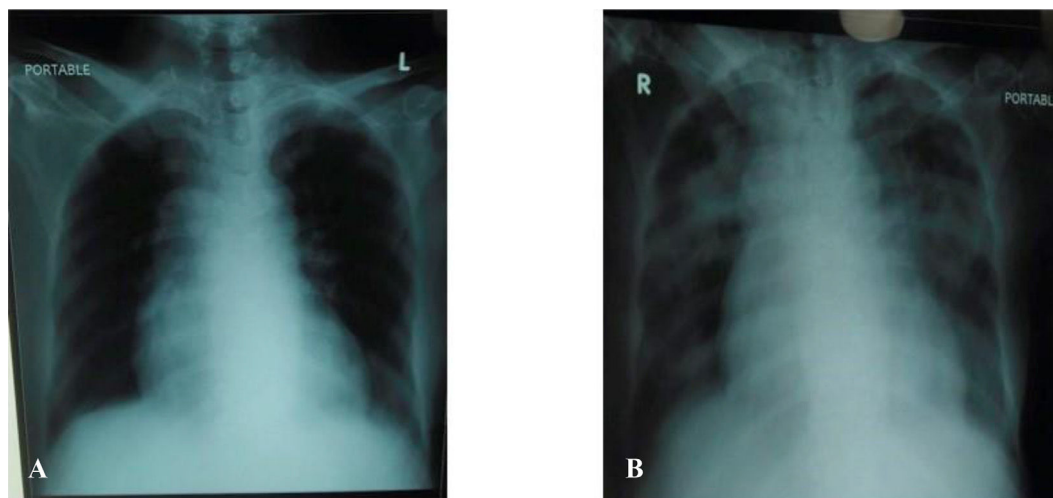


Figure 1 – (A), Chest X-ray before transfusion. (B), Chest X-ray after transfusion.

anti-leukocyte antibody positivity rate of females with a history of pregnancy, and donors that have previously been associated with TRALI should also be excluded.^{3,4}

As well as antibodies, plasma proteins and biological response modifiers are also associated with the onset of TRALI. These are contained in plasma; therefore, it has been reported that washed platelet preparations, from which as much plasma as possible is removed, are effective for preventing TRALI.⁵

Therefore, the present case highlights the fact that TRALI should be kept as a differential diagnosis in all patients developing acute respiratory discomfort within 6 h of transfusion and managed accordingly. Notification of transfusion services is crucial to ensure that a proper investigation is carried out and at-risk donor and recipients can be identified, and risk reduction measures can be adopted.

Conflicts of interest

The author declares no conflicts of interest.

REFERENCES

1. Popovsky MA, Moore SB. Diagnostic and pathogenetic considerations in transfusion-related acute lung injury. *Transfusion*. 1985;25:573–7.
2. Silliman CC, Boshkov LK, Mehdizadehkashi Z, Elzi DJ, Dickey WO, Podlosky L, et al. Transfusion-related acute lung injury: epidemiology and a prospective analysis of etiologic factors. *Blood*. 2003;101:454–62.
3. Strong DM, Lipton KS. Transfusion Related Acute Lung Injury. *Association Bulletin 2006-07*. Bethesda, MD: American Association of Blood Banks; November 2006.
4. Eder AF, Herron Jr RM, Strupp A, Dy B, White J, Notari EP, et al. Effective reduction of transfusion-related acute lung injury risk with male-predominant plasma strategy in the American Red Cross (2006-2008). *Transfusion*. 2010;50(8):1732–42.
5. Hirayama F. Current understanding of allergic transfusion reactions: incidence, pathogenesis, laboratory tests, prevention and treatment. *Br J Haematol*. 2013;160(4):434–44.

Bala Bhasker 

Department of Transfusion Medicine, Sparsh Hospital,
Yeshwantpur, Bangalore, India
E-mail address: balag4g@gmail.com

Received 29 January 2021

Accepted 13 July 2021

Available online 22 November 2021

<https://doi.org/10.1016/j.htct.2021.07.012>
2531-1379/

© 2022 Associação Brasileira de Hematologia, Hemoterapia e Terapia Celular. Published by Elsevier España, S.L.U. This is an open access article under the CC BY-NC-ND license (<http://creativecommons.org/licenses/by-nc-nd/4.0/>).