

Morphological alterations in endometrium after use of levonorgestrel-releasing intrauterine system: a case report

Alterações morfológicas no endométrio após uso de dispositivo intrauterino com liberação de levonorgestrel: relato de caso

Francisco das Chagas Medeiros¹ , Matheus Duarte Pimentel² , Rodrigo Dias Custódio² , Dalgimar Beserra de Menezes³ 

1. Adjunct Professor, Department of Maternal-Child Health, Faculdade de Medicina, Universidade Federal do Ceará (UFC), Fortaleza, CE, Brazil. 2. Medical Doctor, Faculdade de Medicina, Universidade Federal do Ceará (UFC), Fortaleza, CE, Brazil. 3. Emeritus Professor, Pathology Department, Faculdade de Medicina, Universidade Federal do Ceará (UFC), Fortaleza, CE, Brazil

Abstract

Case Report: A 44-year-old patient attended the gynecology service for routine consultation. The patient reported implantation of a levonorgestrel-releasing intrauterine system (LNG-IUS), five years ago. No macroscopic changes were seen in the uterus or in the endometrium cavity during the procedure, but an endometrial biopsy was performed. Histopathological analysis revealed an endometrium with an expanded stroma by pseudo-decidualization and mucoid (mucinous) alterations, forming small puddles of mucin, also presenting with polypoid indentations, ectatic vessels, lymphoid cell foci, including plasma cells and deposits of calcium salts. Conclusion: As the use of this type of contraceptive method becomes more usual, knowledge of LNG-IUS-induced changes becomes increasingly relevant for the assessment of its long-term efficacy and safety.

Key-Words: Endometrium. Morphology. Levonorgestrel.

Resumo

Relato de Caso: Paciente de 44 anos compareceu ao serviço de ginecologia para consulta de rotina. Relatou implante de dispositivo intrauterino com liberação de levonorgestrel (DIU-LNG) há cinco anos. Durante o exame físico, o fio do dispositivo não foi visualizado. À histeroscopia, para remoção do dispositivo, não foram evidenciadas alterações na cavidade endometrial. Material foi, então, colhido para biópsia. O estudo histopatológico evidenciou um endométrio com estroma expandido por pseudodecidualização e alterações mucoides, formando pequenos aglomerados de mucina, também se apresentando com endentações polipoides, vasos ectásicos, focos de células linfoides e depósitos de sais de cálcio. A presença de DIU-LNG na cavidade uterina causa uma série de alterações histopatológicas e funcionais no endométrio, as quais não são relacionadas, exclusivamente, ao efeito contraceptivo do dispositivo. Conclusão: Com o aumento da utilização desse método anticoncepcional, o conhecimento das alterações provocadas pelo seu uso se torna cada vez mais relevante para avaliação de sua eficácia e segurança em longo prazo.

Palavras-chave: Endométrio. Morfologia. Levonorgestrel

BACKGROUND

The intrauterine device (IUD) is one of the most commonly used reversible contraceptive methods, mainly due to its long duration of action, high efficacy for pregnancy prevention, and the relatively unusual side effects, alongside with lower complication rates related to its use¹⁻⁵. Copper IUD and LNG-IUS are the most typically inserted IUDs, the latter being currently the most studied once it has similar or even superior efficacy to copper IUD, with less association with side effects, such as ectopic pregnancies, pelvic inflammatory disease (PID) and menorrhagia^{4,5}.

Mirena® is the type of LNG-IUS approved and most widely available for clinical use. It is a T-shaped device containing a cylinder of the synthetic progestogen levonorgestrel, a substance released into the uterine cavity at a controlled

rate of 20 µg per day, in such a way that circulating progestin concentrations are lower than those seen during the use of oral or parenteral contraceptive therapy, maintaining serum levels between 150 and 200 pg / mL, what reduces side effects and secures the efficacy of the method¹⁻⁵.

In addition to contraceptive use, the literature shows that LNG-IUS is used in other clinical situations, such as control of severe menorrhagia, reduction of primary dysmenorrhea and in the cases in which it is associated to endometriosis, PID and adenomyosis. Treatment of benign endometrial hyperplasia, protection of the malignant endometrial transformation associated with estrogen hormone replacement therapy in patients in the perimenopausal or postmenopausal period, and preservation of endometrium against the effects of the use of

Correspondence: Matheus Duarte Pimentel. Address: Suíça st., 120. A9, 302. Fortaleza, Ceará. Zip-Code: 60711-035. Phone: +55 85 986464115. E-mail: pimentelmd@outlook.com

Conflict of interest: The authors declare no conflict of interest.

Received: 2018 Oct 19; Revised: 2019 Nov 6; 2019 Dec 10; Accepted: 2019 Dec 13

2 Alterations in endometrium after use of levonorgestrel-releasing IUS

tamoxifen are other described uses for this device^{1,3,4,5}.

Despite the clinical applications and benefits previously reported, it is important to note that some studies have shown that, in addition to the endometrial alterations usually associated with LNG-IUS, diverse morphological findings can be found, which are not commonly described in the literature^{4,6,7,8}.

The objective of this report is to describe the case of a patient, in use of a LNG-IUS, in whom, during the procedure for replacement of this device, an endometrial biopsy was performed, and further histopathological analysis revealed unusual morphological alterations in the collected tissue.

CASE REPORT

A 44-year-old patient, pregnant 2, para 2 sought medical assistance in the Department of Gynecology for routine consultation. She had no complaints and did not report any comorbidities or any other relevant data in her medical history. During anamnesis patient reported use of a levonorgestrel-releasing intrauterine system (LNG-IUS), with the device within 5 years of implantation. During physical examination the device's wire was not visualized. The patient was then submitted to hysteroscopy for removal of LNG-IUS. No macroscopic changes were seen in the uterus nor in the endometrium cavity during the procedure, nevertheless an endometrial biopsy was performed.

Figure 1. Pathology findings: (A) Pseudodecidualized endometrium. Presence of cystic glandules with flattened and cuboid coating (H & E, x100). (B) Pseudodecidualized endometrium with ectatic vessels and large area of calcium salts deposits (H & E, x100). (C) Pseudodecidualized endometrium with infiltrate of leukocyte and plasmocytes (H & E, x400). (D) Pseudodecidualized endometrium with fibrinoid deposits and mucous lakes (H & E, x100).

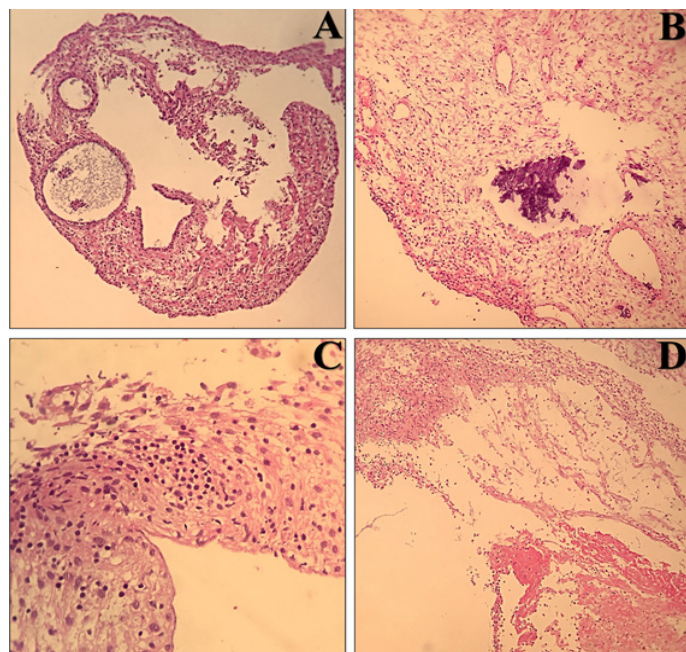
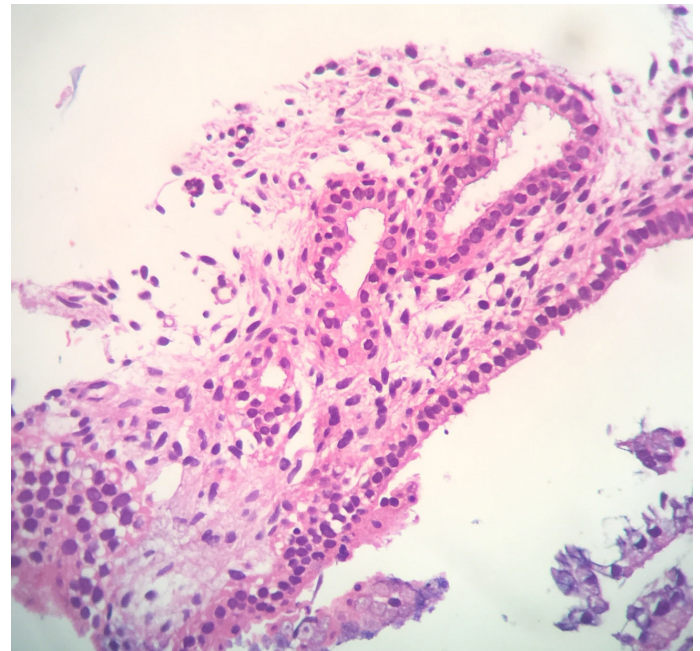


Figure 2. Pathology findings: Oxyphilic Metaplasia (H & E, x400).



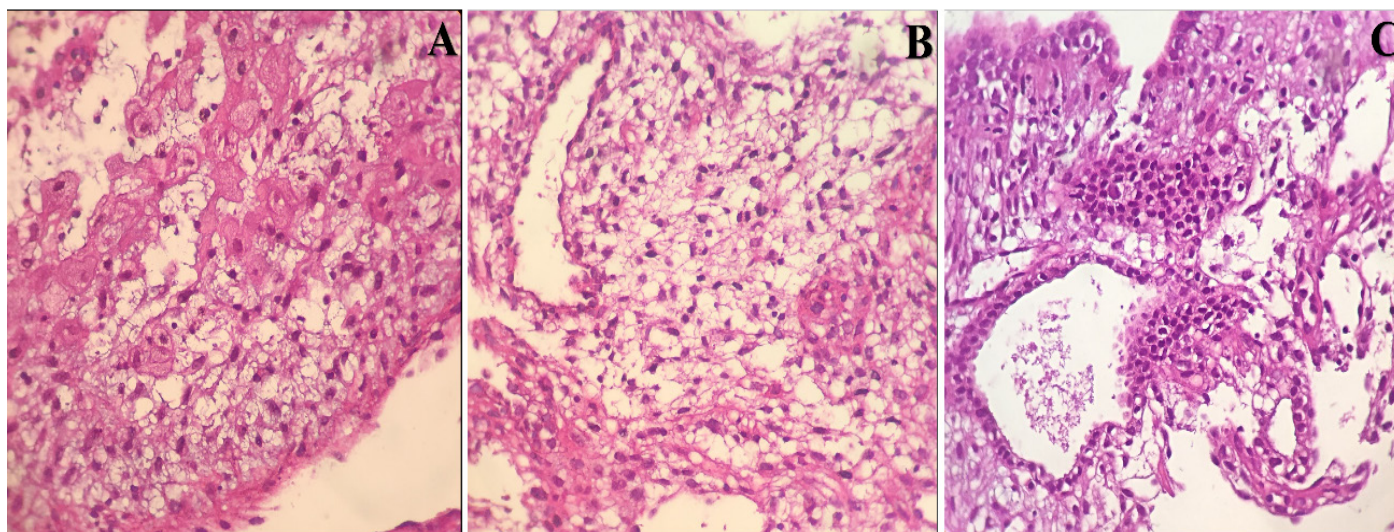
Histopathological analysis revealed an endometrium with an expanded stroma by pseudo-decidualization and mucoid (mucinous) alterations forming small puddles of mucin, also presenting with polypoid indentations, ectatic vessels, lymphoid cell foci, including plasma cells (endometritis, H & E) and deposits of calcium salts. Also, fibrinoid or hyaline deposits were observed, along with reminiscent of Nitabuch's membrane, with rare multinucleated cells. Atrophic glands with flattened epithelium, somewhat cystised, were presented, coated with cuboid cells presenting eosinophilic (oxyphilic) metaplasia.

DISCUSSION

The release of levonorgestrel in the uterine cavity results in direct alterations of the endometrium, such as decidualization of the stroma and glandular atrophy, caused by hormonal action, as well as inflammatory alterations caused by the presence of the device itself in this site. These changes were linked with suppression of endometrial proliferation, along with the thickening of the cervical mucus and reduction of sperm motility, which would lead to the formation of a uterine environment hostile to fertilization and embryo implantation³⁻¹⁰.

Guet et al., in a study with 34 women aged 25-37 years, with no history or suspicion of malignancy, recurrent chronic disease or pelvic inflammatory disease, demonstrated that one year after the start of the use of LNG-IUS, the endometrium of the patients became atrophic and thin, with cubic epithelial cells, and inflammatory stromal reaction with infiltration of polymorphonuclear leukocytes, lymphocytes, macrophages and plasmatic cells, and a decreased number of glands, findings that are similar to those observed in the described case⁶.

Figure 3. Pathology findings: (A) Pseudo-decidua with myxoid degeneration (H & E, x400). (B) Pseudo-decidua with myxoid degeneration. Ectatic Vessels (H & E, x400). (C) Pseudodecidualized endometrium with myxoid degeneration. Glandule with flattened epithelium



Critchley and colleagues, concluded that the use of LNG-IUS, after 12 months of insertion, was associated with a process of glandular atrophy and extensive decidual transformation of the uterine stroma, in a phenomenon known as decidualization, which correlates characteristics such as increase in granulocyte and macrophage colony stimulating factor, immunoreactivity in decidualized stromal cells, expression of marked glandular and stroma prolactin receptors, as well as infiltration of CD56 + granulocyte lymphocytes and CD68 + macrophage⁹.

Analysing the physiopathological aspects of morphological alterations in the endometrium after LNG-IUS insertion, recent studies show that exposure to the levonorgestrel concentrations released by this kind of device would result in increased expression of tissue factor (TF), interleukin-8 (IL-8), interleukin-13 (IL-13) and interleukin-15 (IL-15), cyclooxygenase-2 and matrix metalloproteinases (MMPs). These markers could facilitate leukocyte infiltration, especially of natural killer cells specific for uterine endometrium, and

epithelial degradation, with posterior formation of foci of necrosis and calcification^{4,6,7-12}. There would also be increased expression of vascular endothelial growth factor (VEGF), which would act as to increase vascular permeability, promoting aberrant angiogenesis and resulting in haemorrhages, microthromboses and ulceration of the epithelium^{4,7,10,12}.

It should be noted that these changes are predominantly dependent of dose and time of exposure to LNG-IUS, with reports of reestablishment of the usual endometrial morphology and function after discontinuation of levonorgestrel exposure^{4,7-10}.

In conclusion, the presence of LNG-IUS in the uterine cavity causes a series of histopathological and functional changes in the endometrium, which are not related only to the contraceptive effect of this device. As the use of this type of contraceptive method becomes more usual, knowledge of LNG-IUS-induced changes becomes increasingly relevant for the assessment of its long-term efficacy and safety.

REFERENCES

1. Bahamondes L. [Contraceptive method choice] *Rev. Bras. Ginecol. Obstet.* 2006 May; 28(5): 267-270. doi: <http://dx.doi.org/10.1590/S0100-72032006000500001>.
2. Donadio N, Donadio NF, Dotore A, Silva FF, Ribeiro PAAG, Aoki T. Application of a levonorgestrel-releasing intrauterine device prior to in vitro fertilization cycles in women with adenomyosis. *Rev. Bras. Ginecol. Obstet.* 2006; 28(8): 473-478. doi: <http://dx.doi.org/10.1590/S0100-72032006000800006>.
3. Ortiz ME, Croxatto HB. Copper-T intrauterine device and levonorgestrel intrauterine system: biological bases of their mechanism of action. *Contraception.* 2007 Jun; 75(6): S16-S30. doi: 10.1016/j.contraception.2007.01.020.
4. Phillips V, Graham CT, Manek S, McCluggage WG. The effects of the levonorgestrel intrauterine system (Mirena coil) on endometrial morphology. *J Clin Pathol.* 2003 Apr; 56(4): 305-307. doi: 10.1136/jcp.56.4.305.
5. Varma R, Sinha D, Gupta JK. Non-contraceptive uses of levonorgestrel-releasing hormone system (LNG-IUS)—a systematic enquiry and overview. *J. Health Biol Sci.* 2020; 8(1):1-4.
6. Gu Z, Zhu P, Luo H, Zhu X, Zhang G, Wu S. A morphometric study on the endometrial activity of women before and after one year with LNG-IUD in situ. *Contraception.* 1995 Jul; 52(1): 57-61. doi: 10.1016/0010-7824(95)00125-t.
7. Guttinger A, Critchley HO. Endometrial effects of intrauterine levonorgestrel. *Contraception.* 2007 Jun; 75(6 Suppl): S93-S98. doi: 10.1016/j.contraception.2007.01.015.
8. Hejmadi RK, Chaudhri S, Ganesan R, Rollason TP. Morphologic changes in the endometrium associated with the use of the mirena coil: a retrospective study of 106 cases. *Int J Surg Pathol.* 2007 Apr; 15(2): 148-154. doi: 10.1177/1066896906299120.
9. Critchley HO, Wang H, Jones RL, Kelly RW, Drudy TA, Gebbie AE et al. Morphological and functional features of endometrial decidualization following long-term intrauterine levonorgestrel delivery. *Hum Reprod.* 1998 May; 13(5):

1218-1224. doi: 10.1093/humrep/13.5.1218.

10. Jones RL, Critchley HO. Morphological and functional changes in human endometrium following intrauterine levonorgestrel delivery. *Hum Reprod* 2000 Aug;15(Suppl 3): 162-172. doi: 10.1093/humrep/15.suppl_3.162.

11. Charlton F, Otton G, Hedges A, Scurry J. Endometrial granulomas with levonorgestrel intrauterine system (Mirena). *Pathology*. 2014 Aug; 46(5): 457-458. doi: 10.1097/PAT.0000000000000127.

12. Selim, MF, Hussein AF. Endothelial function in women using levonorgestrel-releasing intrauterine system (LNG-IUS). *Contraception*. 2013 Apr; 87(4): 396-403. doi: 10.1016/j.contraception.2012.12.008.

13. Nicolae A, Preda O, Nogales FF. Endometrial metaplasias and reactive changes: a spectrum of altered differentiation. *J ClinPathol*. 2010 Feb; 64(2): 97-106. doi: 10.1136/jcp.2010.085555.

How to cite this article/Como citar este artigo:

Medeiros FC, Pimentel MD, Custódio RD, Menezes DB. Morphological alterations in endometrium after use of levonorgestrel-releasing intrauterine system: a case report. *J Health Biol Sci*. 2020; 8(1):1-4.