


# The Role of Neurophysiological Monitoring during Complex Aneurysm Surgery: Report of Two Cases and Review of the Literature

## *O papel do monitoramento neurofisiológico durante cirurgia de aneurisma complexo: relato de dois casos e revisão da literatura*

Roger Schmidt Brock<sup>1,2,3</sup> Marcos Queiroz Teles Gomes<sup>1,2,3</sup> Félix Hendrik Pahl<sup>1,2,3</sup>

José Erasmo Dal Col Lúcio<sup>1,2,3</sup> José Francisco Pereira Júnior<sup>1,2,3</sup>

Clarissa Gambarra Nóbrega Nascimento<sup>1,2,3</sup> Henrique Oliveira Martins<sup>3</sup> Matheus Fernandes Oliveira<sup>1,2,3</sup> 

<sup>1</sup>Department of Neurosurgery, DFV Neuro, São Paulo, SP, Brazil

<sup>2</sup>Hospital Sírio-Libanês, São Paulo, SP, Brazil

<sup>3</sup>Hospital Alemão Oswaldo Cruz, São Paulo, SP, Brazil

Address for correspondence: Matheus Fernandes de Oliveira, PhD, Avenida Loeffgren 700, apto. 103, Vila Mariana, São Paulo, São Paulo, 04040-000, Brazil (e-mail: mafernoliv@yahoo.com.br).

Arq Bras Neurocir 2019;38:348–353.

### Abstract

#### Keywords

- ▶ intracranial aneurysm
- ▶ surgery
- ▶ neurophysiological monitoring
- ▶ intraoperative angiography

The surgical treatment of intracranial aneurysms is a routine operation in the neurosurgeon practice. Complex aneurysms are those with morphological irregularities, usually large or giant; thrombosed, partially thrombosed or calcified; with aberrant fundus/neck ratio and near eloquent neurological structures. These cases demand special skills by the surgical team. The present article is a report of two cases of complex aneurysms successfully treated, with a discussion on the role of neurophysiological monitoring. In these two cases of supra- and infratentorial complex giant aneurysms, intraoperative monitoring was extremely relevant. Thus, we believe that treating complex and giant aneurysms carries several pitfalls, and the use of multimodal intraoperative monitoring is mandatory to mitigate risks and deliver the best result to the patient.

### Resumo

#### Palavras-chave

- ▶ aneurisma intracraniano
- ▶ cirurgia
- ▶ monitorização neurofisiológica
- ▶ angiografia intraoperatória

O tratamento cirúrgico de aneurismas intracranianos é uma cirurgia de rotina na prática neurocirúrgica. Aneurismas complexos são caracterizados por terem irregularidades morfológicas; serem grandes ou gigantes; parcialmente trombosados ou calcificados; com uma razão fundo/colo desfavorável ou aqueles próximos a estruturas neurológicas eloquentes.

Esses casos demandam habilidades específicas do time cirúrgico. Este estudo relata dois casos de tratamento bem sucedido de aneurismas complexos, discutindo o uso da monitorização neurofisiológica intraoperatória. Em ambos casos, sendo um supratentorial e outro infratentorial, o uso de monitorização neurofisiológica intraoperatória foi essencial para avaliar a qualidade da clipagem dos aneurismas e eventualmente reposicionamento dos cliques para evitar déficits neurológicos.

Dessa forma, devido ao alto risco potencial de tratamento cirúrgico de aneurismas complexos, acreditamos que a monitorização intraoperatória neurofisiológica multimodal se faz mandatória para mitigar os riscos e alcançar o melhor resultado cirúrgico e funcional.

received  
June 30, 2019  
accepted  
August 21, 2019

DOI <https://doi.org/10.1055/s-0039-1698787>.  
ISSN 0103-5355.

Copyright © 2019 by Thieme Revinter Publicações Ltda, Rio de Janeiro, Brazil

License terms



## Introduction

The surgical treatment of intracranial aneurysms is a routine operation in the neurosurgeon practice. They may be unruptured or ruptured, and surgical clipping enables mass effect control and the avoidance of further bleeding or rebleeding. The majority of intracranial aneurysms is located near the skull base, and are related to branching sites of large vessels of the anterior or posterior circulation. Morphologically, aneurysms may be small, large or giant, and saccular or fusiform. They may also be classified according to the fundus/neck ratio and their content (thrombosed, partially thrombosed or calcified).<sup>1–15</sup>

Complex aneurysms are those with morphological irregularities, usually large or giant; thrombosed, partially thrombosed or calcified; with aberrant fundus/neck ratio, and near eloquent neurological structures. These cases demand special skills by the surgical team. A preoperative complete investigation associated with the correct intraoperative planning is essential for maximum success. Currently, these cases need special technology application, including navigation, neurophysiological monitoring, and intraoperative real-time angiographic evaluations by immunofluorescence.<sup>10–18</sup>

In the present report, we describe two cases of complex aneurysms successfully treated, and discuss the role of neurophysiological monitoring. In these two cases of supra- and infratentorial complex giant aneurysms, intraoperative

monitoring was extremely relevant because the aneurysms were closely related to eloquent brain structures such as: the medulla, the cerebellum, the lower cranial nerves (IX, X, XI, XII), the posterior inferior cerebellar artery (PICA), the vertebral artery, the internal carotid artery, and the perforating arteries of these vessels.

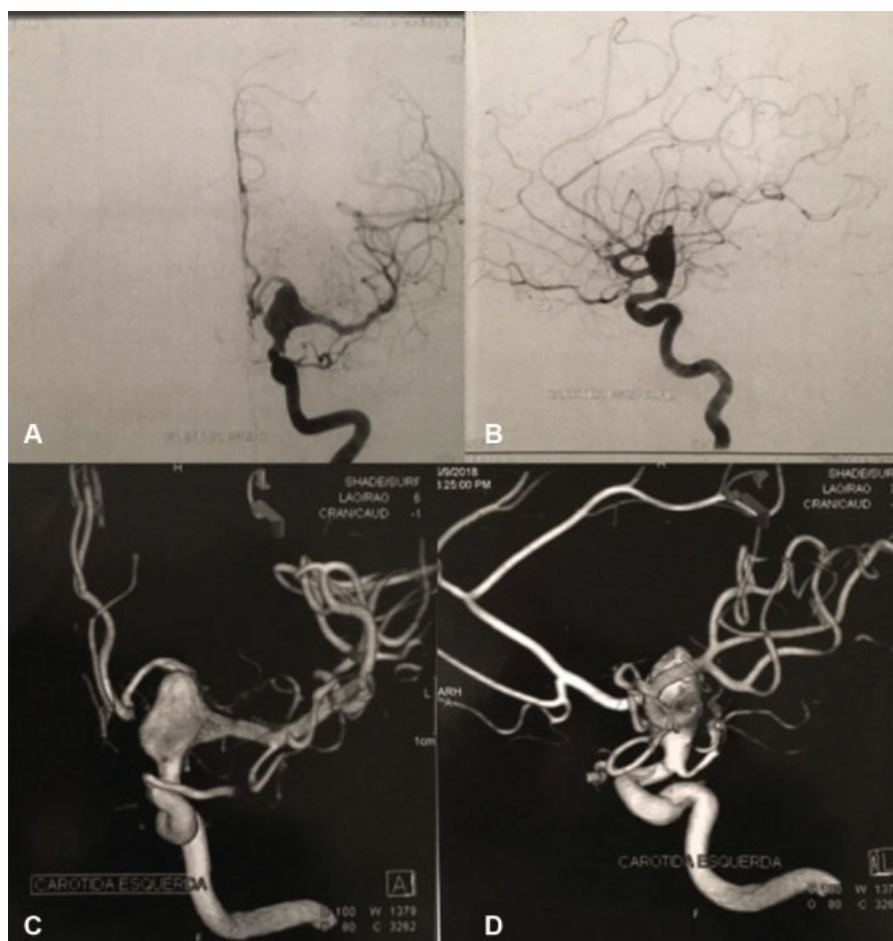
## Case Descriptions

### Case 1

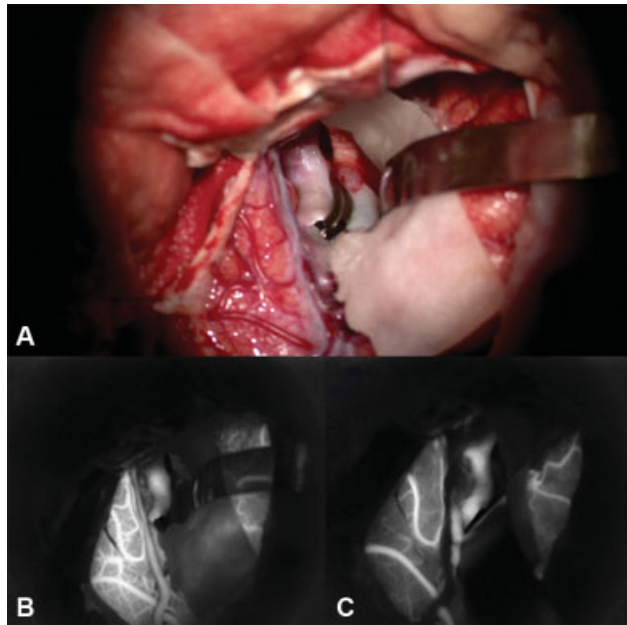
The first case was of a 36-year-old male patient with a history of left holocranial pulsatile headache with irradiation to the cervical region. It was persistent, relieving with usual analgesic use. There were no other complaints and/or neurological deficits. The neurological examination was normal. His previous medical history was unremarkable.

The patient was submitted to cerebral angiography, which disclosed a fusiform lesion of the left internal carotid artery (ICA), reaching the bifurcation of the ICA, the M1 segment of the middle cerebral artery (MCA), and segment A1 of the anterior cerebral artery (ACA). There was no subarachnoid hemorrhage (SAH) associated (►Fig. 1).

The patient underwent microsurgical clipping of the aneurysm and vessel reconstruction by a pterional approach with adjunct use of neurophysiological monitoring (►Fig. 2). Additionally, we used indocyanine green to address the




**Fig. 1** Complex and fusiform internal carotid artery (ICA) bifurcation aneurysm reaching the proximal M1 and A1 segments.



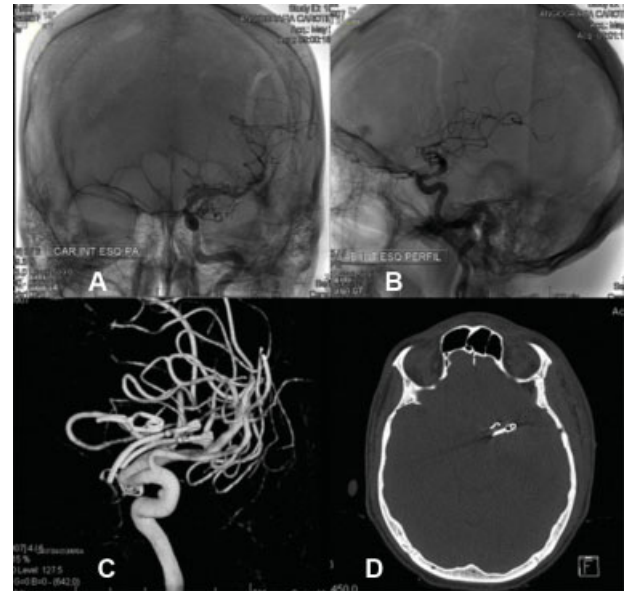
**Fig. 2** Aneurysmal clipping and vessel reconstruction. Intraoperative angiography with indocyanine green (ICG) revealing good blood flow.

intraoperative flowmetry after clipping. Multimodal neurophysiological monitoring was performed from the beginning to the end of the procedure, with the following techniques (►Fig. 3):

- Somatosensory-evoked potentials (SEPs) by stimuli in the upper and lower limbs.
- Motor-evoked potentials (MEPs) by transcranial electrical stimuli, with registration in muscles of the upper and lower limbs.
- Electroencephalogram (EEG) with ten channels for depth assessment anesthesia and train-of-four (TOF) to evaluate neuromuscular blockade.



**Fig. 3** Intraoperative neurophysiological monitoring revealing no disturbances during clipping.



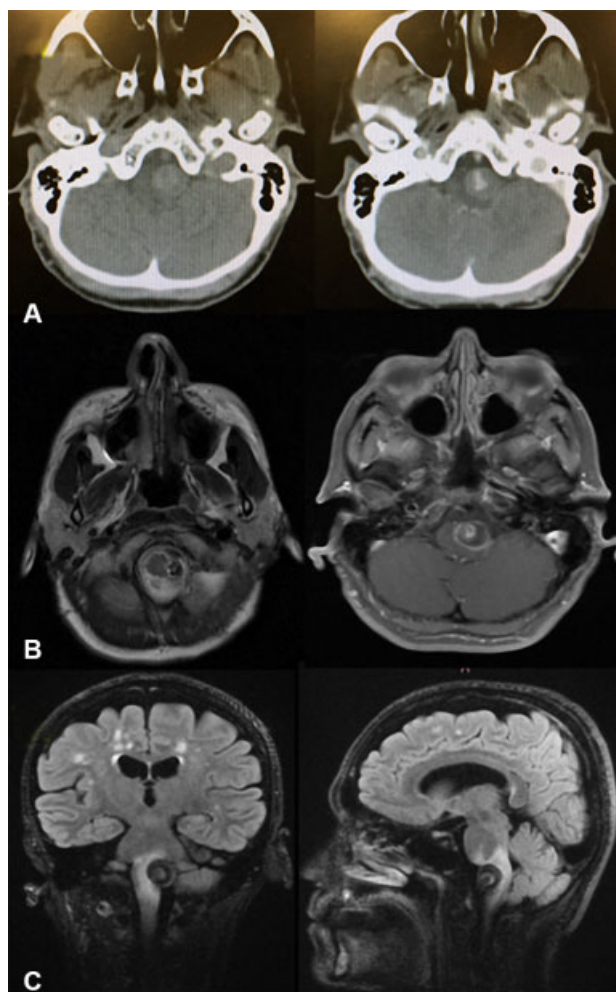
**Fig. 4** Postoperative images disclosing total aneurysmal exclusion and preservation of blood flow.

The reconstruction was accomplished by clipping the proximal ACA and reconstructing bifurcation walls with clips.<sup>3</sup> During surgery, neurophysiological monitoring was unremarkable, and the postoperative neuroimage and clinical picture were adequate (►Fig. 4). The patient was discharged in the fifth postoperative day, without neurological impairment.

## Case 2

A 54-year-old female patient presented with a history of dizziness and nausea for weeks, which was associated with moderate to severe pulsatile persistent holocranial headache relieved by analgesics. After a few days, the patient evolved





**Fig. 5** Large, complex and partially thrombosed aneurysm near the medulla. Inside the aneurysm there were also different phases of intramural bleeding.

with left hemiparesis (grade IV), with gait disturbances and falling, as well as alteration of the lower cranial nerves (X, XII) on the left (dysphagia, dysphonia).

She underwent cranial tomography and magnetic resonance, which revealed an extra-axial nodular lesion on the left side of the medulla measuring 2 cm in diameter, heterogeneous, hypodense in the periphery and hyperdense in the center, closely related to the left vertebral artery, and deforming the medulla. The hypothesis of a vascular lesion was raised, and she underwent a vascular study (► Fig. 5).

The images of the cerebral angiography showed a communication of the vascular lesion with the left vertebral artery through a narrow, saccular lesion (► Fig. 6). The patient was submitted to a left far lateral approach with partial resection of the occipital condyle and the C1 left arch, to better approach the lesion, which had an intimate contact with the vertebral artery and ipsilateral brainstem (► Fig. 7). Additionally, we used indocyanine green to address the intraoperative flowmetry after clipping.

Then, the artery remained for 20 minutes with a provisional straight clip, which caused a decrease in the potential of the ipsilateral XII cranial nerve in this period, with a return after the clip was repositioned (► Fig. 8). The patient was discharged in the seventh postoperative day, without neurological impairment.

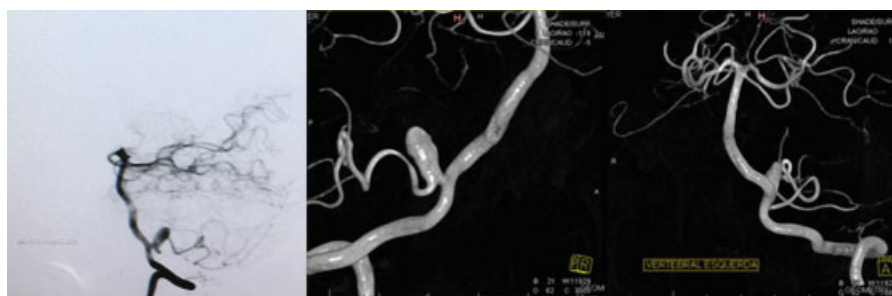
## Discussion

Complex aneurysms are difficult lesions to treat. Their irregular morphology and atypical location and characteristics make surgery attempts potentially harmful and challenging. On the other hand, due to such peculiarities, treatment by endovascular means is not ideal, or may be used just in the context of a staged or partial procedure. Therefore, developing a surgical strategy and additional intraoperative information is key in these cases.<sup>1-10</sup>

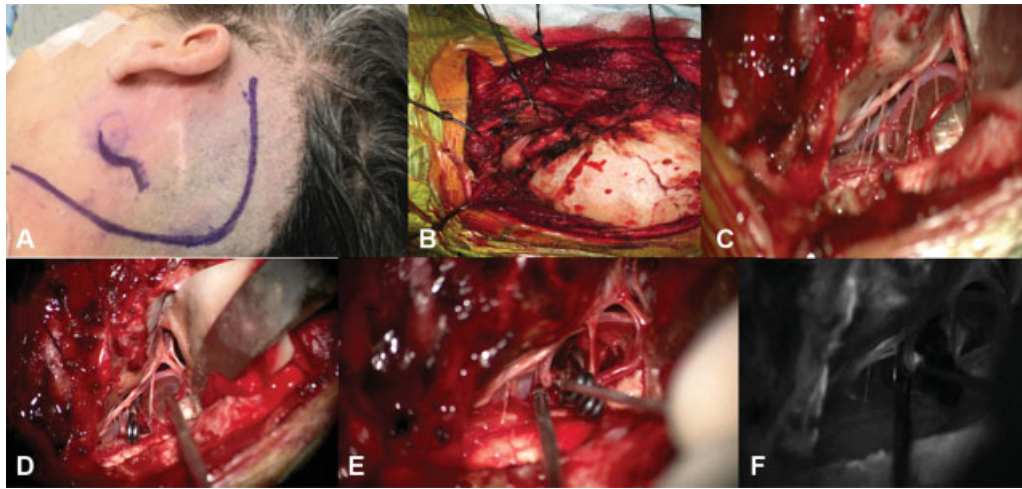
Complex and giant aneurysms of the ICA (diameter > 2.5 cm) are sometimes associated with life-threatening complications such as a mass effect, thromboembolic ischemic stroke, and hemorrhage. Patients can deteriorate rapidly, with neurological deficits that can lead to death after the rupture of the aneurysm. The risk of injury to perforating arteries is high, resulting in neurological deficits.<sup>11-18</sup>

In the first case herein presented, the major concern was the injury to ICA perforators. The reconstruction was accomplished by clipping the proximal ACA and reconstructing bifurcation walls with clips without changes in neurophysiology parameters. This technique was previously described,<sup>3</sup> and may be used in complex aneurysms of the ICA bifurcation when the communicating complex is functional and able to provide collateral flow to the ipsilateral ACA territory.<sup>3</sup>

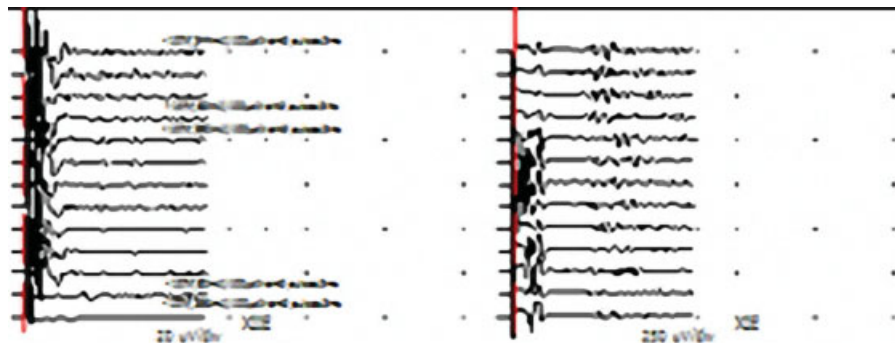
The decision of when to perform the clipping and bypass remains controversial. There are advantages and disadvantages to each technique. Data from the literature shows that 95% of patients with extracranial to intracranial (EC-IC) bypass and ICA occlusion had relatively good results, as



**Fig. 6** Posterior inferior cerebellar artery (PICA) aneurysm arising together with the PICA and measuring 10 × 6 mm.



**Fig. 7** Surgery by a far lateral approach to enable the manipulation of the anterior and lateral lower medullas. Clipping of the aneurysm and postclipping with indocyanine green (ICG).



**Fig. 8** Loss of motor potential of the XI and XII nerves after initial clipping, demanding repositioning, after which the potentials became normal.

indicated by the Glasgow coma scale (GCS) after 3 to 64 months of follow-up, but those cases were also associated with an incidence of 10% of postoperative obstruction with the bypass technique.<sup>6-15</sup> This finding indicates that, for patients with anastomotic obstruction, bypass surgery may be unnecessary. Then, the clipping technique can be the best choice to protect the main vessel (ICA). Moreover, the ideal technique depends on the expertise of the surgical team, and may change also depending on intraoperative findings.

Temporary occlusion is required during the clipping and bypass procedures. Collateral circulation and tolerance to brain ischemia while the ICA is temporarily occluded is generally assessed according to the preoperative occlusion test. Under general anesthesia, however, this preoperative analysis may be unreliable, because the metabolic demand of the anesthetized brain is lower than that of the waking brain.

The second case (giant aneurysm located in the infratentorial region) originated in the left vertebral artery, and caused mass effect in the brainstem, in addition to having the PICA originating along the neck of the lesion. Clamping of this artery to empty the complex aneurysm was unavoidable. Then, it remained for 20 minutes with a provisional straight clip, which caused a decrease in the potential of the ipsilateral XII cranial nerve in this period, with a return after the clip was repositioned.

Motor-evoked potentials appear to be more sensitive than SEPs for cerebral blood flow deficit, for they can detect subcortical ischemia or infarction during the operation in less than 1 minute, especially pure motor deficits caused by perforating arteries or large branches. In our cases, the MEPs correlated with the postoperative neurological status.<sup>2-6</sup>

Some reports highlight the use of other intraoperative strategies to address functional status during surgery. Some studies emphasize the use of micro Doppler probes to make real-time evaluations of arterial blood flow.<sup>2-6</sup> They are useful to analyze blood flow inside the aneurysm and especially after clipping, to evaluate the patency of the vessel.<sup>5</sup> In the case of the performance of a bypass, it is also useful to analyze the patency of the bypass. Other groups reported the application of awake craniotomies to perform complex aneurysm clipping.<sup>4</sup> Similarly to functional neurological tumor surgery, awake craniotomies would enable a better visualization of functional impairment during surgery, with higher accuracy compared with routine neurophysiological monitoring.<sup>4</sup> Although we recognize the potential benefits of both strategies, we did not apply them in our cases.

Another peculiarity of our cases was that we did not use endovascular means. Had we chosen to use the endovascular treatment, we would not have intraoperative monitoring in our favor, and, due to the morphology of the lesions, we

would have faced an increased risk of obstruction, and, consequently, morbidity and mortality in the postoperative period of these complex lesions. Additionally, ours were cases of unruptured aneurysms. Surely, we managed them rapidly, but had time to make the best preoperative planning. In the scenario of ruptured aneurysms, especially depending on the severity of the clinical profile, there is no time to adequately plan surgery and use all the multimodal neuro-monitoring modalities available.

Thus, we believe that treating small or large aneurysms in usual presentations may be performed with safety in the routine neurosurgical set up. Nevertheless, cases of complex and giant aneurysms carry several pitfalls, and the use of multimodal intraoperative monitoring is mandatory to mitigate risks and deliver the best result to the patient.

#### Conflict of Interests

The authors have none to declare.

#### References

- Friedman WA, Chadwick GM, Verhoeven FJS, Mahla M, Day AL. Monitoring of somatosensory evoked potentials during surgery for middle cerebral artery aneurysms. *Neurosurgery* 1991;29(01):83–88
- Pahl FH, Oliveira MF, Brock RS, Lucio JE. Application of indocyanine green video angiography in surgical treatment of intracranial aneurysms. *Arq Neuropsiquiatr* 2015;73(07):607–610
- Pahl FH, de Oliveira MF, Beer-Furlan AL, Rotta JM. Surgical flow modification of the anterior cerebral artery-anterior communicating artery complex in the management of giant aneurysms of internal carotid artery bifurcation: An alternative for a difficult clip reconstruction. *Surg Neurol Int* 2016;7(Suppl 14):S405–S409
- Abdulrauf SI, Urquiaga JF, Patel R, et al. Awake High-Flow Extracranial to Intracranial Bypass for Complex Cerebral Aneurysms: Institutional Clinical Trial Results. *World Neurosurg* 2017;105:557–567
- Pereira BJ, Holanda VM, Giudicissi-Filho M, Borba LA, de Holanda CV, de Oliveira JG. Assessment of Cerebral Blood Flow with Micro-Doppler Vascular Reduces the Risk of Ischemic Stroke During the Clipping of Intracranial Aneurysms. *World Neurosurg* 2015;84(06):1747–1751
- Greve T, Stoecklein VM, Dorn F, et al. Introduction of intraoperative neuromonitoring does not necessarily improve overall long-term outcome in elective aneurysm clipping. *J Neurosurg* 2019;••:1–9
- Grigorian AA, Marcovici A, Flamm ES. Intraoperative factors associated with surgical outcome in patients with unruptured cerebral aneurysms: the experience of a single surgeon. *J Neurosurg* 2003;99(03):452–457
- Holland NR. Subcortical strokes from intracranial aneurysm surgery: implications for intraoperative neuromonitoring. *J Clin Neurophysiol* 1998;15(05):439–446
- Kothbauer KF, Deletis V, Epstein FJ. Motor-evoked potential monitoring for intramedullary spinal cord tumor surgery: correlation of clinical and neurophysiological data in a series of 100 consecutive procedures. *Neurosurg Focus* 1998;4(05):e1
- MacDonald DB. Safety of intraoperative transcranial electrical stimulation motor evoked potential monitoring. *J Clin Neurophysiol* 2002;19(05):416–429
- Neuloh G, Schramm J. Intraoperative neurophysiological mapping and monitoring. In Deletis V, Shils J (eds): *Neurophysiology in Neurosurgery: A Modern Intraoperative Approach*, ed 1. New York: Academic Press; 2002:386–387
- Quiñones-Hinojosa A, Alam M, Lyon R, Yingling CD, Lawton MT. Transcranial motor evoked potentials during basilar artery aneurysm surgery: technique application for 30 consecutive patients. *Neurosurgery* 2004;54(04):916–924, discussion 924
- Suzuki K, Kodama N, Sasaki T, et al. Intraoperative monitoring of blood flow insufficiency in the anterior choroidal artery during aneurysm surgery. *J Neurosurg* 2003;98(03):507–514
- Szelényi A, Bueno de Camargo A, Flamm E, Deletis V. Neurophysiological criteria for intraoperative prediction of pure motor hemiplegia during aneurysm surgery. Case report. *J Neurosurg* 2003;99(03):575–578
- Szelényi A, Kothbauer K, de Camargo AB, Langer D, Flamm ES, Deletis V. Motor evoked potential monitoring during cerebral aneurysm surgery: technical aspects and comparison of transcranial and direct cortical stimulation. *Neurosurgery* 2005;57(4, Suppl):331–338, discussion 331–338
- Della Puppa A, Rossetto M, Volpin F, et al. Microsurgical Clipping of Intracranial Aneurysms Assisted by Neurophysiological Monitoring, Microvascular Flow Probe, and ICG-VA: Outcomes and Intraoperative Data on a Multimodal Strategy. *World Neurosurg* 2018;113:e336–e344
- Heiroth HJ, Etminan N, Steiger HJ, Hänggi D. Intraoperative Doppler and Duplex sonography in cerebral aneurysm surgery. *Br J Neurosurg* 2011;25(05):586–590
- Roessler K, Krawagna M, Dörfler A, Buchfelder M, Ganslandt O. Essentials in intraoperative indocyanine green videoangiography assessment for intracranial aneurysm surgery: conclusions from 295 consecutively clipped aneurysms and review of the literature. *Neurosurg Focus* 2014;36(02):E7