

Multifocal Pseudotumorous Form of Neuroparacoccidioidomycosis in an Immunocompetent Patient: A Clinicopathological Review Based on a Case Report

Neuroparacoccidioidomicose multifocal de forma pseudotumoral em paciente imunocompetente: Uma revisão clinicopatológica baseada em um relato de caso

Eduardo Cambruzzi^{1,2,3,4,5} Karla Lais Pêgas^{2,3} Gabriella Bezerra Cortês Nascimento⁶
José Nathan Andrade Muller da Silva⁶ Natália Brandelli Zandoná⁶ William Pegoraro Kus⁶
Felipe Lourezon Schiavo⁷ Samir Cezimbra dos Santos⁷

¹ Department of Pathology, Universidade Federal do Rio Grande do Sul, Porto Alegre, RS, Brazil

² Department of Pathology, Hospital Santa Rita, Complexo Hospitalar Santa Casa, Porto Alegre, RS, Brazil

³ Department of Pathology, Grupo Hospitalar Conceição, Porto Alegre, RS, Brazil

⁴ Department of Pathology, Universidade Luterana do Brasil, Canoas, RS, Brazil

⁵ Department of Pathology, Instituto de Cardiologia, Fundação Universitária de Cardiologia, Porto Alegre, RS, Brazil

⁶ Grupo Hospitalar Conceição, Porto Alegre, RS, Brazil

⁷ Department of Neurosurgery, Grupo Hospitalar Conceição, Porto Alegre, RS, Brazil

Address for correspondence Eduardo Cambruzzi, MD, PhD, Departamento de Patologia, Hospital Santa Rita, Complexo Hospitalar Santa Casa, Rua Sarmento Leite, 187, 2º andar, Porto Alegre, RS, Brazil (e-mail: dudacambuzzi@yahoo.com.br).

Arq Bras Neurol 2021;40(2):e195–e199.

Abstract

Keywords

- ▶ paracoccidio-
mycosis
- ▶ south american
blastomycosis
- ▶ paracoccidioides
brasiliensis
- ▶ central nervous
system
- ▶ mycosis
- ▶ pathology

Neuroparacoccidioidomycosis (NPDM) is an uncommon granulomatous disease, which more frequently affects immunocompromised male patients over 30 years of age in the course of chronic lung disease. *Paracoccidioides brasiliensis* (PB) is an endemic fungus in Brazil, and grows as thick-walled yeast (with round to oval bodies) measuring 10 µm to 60 µm in diameter. Neuroparacoccidioidomycosis may develop many years after transmission and/or primary lung involvement. The authors describe a case of NPDM affecting a male patient, 52 years of age, farmer, heavy smoker, with clinical complaint of headache, asthenia, seizures, and prostration in the previous nine months. Upon physical examination, the patient presented regular general condition, without other relevant physical alterations. Computed tomography (CT) showed multiple bilateral pulmonary nodules associated to enlargement of the mediastinal lymph node. Magnetic resonance imaging (MRI) and CT scans of the central nervous system showed

received
January 7, 2020
accepted
August 24, 2020
published online
November 26, 2020

DOI <https://doi.org/10.1055/s-0040-1719005>.
ISSN 0103-5355.

© 2020. Sociedade Brasileira de Neurocirurgia. All rights reserved.
This is an open access article published by Thieme under the terms of the Creative Commons Attribution-NonDerivative-NonCommercial-License, permitting copying and reproduction so long as the original work is given appropriate credit. Contents may not be used for commercial purposes, or adapted, remixed, transformed or built upon. (<https://creativecommons.org/licenses/by-nc-nd/4.0/>)
Thieme Revinter Publicações Ltda., Rua do Matoso 170, Rio de Janeiro, RJ, CEP 20270-135, Brazil

six heterogeneous nodular lesions compromising the frontal and parietal lobes, the largest one measuring $3.8 \times 3.2 \times 3.2$ cm. The hypothesis of a neoplastic process compromising the lung and brain was considered. A biopsy of the mediastinal lymph node showed epithelioid granulomas, which exhibited round, thin-walled fungal structures in Grocott silver stain. The stereotactic biopsy of the frontal lesion was constituted by necrotic tissue admixed with some round to oval, thin-walled fungi measuring $10 \mu\text{m}$ to $60 \mu\text{m}$, compatible with PB (identified on Grocott silver stain/confirmed in culture). The diagnosis of NPDM was then established. The employed therapeutic regimen was intravenous amphotericin B, itraconazole, and sulfamethoxazole-trimetoprim. After ninety days of clinical follow-up, no episodes of seizures/neurological deficits were identified, and a marked decrease in the number and size of the lung and brain lesions were found.

Resumo

A neuroparacoccidioidomicose (NPDM) é uma doença granulomatosa incomum, que acomete mais frequentemente pacientes imunocomprometidos do sexo masculino com mais de 30 anos, no curso de doença pulmonar crônica. *Paracoccidioides brasiliensis* (PB) é um fungo endêmico no Brasil e cresce como levedura de parede espessa (com corpos arredondados a ovais) medindo $10\text{--}60 \mu\text{m}$ de diâmetro. A NPDM pode se desenvolver muitos anos após a transmissão e / ou envolvimento pulmonar primário. Os autores descrevem um caso de NPDM em paciente masculino, 52 anos, agricultor, tabagista pesado, com queixa clínica de cefaleia, astenia, convulsões e prostração nos últimos nove meses. Ao exame físico, o paciente apresentava estado geral regular, sem outras alterações físicas relevantes. A tomografia computadorizada (TC) mostrou múltiplos nódulos pulmonares bilaterais associados a linfonodomegalia mediastinal. A TC / ressonância magnética do sistema nervoso central revelou seis lesões nodulares heterogêneas comprometendo os lobos frontal e parietal, a maior delas medindo $3,8 \times 3,2 \times 3,2$ cm. Foi considerada a hipótese do processo neoplásico comprometendo pulmão e cérebro. A biópsia de linfonodo mediastinal mostrou granulomas epitelioides, que exibiam estruturas fúngicas arredondadas e de paredes finas na coloração pela prata de Grocott. A biópsia estereotáxica da lesão frontal era constituída por tecido necrótico entremeado por algumas estruturas fúngicas redondas a ovais e de parede fina, medindo $10\text{--}60 \mu\text{m}$, compatível com PB (identificado na coloração de prata Grocott / confirmado em cultura). O diagnóstico de NPDM foi então estabelecido. O esquema terapêutico empregado foi anfotericina B intravenosa, itraconazol e sulfametoxazol-trimetropina. Após 90 dias de acompanhamento clínico, nenhum episódio de convulsão / déficit neurológico foi identificado, e uma diminuição acentuada no número e tamanho das lesões pulmonares e cerebrais foi encontrada.

Palavras-chave

- ▶ paracoccidioidomicose
- ▶ blastomicose da América do Sul
- ▶ paracoccidioides brasiliensis
- ▶ sistema nervoso Central
- ▶ Micose
- ▶ patologia

Introduction

Central nervous system (CNS) mycoses have assumed greater importance as the number of immunocompromised patients has increased over the past few decades.^{1–3} Fungal infections in the CNS have also been increasing, because of the growing use of complex surgical procedures, invasive medical devices, and long-term broad-spectrum antibiotics. Considerable progress has been made in our understanding of fungal pathobiology, in special due to the sequencing of fungal genomes and the employment of animal models to determine the different components of fungal virulence.^{1–3} The epidemiology of CNS

fungal disease is variable in the literature. Relevant epidemiological data come from the database of the Transplant-Associated Infection Surveillance Network.⁴ Many CNS mycoses are preceded by lung infections, and fungi reach the CNS via the hematogenous route. The risk factors that lower host resistance include neutropenia, hematological malignancy, steroids, diabetes mellitus, systemic lupus, renal failure, and impaired cell-mediated immunity.^{1,2,4}

Paracoccidioidomycosis (PDM), or South American blastomycosis, is caused by *Paracoccidioides brasiliensis* (PB). The fungi grow as thick-walled yeast with round to oval bodies, which are $10 \mu\text{m}$ to $20 \mu\text{m}$ in diameter and give rise to single or

multiple thin-necked buds.^{1,5,6} These fungi probably live in the vegetation or soil. Usually, PDM is a granulomatous disease that initially compromises the lungs and the oral mucosa, and then spreads to the lymph nodes, the adrenal glands, and, rarely, to the CNS.^{1,3,5,6} Herein, the authors present a case of neuroparacoccidioidomycosis (NPDM) affecting an immuno-competent male patient, and discuss the pathological and clinical data of this uncommon cerebral mycosis.

Case Report

A male patient, 52 years of age, farmer, heavy smoker for 30 years, was referred to the hospital service with a clinical complaint of headache, asthenia, fatigue, and prostration in the previous nine months. Upon physical examination, the patient presented a regular general condition, without other relevant physical alterations. The patient's previous history did not present significant pathological processes. A conventional chest radiological study revealed a micronodular interstitial infiltrate in both lungs. A computed tomography (CT) scan of the chest showed multiple bilateral and coalescent pulmonary nodules associated to enlargement of the mediastinal lymph node (►Fig. 1). The patient evolved with episodes of seizures. The hypothesis of a neoplastic process compromising the lung and brain was considered. Magnetic resonance imaging (MRI) and CT scans of the CNS showed 6 heterogeneous nodular lesions, which compromised predominantly the white matter of the frontal and parietal lobes bilaterally, with surrounding areas of edema and narrowing zones of the brain grooves, and the largest one measured $3.8 \times 3.2 \times 3.2$ cm (►Fig. 2). The lesions were hypointense at T2, with a slight peripheral signal at T1 and diffusion restriction. On the CT/MRI scans of the abdomen, no significant alterations were observed. The patient had negative serology for HIV, hepatitis B and C, syphilis and toxoplasmosis. An analysis of the cerebrospinal fluid (CSF) did not reveal any significant data. In a biopsy of the mediastinal lymph node, we identified anthracosis and the formation of epithelioid granulomas, which exhibited small, round, thin-walled fungal structures in Grocott silver stain. A stereotactic biopsy of the frontal

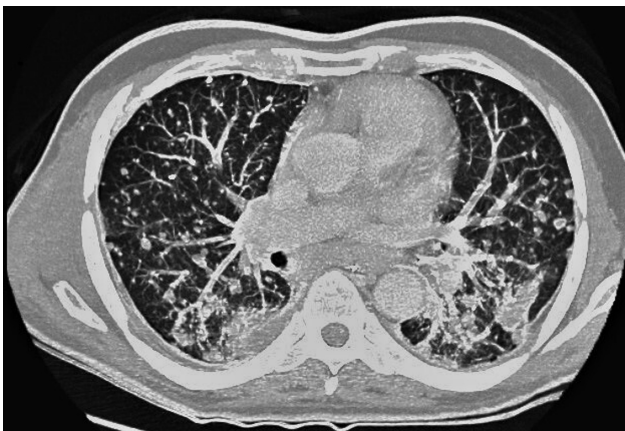


Fig. 1 Lung paracoccidioidomycosis: computed tomography scan exhibiting multiple bilateral and coalescent pulmonary nodules.

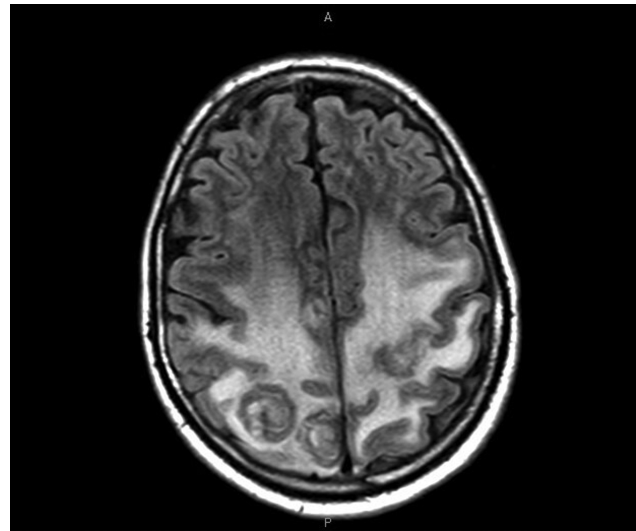


Fig. 2 Neuroparacoccidioidomycosis: magnetic resonance imaging (axial – fluid attenuated inversion recovery [FLAIR] image) scan showing two heterogeneous nodular lesions compromising the parietal lobes, with surrounding areas of edema.

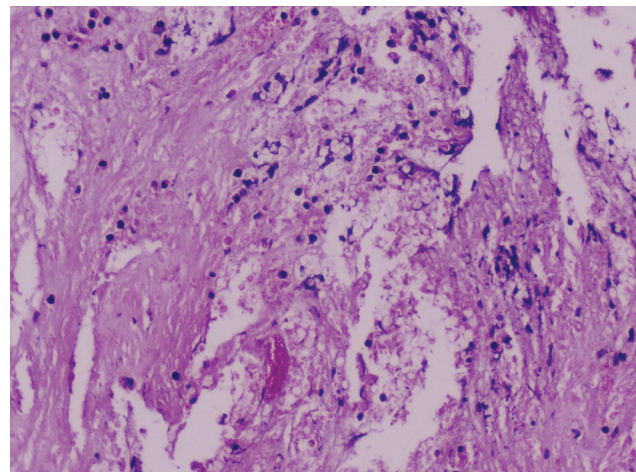


Fig. 3 Central nervous system paracoccidioidomycosis: necrotic tissue obtained by stereotactic biopsy, hematoxylin-eosin, 100X.

lesion was constituted by an amorphous, eosinophilic necrotic tissue (hematoxylin-eosin technique; ►Fig. 3) admixed by some round to oval, thin-walled fungal structures measuring $10\mu\text{m}$ to $60\mu\text{m}$, compatible with PB (identified on Grocott silver stain and confirmed in culture; ►Fig. 4). The diagnosis of pulmonary PDM determining secondary involvement of the CNS was then established. The proposed therapeutic regimen was the use of intravenous amphotericin B, itraconazole, and sulfamethoxazole-trimetropin. In the first week of the pharmacological treatment, the patient developed respiratory failure, hypokalemia, and hypomagnesemia, and mechanical ventilation was started. Thirty days after this episode, the patient showed an improvement in his general clinical condition. After ninety days of clinical follow-up, no episodes of seizures or neurological deficits were identified, and a marked decrease in the number and size of the lung and brain lesions was observed.

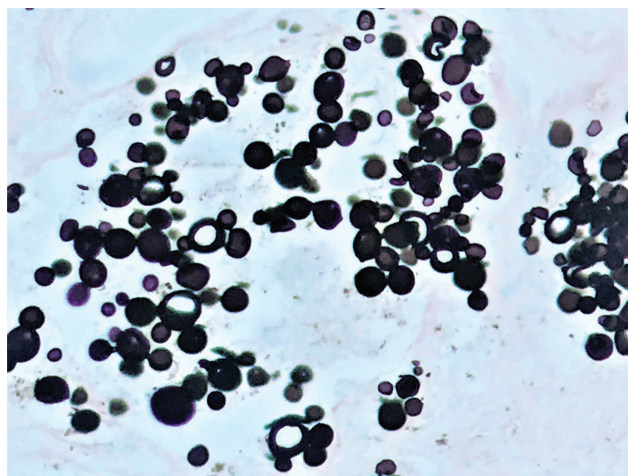


Fig. 4 Central nervous system paracoccidioidomycosis: thick-walled yeasts with round to oval bodies identified in Grocott methenamine silver stain, 200X.

Discussion

First described by Lutz in 1908, PDM is very restricted to geographic areas such as Central and South America. In Brazil, PDM is an endemic disease.^{1,7-9} Most compromised patients are over 30 years of age, and males are more frequently affected. The lungs are primarily involved, and symptoms of PDM often develop many years after transmission.^{1,7-9} This long latent period may be due to the fungus lying dormant in the lymph nodes. The severity of the disease is related to host immunity. Most patients present with various combinations of fever, cough, night sweats, weight loss, or chills. Pulmonary findings may be localized or may be part of a more disseminated disease.⁷⁻¹¹ A small number of patients remain subclinical. Acute lung infection rapidly spreads to the lymph nodes, liver and spleen. Radiological findings are unspecific, and include micronodular infiltrates, foci of consolidation, cavities, fibrosis or, infrequently, calcified nodules.⁷⁻¹¹ The histopathological findings range from neutrophilic microabscesses, scattered interstitial necrotizing granulomas, and consolidative granulomatous pneumonia. Progressive pulmonary disease is more common than acute/subacute lung involvement.^{2,3,5,8,12} It compromises older patients who probably develop reactivation many years after transmission. Chests radiographs exhibit confluent/patchy nodular infiltrates in the mid/basal segments, usually bilateral and symmetrical. The pathological findings include lung scarring with a coarse, hobnail appearance, cavities, ulceration of the large airways, bronchiectasis, dense fibrous pleural adhesions, and pleural effusions.^{2,3,5,8,12} Lung PDM can resemble and coexist with blastomycosis and tuberculosis, and a mixed piogenic and granulomatous inflammatory response is typical of the disease. Numerous organisms are usually present within giant cells.^{2-4,6,8,9}

Dissemination from a primary lung disease may involve regional lymph nodes and eventually the CNS, which is usually related to the chronic form of the pulmonary disease and male patients after the third decade of life who live in rural areas. The

prevalence of NPDM ranges from 4% to 15% of cases of systemic PDM.^{1,4,10,12,13} Manifestations of the involvement of the CNS include headache, lethargy, raised intracranial pressure, and personality changes. Neuroparacoccidioidomycosis is most commonly associated with symptoms and signs of an expansive lesion in the brain (pseudotumorous form) or to a meningitic form.^{2,3,5,8,9,12,14} On gross, the most common form of NPDM is the pseudotumorous form, which usually exhibits well-circumscribed necrotic nodules measuring from a few millimeters to several centimeters in diameter. Supratentorial lesions are predominantly found in NPDM (around 70% of the cases), and the frontal and parietal lobes are the most common locations.^{2,3,5,8,9,12,14} Spinal PDM accounts for 0.6% of all cases of systemic PDM, and for 4% of the cases of NPDM.^{4,5,10} The leptomenigeal form is granulomatous, predominantly basal, and may cause hydrocephalus. When it affects the dura mater, NPDM may resemble meningiomas. On microscopy, paracoccidioidomycosis (pseudotumorous form) exhibit granulomas composed of epithelioid macrophages, Langhans giant cells, necrotic central areas, and lymphocytes.^{2,5,8,12,13,15} A chronic inflammatory infiltrate can be identified in the leptomeninges, and this infiltrate can extend along the Virchow-Robin space into the underlying brain tissue, especially in the hypothalamus.^{2,5,8,12,13,15}

A dimorphic fungus, PB forms oval to round yeasts with multiple buds at 37°C in tissues and in cultures. The fungus is a white mold composed of thin septate hyphae that produce chlamydoconidia, and, when cultured, it produces < 5 µm asexual propagules known as microconidia (probably the infectious particle).^{1,2,7,9,14,16} In tissue sections, the organisms are round to oval and 10 µm to 60 µm in diameter, and have thin, refractive walls. In the hematoxylin-eosin technique, their contents may be basophilic or amphophilic.^{1,2,7,9,14} *P. brasiliensis* reproduces by multiple buds, which can be roughly equal or may vary in size and are linked to the parent by narrow buds. In fibrous longstanding granulomatous lesions, the yeasts may be fragmented, distorted and unevenly stained by fungal stains. Rarely, hyphae are formed in the tissues.^{3,5,12,13,16} Diagnosis of lung disease can be established by sputum, bronchioalveolar lavage, and biopsies. If the submitted material is warmed with 5% potassium hydroxide (KOH), the yeasts are doubly refractive. Cell-block preparations and histological slides stained with Grocott silver stain are also sensitive techniques. In cultures, mold colonies can be obtained after incubation in Sabouraud dextrose agar supplemented with cycloheximide.^{3,5,12,13} Serological tests are also useful for the presumptive diagnosis of NPDM, and these tests can be used to monitor the response to the treatment too.^{2,12,13,16-19} The CSF analysis has both low sensitivity and low specificity. Gp43 and gp70 PB antigens in body fluids and in the CSF (in-house enzyme-linked immunosorbent assay [ELISA] method) can be helpful for the diagnosis of the disease. The ELISA anti-gp43 has 89% of sensitivity and 10% of specificity.^{12,13,16-19} The CT/MRI scans exhibit an expansive, ring-enhancement lesion, with surrounding edema, in the pseudotumorous form of NPDM. On MRI, the pseudotumorous form can appear as hyper-, iso-, or hypointense lesions on T1 and T2-weighted imaging.

Diffusion-weighted imaging does not normally demonstrate signal restriction.^{2,5,6,13,21} In the present case, the authors report an immunocompetent, heavy smoker farmer, who developed the classic pseudotumorous form of NPDM in the course of concomitant chronic lung disease. The initially-admitted clinical hypothesis was primary lung neoplasia with secondary implants in the brain parenchyma, due previous history of smoking and the radiological data. The identification of fungal structures in the mediastinal lymph nodes and brain biopsies was fundamental to establish the final diagnosis and correct clinical management.

Differential diagnosis includes *Coccidioides immitis* (sporangia measuring 30 µm to 60 µm and containing 1 µm to 5 µm sporangiospores – it usually occurs as meningitis), *Histoplasma capsulatum* (a dimorphic, ovoid fungi, measuring 2 µm to 5 µm), and *Cryptococcus neoformans* (yeasts measuring 4 µm to 7 µm and exhibiting a mucinous capsule).^{1,2,7,12,13,19,20,22} In the presence of the pseudotumorous form of NPDM, the differential diagnosis also includes neoplasms (primary and secondary), abscesses, tuberculosis, and neurocysticercosis.^{7,12,13,19,20,22–24} The therapy includes sulfonamides, amphotericin B and azoles (fluconazole, itraconazole, voriconazole).^{2,3,8,11,13,14,19} Actually, the combination of oral fluconazole and trimethoprim-sulfamethoxazole for long periods (more than 12 months) is also employed in NPDM.^{2,3,7,11,13,14,19}

Funding

No funding was received.

Conflict of Interests

The author have no conflict of interests to declare.

References

- de Almeida SM, Salvador GLO, Roza TH, et al. Geographical evaluation of Neuroparacoccidioidomycosis and Paracoccidioidomycosis in Southern Brazil. *Mycoses* 2018;61(08):587–593
- Carvalho de Medeiros F, Curcio de Moraes A, Buzelin Nunes M, Dellaretti M. Neuroparacoccidioidomycosis mimicking brain tumor in an immunocompetent patient. *Rev Neurol (Paris)* 2018;174(04):268–271
- Silva-Vergara ML, Rocha IH, Vasconcelos RR, et al. Central nervous system paracoccidioidomycosis in an AIDS patient: case report. *Mycopathologia* 2014;177(1-2):137–141
- Kontoyannis DP, Marr KA, Park BJ, et al. Prospective surveillance for invasive fungal infections in hematopoietic stem cell transplant recipients, 2001–2006: overview of the Transplant-Associated Infection Surveillance Network (TRANSNET) Database. *Clin Infect Dis* 2010;50(08):1091–1100
- dos Santos VM, Xavier RM, Cortes JA, Osterne EM, de Worisch Ferreira Lopes M. Pseudotumoral neuroparacoccidioidomycosis: one case report. *Mycopathologia* 2008;166(03):155–158
- Reis F, Collier PP, Souza TF, et al. Neuroparacoccidioidomycosis (NPCM): magnetic resonance imaging (MRI) findings. *Mycopathologia* 2013;175(1-2):181–186
- Gomes Carvalho Neto E, Coletto A, Biazus PG, Pereira Dos Santos I, Rieder CRM, de Castro Ribeiro M. Neuroparacoccidioidomycosis. *Neurol Neuroimmunol Neuroinflamm* 2018;6(01):e519
- de Almeida SM, Roza TH, Salvador GLO, et al. Neurological and multiple organ involvement due to Paracoccidioides brasiliensis and HIV co-infection diagnosed at autopsy. *J Neurovirol* 2017;23(06):913–918
- Fagundes-Pereyra WJ, Carvalho GT, Góes AM, das Chagas Lima e Silva F, de Sousa AA. [Central nervous system paracoccidioidomycosis: analysis of 13 cases]. *Arq Neuropsiquiatr* 2006;64(2A):269–276
- de Almeida SM, Roza TH, Salvador GLO, et al. Autopsy and biopsy study of paracoccidioidomycosis and neuroparacoccidioidomycosis with and without HIV co-infection. *Mycoses* 2018;61(04):237–244
- Francesconi F, da Silva MT, Costa RL, et al. Long-term outcome of neuroparacoccidioidomycosis treatment. *Rev Soc Bras Med Trop* 2011;44(01):22–25
- Dall Bello AG, Severo CB, Oliveira FdeM, Severo LC. Disseminated paracoccidioidomycosis (simulating metastatic lung cancer) and Strongyloides stercoralis hyperinfestation in a steroid-treated patient. *J Clin Microbiol* 2011;49(05):2054–2055
- Dias AB, Giugno CS, Scapinelli JO, Tarso GP, Curtis RM, Lenhardt R. Neuroparacoccidioidomycosis with concomitant pulmonary and vocal cord lesions. *Arq Neuropsiquiatr* 2018;76(11):802–804
- Elias J Jr, dos Santos AC, Carlotti CG Jr, et al. Central nervous system paracoccidioidomycosis: diagnosis and treatment. *Surg Neurol* 2005;63(Suppl 1):S13–S21, discussion S21
- Alves GR, Lauda Filho JD, Haygert CJ. Neuroparacoccidioidomycosis. *Rev Soc Bras Med Trop* 2011;44(05):654
- de Almeida SM, Queiroz-Telles F, Teive HA, Ribeiro CE, Werneck LC. Central nervous system paracoccidioidomycosis: clinical features and laboratorial findings. *J Infect* 2004;48(02):193–198
- Paniago AM, de Oliveira PA, Aguiar ES, et al. Neuroparacoccidioidomycosis: analysis of 13 cases observed in an endemic area in Brazil. *Trans R Soc Trop Med Hyg* 2007;101(04):414–420
- Marques da Silva SH, Colombo AL, Blotta MH, Lopes JD, Queiroz-Telles F, Pires de Camargo Z. Detection of circulating gp43 antigen in serum, cerebrospinal fluid, and bronchoalveolar lavage fluid of patients with paracoccidioidomycosis. *J Clin Microbiol* 2003;41(08):3675–3680
- Jorge LA Jr, Yamashita S, Trindade AP, et al. Pseudotumoral neuroparacoccidioidomycosis of the posterior fossa: A case report and review of the literature. *Surg Neurol Int* 2017;8:76
- Rosa Júnior M, Amorim AC, Baldon IV, et al. Paracoccidioidomycosis of the central nervous system: CT and MR imaging findings. *AJNR Am J Neuroradiol* 2019;40(10):1681–1688
- Corti M, Trione N, Risso D, et al. Disseminated paracoccidioidomycosis with a single brainstem lesion. A case report and literature review. *Neuroradiol J* 2010;23(04):454–458
- Buccheri R, Benard G. Opinion: Paracoccidioidomycosis and HIV immune recovery inflammatory syndrome. *Mycopathologia* 2018;183(03):495–498
- de Almeida SM, Roza TH. HIV immune recovery inflammatory syndrome and central nervous system paracoccidioidomycosis. *Mycopathologia* 2017;182(3-4):393–396
- Pedroso VS, Vilela MC, Santos PC, Cisalpino PS, Rachid MA, Teixeira AL. Traffic of leukocytes and cytokine up-regulation in the central nervous system in a murine model of neuroparacoccidioidomycosis. *Mycopathologia* 2013;176(3-4):191–199