



Neonatal listeriosis a diagnostic challenge: case report and review of the literature

Carlos Andrés Espinosa Rivas* ¹, Cristina Elizabeth Tafur Ochoa ^{2,3}, Daniel Vicente Puertas Tumipamba  ^{2,3}

1. Neonatology Service, San Francisco de Quito General Hospital, Ecuadorian Social Security Institute, Quito, Ecuador.
2. Pediatric Service, San Francisco de Quito General Hospital, Ecuadorian Social Security Institute, Quito, Ecuador.
3. Faculty of Health Sciences "Eugenio Espejo", Universidad Tecnológica Equinoccial, Quito, Ecuador.

Received: January 4, 2023

Accepted: March 27, 2023

Published: April 27, 2023

Editor: Dr. Francisco Xavier Jijón Letort.


Bibliographic letterhead:

Espinosa C, Tafur C, Puertas D. Neonatal listeriosis a diagnostic challenge: case report and review of the literature. Revista Ecuatoriana de Pediatría 2023;24(1):23-29.

DOI: <https://doi.org/10.52011/200>

ECUADORIAN SOCIETY OF PEDIATRICS

e-ISSN: 2737-6494

 Copyright 2023, Carlos Espinosa R, Cristina Tafur O., Daniel Puertas T. This article is distributed under the terms of the [Creative Commons CC BY-NC-SA 4.0 Attribution License](https://creativecommons.org/licenses/by-nc-sa/4.0/), which permits noncommercial use and redistribution provided by the source, and the original author is cited.

Abstract

Introduction: Listeriosis is a low-incidence pathology with mild and self-limiting symptoms in the general population; however, maternal-fetal transmission can generate severe conditions in neonates, manifested as sepsis, meningitis, endocarditis, encephalitis, and meningoencephalitis. Timely diagnosis by clinical and laboratory data in conjunction with adequate therapy favors the resolution of the disease.

Clinical case: A late preterm neonate of 34 weeks, six days of gestational age, was born by repetitive cesarean section at nonvigorous birth with heavy meconium amniotic fluid and required basic and advanced resuscitation.

Evolution: Based on the birth history, an infection study was carried out, with a favorable report and development of *Listeria monocytogenes* in blood cultures, diagnosis of sepsis, meningitis, and conjunctivitis, received intravenous antibiotic therapy, completed treatment, and presented favorable clinical evolution.

Conclusions: In the present case, the listeriosis of maternal-neonatal transmission had a severe presentation with the aspiration of meconium fluid that required intubation and ventilatory support; the patient developed meningitis and conjunctivitis. Chorionitis occurs in the placenta.

Keywords: MESH: Listeriosis, *Listeria monocytogenes*, Newborn, Pregnancy, Meconium, *Listeria meningitis*.

* Corresponding author.

Introduction

Listeria monocytogenes is a short gram-positive bacillus that causes isolated cases or outbreaks of listeriosis and is the primary cause of morbidity and mortality related to food poisoning. It can grow in refrigerated foods with low moisture content and high salt concentration, and it is transmitted by food or direct contact with animals and contaminated environments. After ingesting food, this bacterium survives at the stomach's pH and passes to the small intestine, then to the mesenteric lymph nodes, later to the spleen and liver, to spread to other organs and even cross the blood-brain and blood-placental barriers [1, 2].

The incidence is very low, and the symptoms are mild and self-limited in the general population. Nevertheless, they can cause severe symptoms in elderly individuals, pregnant women, fetuses, newborns, and immunosuppressed patients. The clinical manifestations vary, depending on the patient's age, immunological status, and virulence of the strain, and may appear after a long incubation period (1 day to 70 days). Clinically, they are classified as severe invasive listeriosis and non-invasive febrile gastroenteritis. The first is the most serious, occurring mainly in immunocompromised individuals and manifesting as sepsis, meningitis, endocarditis, encephalitis, and meningoencephalitis [3, 4]. In pregnant women, it can produce abortion, stillbirth, and premature delivery, and in neonates, it can produce sepsis, pneumonia, and meningitis [1]. The second form of clinical presentation is noninvasive gastroenteritis; it occurs in previously healthy or immunocompetent people and is self-limiting, characterized by headache, fever, and watery diarrhea that lasts 2-3 days [3].

Clinical case

Clinical history

Newborn born to a 27-year-old mother, farmer by profession, second pregnancy, 7-year internatal period, diagnoses of vaginitis and urinary tract infection during

pregnancy at 25 and 27 weeks, respectively, received complete antibiotic treatment in each event, no history of immunosuppression, nonreactive HIV and VDRL, and no use of corticosteroids.

The mother went to the Emergency Department at 34 weeks, six days of gestation, due to the date of her last menstrual period, due to presenting labor in the active phase. A male newborn was received by iterative cesarean section, anthropometric measurements: weight 2460 grams (P50-75), height 46 cm (P50-75), head circumference 31 cm (P25-50) (Fenton curve), liquid heavy meconium amniotic fluid, nonvigorous neonate, basic and advanced neonatal resuscitation maneuvers were performed, which included endotracheal intubation for aspiration of meconium fluid and maintenance of the airway. The APGAR score at minute 1 was 5; at 5 minutes of 7 and 10 minutes of 9.

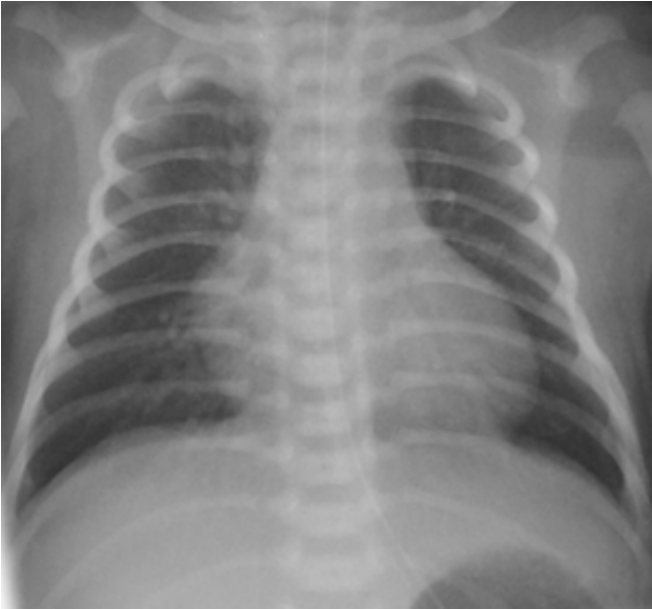
Evolution

The neonate remained on noninvasive ventilatory support for 24 hours, ruling out meconium amniotic fluid aspiration syndrome (Figure 1). No peripartum maternal infection was reported.

Complementary exams

Due to the history of heavy meconium in premature infants, an infection study was requested, with a positive result (Table 1); antibiotic therapy with ampicillin and amikacin was started. After 24 hours of incubation of blood cultures, two bottles reported the growth of gram-positive bacilli, whose final result was *Listeria Monocytogenes*, with sensitivity in the antibiogram for ampicillin, penicillin, and vancomycin. The ampicillin dose was increased to 200 mg/kg/dose. Lumbar puncture with analysis of cerebrospinal fluid (CSF) compatible with bacterial meningitis (Table 2), neonate without signs of neurological focalization, with control of transfontanellar ultrasound without pathological findings, simple and contrasted magnetic resonance imaging study of the brain without evidence of empyemas.

Figure 1. Chest X-ray: Accentuation of the bronchovascular network. Cardiothymic silhouette of size within normal limits with a Cardiothoracic Index of 0.56. Phrenic domes are well defined and of the usual height. Cost angle and free cardio-phrenics.



CSF control six days after antibiotic therapy with a negative report for the bacterial process (Table 2). Pathological study of the placenta reported acute chorionitis. Three days after life, the neonate presented greenish ocular discharge in moderate amounts, with a secretion culture that identified the development of *Listeria Monocytogenes*. He received Tobramycin Ophthalmic for seven days. At five days of life, a neonate with symptoms of respiratory distress due to moderate subcostal retractions required noninvasive ventilatory support, radiographic control with an increase in the pulmonary bronchovascular pattern, infection profile with a decreasing positive C-reactive protein value, and mild thrombocytopenia, without active bleeding (Table 1). A dose of intravenous diuretic was administered, evidencing improvement in the respiratory symptoms. Oxygen supplied by nasal cannula was passed, with which it was maintained until the 7th day of life. It was held at subsequent optimal saturations with FiO2 21%. Echocardi-

ogram control reported mild pulmonary arterial hypertension, 34 mmHg, normal systolic-diastolic function, and restrictive foramen ovale.

Table 1. Results of laboratory studies.

Biomarker	Days of life		
	1st.	5th.	14th.
Leukocytes u/ul	5520	22270	11360
Neutrophils u/ul	3800	11080	4770
Lymphocytes u/ul	880	5400	5210
Monocytes u/ul	560	2020	930
Eosinophils u/ul	70	240	270
Basophils u/ul	40	130	10
Platelets *10 ³ u/ul	209	129	494
Hemoglobin g/dL	15.9	16.9	14.5
Hematocrit %	49.4	47	41.6
C-Reactive Protein mg/L	81.91	28.31	3.31

Table 2. Cerebrospinal fluid analysis .

	1st Analysis	2nd Analysis
Characteristics		
Color	Yellow	rock water
Aspect	Slightly turbid	Transparent
ph	7	7
Cytochemical		
Glucose mg/dl	47.6	36.8
L	82.6	51
Protein mg/dL	119.5	105.2
Mononuclear	2%	96%
Polymorphonuclear	98%	4%
Red Blood Cells u/ul	1	5
White Blood Cells u/ul	550	250
Bacteriological		
Fresh Drop Gram	Rare Gram Positive Cocci.	No Bacteria Observed
Crop	Negative at 48 hours	Negative at 48 hours
Pcr Multiplex Meningitis Panel	Negative	

Resolution

Neonates evolved favorably, without clinical deterioration; a negative biomarker of infection was recorded 13 days after starting antibiotic treatment (Table 1), completed intravenous therapy with Amikacin and Ampicillin, 5 and 21 days, respectively.

Discussion

The incidence of maternal-neonatal listeriosis, defined by listeria in any sample of maternal, fetal, or neonatal origin, in pregnant women has been estimated at 12 per 100,000, compared with 0.7 per 100,000 in the general population. In Europe and North America, 4-10/100,000 pregnant women/year are described; it constitutes a mandatory reporting disease [5- 8]. In underdeveloped countries, no records are kept, but sporadic cases or outbreaks are described [6]. In some studies, pregnant women accounted for 7% of hospitalizations for listeriosis, and neonatal infections accounted for 4% [7].

Maternal infection

The majority of pregnant patients have no significant personal history, and a smaller group have predisposing factors such as diabetes mellitus, immunosuppression (use of corticosteroids, human immunodeficiency virus), liver failure, and splenectomy. Pregnancy increases the risk of contracting invasive listeriosis 18 times more due to the immunosuppression typical of this stage; it can be transmitted to the fetus or newborn through the transplacental route or ascending colonization during childbirth [4].

Clinically, pregnant women may present symptoms of the common cold, with or without gastrointestinal symptoms. According to the medical literature, the following symptoms are presented in order of frequency: fever, common cold, abdominal pain, low back pain, vomiting, diarrhea, headache, myalgia, and throat pain, and one-third of cases may be asymptomatic [8].

Obstetric signs are nonspecific (uterine contractions, labor, reduced fetal movement, rupture of membranes, or abnormal fetal heart rate); if the infection occurs in the first months of pregnancy, it can cause spontaneous abortion, and during the second or third trimester of pregnancy, it could end in miscarriage, stillbirth or premature delivery, or death [9, 10].

In pregnant women, it can be diagnosed in the culture of amniotic fluid, the culture of cervical and vaginal smears, placenta, and blood culture, the latter being the most frequently positive stool culture; it is not recommended since part of the population is a carrier. Serological detection of anti-listeriolysin can be helpful if accompanied by clinical symptoms. Nevertheless, it is not recommended to perform it in all asymptomatic pregnant women because the positive rate of serological antibodies is very high in the general population, even with previous treatment. In the placental biopsy, neutrophil infiltration, focal infarction, calcification, interstitial microabscess, and extensive or necrosis in small blood vessels can be found. The findings were compatible with chorioamnionitis [10].

In the present case, the mother is asymptomatic but presents labor; a premature patient is born with meconium fluid, which makes us suspect an intrauterine infectious process due to listeria; the anatomopathological findings of the placenta confirm the presence of listeria.

Neonatal infection

It is mainly transmitted via the placenta and through the birth canal or through a nosocomial route. It is early onset if it occurs in the first six days of life and late onset after the seventh day.

The most common signs and symptoms in order of frequency in early listeriosis are respiratory distress (cyanosis, apnea, retractions, among others), fever, neurological abnormalities (lethargy, seizures), rash (maculopapular or papulovesicular), and jaundice. Less common is infantisepsis granulomatosis (focal

necrosis in the liver, spleen, lungs, and intestines) [8, 9]. The presence of meconium or brown amniotic fluid has been described in premature infants with listeriosis [10-12].

Diagnosis in the neonate

The presence of the Gram stain of a gram-positive bacillus in a sample of amniotic fluid, other fluids, or skin lesions helps in the presumptive diagnosis. The presence of monocytosis in the blood or the cerebrospinal fluid is not a defining or valuable characteristic [11]. The definitive diagnosis is established mainly by blood culture, followed by positivity in the cerebrospinal fluid culture; the polymerase chain reaction in cerebrospinal fluid is sensitive and specific for the diagnosis of meningitis. Anti-listeriolysin serologic tests can help diagnose invasive and noninvasive listeriosis [9].

Clinically, it can present as pneumonia, bacteremia/sepsis, or meningitis, the latter being the leading cause of death; at a lower gestational age, mortality is higher, or patients survive with neurological dysfunction [8, 12, 13].

Treatment: *L. monocytogenes* does not usually produce β -lactamase, and the addition of β -lactamase inhibitors is unnecessary. Ampicillin continues to be the empirical antibiotic of choice in newborns; if there is no central nervous system involvement, a duration of 10 to 14 days is considered adequate, and in meningitis, 14 to 21 days. Synergism with aminoglycosides is recommended in various guidelines; the results in the studies are diverse, some report a reduction in mortality, and others have not found a beneficial effect. Intravenous trimethoprim/sulfamethoxazole has good in vitro activity. Nevertheless, due to its impact on bilirubin, it is not taken into account as a first option, useful in patients allergic to beta-lactams. It is essential to consider resistance to cephalosporins, vancomycin, and less effective carbapenems, piperacillin/tazobactam [11, 12, 14, 15].

In the present case, the investigation began due to the suspicion that late or moderately premature infants

who present meconium amniotic fluid should be suspected of an infectious process due to *Listeria monocytogenes*, which suggests taking three actions immediately: request the histopathology of the placenta, and two blood cultures, if the latter are positive early, perform a lumbar puncture to establish dose and duration of treatment and avoid long-term neurological sequelae.

Conclusions

In the present case, the listeriosis of maternal-neonatal transmission had a severe presentation with the aspiration of meconium fluid that required intubation and ventilatory support; the patient developed meningitis and conjunctivitis. Chorionitis occurs in the placenta. Maternal-neonatal transmission listeriosis is a rare infection with a severe presentation in this age group and is underdiagnosed in developing countries. It is essential to follow the medical history and laboratory tests in patients with early spontaneous abortions. This pathology can produce spontaneous abortion, death, premature birth, infection, or neonatal death. Epidemiological surveillance and preventive measures should be established.

Abbreviations

CSF: cerebrospinal fluid.

Supplementary information

No supplementary materials are declared.

Acknowledgments

Not declared.

Author contributions

Carlos Andrés Espinosa Rivas: bibliographic review and writing of the manuscript

Cristina Elizabeth Tafur Ochoa: review and critical analysis of the article

Daniel Vicente Puertas Tumipamba: case writing, a compilation of paraclinical tests and biopsies.

All authors read and approved the final version of the manuscript.

Financing

The authors of this article financed the expenses of this research.

The health home financed hospital costs, and there were no additional expenses for the patient's guardians.

Availability of data and materials

Data were collected from medical files and are not publicly available due to patient confidentiality but are available through the corresponding author under clearly justified academic requests.

Statements

Ethics committee approval and consent to participate

Not required for clinical cases.

References

- de Noordhout CM, Devleeschauwer B, Angulo FJ, Verbeke G, Haagsma J, Kirk M, Havelaar A, Speybroeck N. The global burden of listeriosis: a systematic review and meta-analysis. *Lancet Infect Dis*. 2014 November; 14(11): 1073-1082. doi : 10.1016/S1473-3099-14070870-9
[https://doi.org/10.1016/S1473-3099\(14\)70870-9](https://doi.org/10.1016/S1473-3099(14)70870-9)
- Mateus T, Silva J, Maia RL, Teixeira P. Listeriosis during Pregnancy: A Public Health Concern. *Obstetric SNRI Gynecol*. 2013;851712. doi : 10.1155/2013/851712. PMID: 24191199; PMCID: PMC3804396.
<https://doi.org/10.1016/10.1155/2013/851712>
- Matle I, Mbatha KR, Madoroba E. A review of *Listeria monocytogenes* from meat and meat products: Epidemiology, virulence factors, antimicrobial resistance and diagnosis. *Onderstepoort J Vet Res*. 2020 Oct 9;87(1):e1-e20. doi : 10.4102/ojvr.v87i1.1869. PMID: 33054262; PMCID: PMC7565150.
<https://doi.org/10.4102/ojvr.v87i1.1869>
- Jeffs E, Williman J, Brunton C, Gullam J, Walls T. The epidemiology of listeriosis in pregnant women and children in New Zealand from 1997 to 2016: an observational study. *BMC Public Health*. 2020 January 28; 20(1):116. doi : 10.1186/s12889-020-8221-z. PMID: 31992263; PMCID: PMC6988350.
<https://doi.org/10.1186/s12889-020-8221-z>
- Charlier C, Disson O, Lecuit M. Maternal-neonatal listeriosis. Virulence. December 2020; 11(1):391-397. doi : 10.1080/21505594.2020.1759287. PMID: 32363991; PMCID: PMC7199740.
<https://doi.org/10.1080/21505594.2020.1759287>
- Thomas J, Govender N, McCarthy KM, Erasmus LK, Doyle TJ, Allam M, Ismail A, Ramalwa N, Sekwadi P, Ntshoe G, Shonhiwa A, Essel V, Tau N, Smouse S, Ngomane HM, Disenyeng B, Page NA, Govender NP, Duse AG, Stewart R, Thomas T, Mahoney D, Tourdjman M, Disson O, Thouvenot P, Maury MM, Leclercq A, Lecuit M, Smith AM, Blumberg LH. Outbreak of listeriosis in South Africa associated with processed meat. *N Engl J Med*. 2020 February 13; 382(7): 632-643. doi : 10.1056/NEJMoa1907462. PMID: 32053299; PMCID: PMC7301195.
<https://doi.org/10.1056/NEJMoa1907462>
- Herrador Z, Gherasim A, López-Vélez R, Benito A. Listeriosis in Spain according to hospitalization records, 1997 to 2015: need for greater awareness. *Euro Surveill*. May 2019; 24 (21): 1800271. doi : 10.2807/1560-7917.ES.2019.24.21.1800271. PMID: 31138365; PMCID: PMC6540645.
<https://doi.org/10.2807/1560-7917.ES.2019.24.21.1800271>
- Mylonakis E, Paliou M, Hohmann EL, Calderwood SB, Wing EJ. listeriosis during pregnancy : a case series and review of 222 cases. *Medicine (Baltimore)*. 2002 Jul ;81(4):260-9. doi : 10.1097/00005792-200207000-00002. PMID: 12169881.
<https://doi.org/10.1097/00005792-200207000-00002>
- Lamont RF, Sobel J, Mazaki-Tovi S, Kusanovic JP, Vaisbuch E, Kim SK, Uldbjerg N, Romero R. Listeriosis in human pregnancy: a systematic review. *J Perinat Med*. 2011 May;39(3):227-36. doi : 10.1515/jpm.2011.035. Epub 2011 Apr 25. PMID: 21517700; PMCID: PMC3593057.
<https://doi.org/10.1515/jpm.2011.035>
- Wang Z, Tao X, Liu S, Zhao Y, Yang X. An Update Review on *Listeria* Infection in Pregnancy. *Infect Drug Resist*. 2021 May 26;14:1967-1978. doi : 10.2147/IDR.S313675. PMID: 34079306; PMCID: PMC8165209.
<https://doi.org/10.2147/IDR.S313675>
- McKinney, JS (2016). *Listeria* Infections in Neonates. *NeoReviews*, 17(9), e515-e520. doi:10.1542/neo.17-9-e515
<https://doi.org/10.1542/neo.17-9-e515>
- Satti K, Ali S, Weitkamp J. (2010). Congenital Infections, Part 2: Parvovirus, Listeria, Tuberculosis, Syphilis, and Varicella. *NeoReviews*, 11(12), e681-e695. doi:10.1542/neo.11-12-e681
<https://doi.org/10.1542/neo.11-12-e681>
- Awofisayo A, Amar C, Ruggles R, Elson R, Adak GK, Mook P, Grant KA. Pregnancy-associated listeriosis in England and Wales. *Epidemiol Infect*. 2015 Jan;143(2):249-56. doi : 10.1017/S0950268814000594. Epub 2014 Mar 20. Erratum in: *Epidemiol Infect*. 2015 Jan;143(2):257. Mook, P [added]. PMID: 24650375
<https://doi.org/10.1017/S0950268814000594>
- Thønnings S, Knudsen JD, Schønheyder HC, Søgaard M, Arpi M, Gradel KO, Østergaard C; Danish Collaborative Bacteraemia Network (DACOBAN). Antibiotic treatment and mortality in patients with *Listeria monocytogenes* meningitis or bacteraemia. *Clin Microbiol Infect*. 2016

Publication Consent

The authors have the informed consent of the patient's mother for the publication of the clinical case, as well as for the images presented for academic purposes, safeguarding the confidentiality of the minor.

Conflicts of interest

The authors declare they have no conflicts of interest.

Author Information

Not declared.

Aug;22(8):725-30. doi : 10.1016/j.cmi.2016.06.006. Epub 2016 Jun 23.
PMID: 27345176.

<https://doi.org/10.1016/j.cmi.2016.06.006>

14;20(1):601. doi : 10.1186/s12879-020-05327-6. PMID: 32799811; PMCID:
PMC7429786.

<https://doi.org/10.1186/s12879-020-05327-6>

15. Li C, Zeng H, Ding X, Chen Y, Liu X, Zhou L, Wang X, Cheng Y, Hu S, Cao Z, Liu R, Yin C. Perinatal listeriosis patients treated at a maternity hospital in Beijing, China , from 2013-2018. BMC Infect Dis. 2020 Aug

DOI: Digital Object Identifier. **PMID:** PubMed Identifier. **SU:** Short URL.

Editor's Note

The Revista Ecuatoriana de Pediatría remains neutral regarding jurisdictional claims on published maps and institutional affiliations.
