Relation of Fractionated Atrial Potentials with the Vagal Innervation Evaluated by Extracardiac Vagal Stimulation during Cardioneuroablation

Running title: *Pachon-M et al.; Vagal Dennervation by AF-Nest Ablation*

Enrique I. Pachon-M, MD, PhD[1-3]; Jose Carlos Pachon-Mateos, MD, PhD, CCDS, FHRS, FLAHRS[1-3]; Christian Higuti, MD[1,2]; Tomas G. Santillana-P. MD[1]; Tasso Lobo, MD[1]; Carlos Pachon, MD[1]; Juan Pachon-Mateos, MD, PhD[1-3]; Juan Zerpa, MD[1]; Felipe Ortencio, MD[1]; Ricardo Carneiro Amarante, MD, PhD[1-3]; Ricardo Ferreira Silva, MD, PhD[3]; Osório Thiago Guimarães, MD[4]

[1]Sao Paulo University; [2]Heart Hospital; [3]Dante Pazzanese Cardiology Institute, São Paulo, Brazil; [4]Brussels Universiteit, Brussels, Belgium

Correspondence:

Enrique I Pachon-M, MD, PhD

204 Juquis Street

Ap 61A – Indianopolis

Sao Paulo, SP, Brazil 04081-010

Tel: +55 11 98536 6046

Fax: +55 11 5051 6648

E-mail: epachon@usp.br

Journals Subject Terms: Arrhythmias; Catheter Ablation and Implantable Cardioverter-Defibrillator; Atrial Fibrillation; Electrophysiology

Abstract:

Background: Vagal hyperactivity is directly related to several clinical conditions as reflex/functional bradyarrhythmias and vagal atrial fibrillation (AF). Cardioneuroablation provides therapeutic vagal denervation through endocardial RF ablation for these cases. Main challenges are neuro-myocardium interface identification and the denervation control and validation. The finding that the AF-Nest (AFN) ablation eliminates the atropine response and decreases RR variability suggests that they are related to the vagal innervation.

Method: Prospective, controlled, longitudinal, non-randomized study enrolling 62 patients in two groups: AFN group (AFNG-32 patients) with functional or reflex bradyarrhythmias or vagal AF treated with AFN ablation, and a control group (CG-30 patients) with anomalous bundles, ventricular premature beats, atrial flutter, AV-nodal reentry and atrial tachycardia, treated with conventional ablation (non-AFN ablation). In AFNG, ablation delivered at AFN detected by fragmentation/fractionation of the endocardial electrograms and by 3D anatomical location of the ganglionated plexus. Vagal response was evaluated before, during, and post-ablation by 5s non-contact vagal stimulation at the jugular foramen, through the internal jugular veins (ECVS), analyzing 15s mean heart rate, longest RR, pauses, and AV block. All patients had current guidelines arrhythmia ablation indication.

Results: Pre-ablation ECVS induced sinus pauses, asystole and transient AV block in both groups showing a strong vagal response (p=0.96). Post-ablation ECVS in the AFNG showed complete abolishment of the cardiac vagal response in all cases (Pre/post-ablation ECVS=p<0.0001), demonstrating robust vagal denervation. However, in the CG, vagal response remained practically unchanged post-ablation (p=0.35) showing that non-AFN ablation promotes no significant denervation.

Conclusion: AF-Nest ablation causes significant vagal denervation. Non-AF-Nest ablation causes no significant vagal denervation. These results suggest that AF-Nests are intrinsically related to vagal innervation. ECVS was fundamental to stepwise vagal denervation validation during cardioneuroablation.

Key words: syncope; atrial fibrillation; vagal stimulation; ablation; neurocardiology; cardioneuroablation; extra-cardiac vagal stimulation

Non-standard Abbreviations and Acronyms:

AF	Atrial Fibrillation
AFN	AF-Nest
AFNG	AF-Nest Group
AV	Atrioventricular
CFAEs	Complex Fractionated Atrial Electrograms
CG	Control Group
CAN	Cardioneuroablation
ECVS	Extracardiac vagal stimulation
GP	Ganglionated plexus
Hz	Hertz
PV	Pulmonary Vein
RF	Radiofrequency
RFA	RF ablation
SD	Standard deviation
V	Volts
VA	Ventriculo-atrial

Introduction

Several clinical conditions in patients without significant structural heart disease, featured by reflex or persistent bradyarrhythmia, are directly related to vagal hyperactivity. These include vasovagal cardioinhibitory or mixed syncope[1], vagal atrial fibrillation[2], carotid sinus syndrome[3], sinus node dysfunction[4], situational syncope[5], bradytachycardia syndrome[6], and exercise training-induced bradycardia[7,8].

At rest, the vagus nerve imposes a permanent inhibitory tone on the heart whose pharmacological or surgical suppression promotes an immediate and persistent increase in sinus rate[9]. The first study describing and proposing the cardioneuroablation (CNA) was published in 2005, a kind of catheter vagal denervation, for treatment of functional bradyarrhythmias[10]. A cohort of twenty-one patients with neurally mediated reflex syncope, functional high-grade atrioventricular block or sinus node dysfunction was treated by catheter RF ablation (RFA) based on AF-Nests (AFN) mapping. In a mean of 9.2 months, all cases had no symptom recurrence. Nowadays, there is a growing interest in the cardiac vagal innervation and endocardial ablation regarding the possibility of achieving therapeutic denervation. The aim is to eliminate visceral vagal neurons in the atrial walls and ganglionated plexus (GPs), abolishing or attenuating the cardioinhibitory reflex and/or the vagal inhibitory tonus.

Crucial challenges are to identify the main innervation entry and to measure the amount and progression of the vagal denervation.

Vagal Innervation Entry

In the nineties, it was observed that ablation of AF-Nests[11], a kind of atrial myocardium with disconnected cells, resulted in vagal denervation, reducing dramatically the heart rate variability

and making the heart nonresponsive to atropine[10,12]. Therefore, in 2005 it was published the first study describing the CNA by ablating the AFN, mainly the ones overlapping the main GPs[10].

Spectral study has shown that AF-Nest is composed of electrically poor-connected myocardium (fibrillar myocardium) probably interpolated with visceral neurons. This blend, changes the electrical activation properties, better displayed by spectral analysis[11,13,14,15]. Several authors have been reproducing these findings[16,17,18,19,20]. AF-Nest can be identified by spectral mapping, by filter adjustments of conventional recorders and recently by fractionation software. Currently, the electroanatomic location of GPs[21], supported by AF-Nests tagged with Fractionation Mapping or on-line Spectral mapping[10,11,18,22] seem to be the best alternatives in terms of celerity, specificity, feasibility, and efficiency for CNA, Figure 1.

The cardiac nervous system, unlike the innervation of the skeletal muscle, has a ganglion between the central nervous system and the heart, located in the paravertebral sympathetic chain, in the sympathetic, or in the heart (GPs and atrial myocardium), in the parasympathetic system, Figure 1. This exquisite model has the parasympathetic postganglionic neural body in the atrial wall and in the epicardial GPs, Figure 1, while the sympathetic and sensory systems have their neural bodies far from de heart, protected from the RF, Figure 1A. This remarkable distribution is the CNA keystone as it directly allows to eliminate the postganglionic parasympathetic neural bodies whereas predominantly ablates only axonal fibers of the sympathetic and sensory systems, Figure 1-A. Abolition of the body cell is essential for long-term denervation reducing the reinnervation probability[23,24]. The exclusive elimination of the sympathetic and sensory fibers preserving their neural body allows significant reinnervation, as it can be observed for example, in the transplanted heart[25]. Beyond the atrial wall, high number of parasympathetic neural bodies are located in the GPs that can be 3 to 7, four of them the most prevalent[26,27,28,29]: GP 1, between

the superior vena cava and aortic root just above the right upper pulmonary vein; GP 2, between the right upper pulmonary vein and the right atrium; GP 3, between the inferior vena cava and the right and left atrium and GP 4, at the insertion of the left pulmonary veins[30], Figure 1-B. These ganglia may be transmurally ablated by endocardial RF depending on the position and thickness of the atrial wall, especially when using irrigated catheters that reach deeper ablation[31].

Objective

To verify whether AF-Nest ablation promotes vagal denervation compared to a control group submitted to non-AFN ablation.

Methods

The authors declare that all supporting data are available within the article.

This is a prospective, longitudinal controlled, non-randomized study, consisting of two groups: AF-Nest Group (AFNG) with 32 patients undergoing vagal denervation for treatment of functional bradyarrhythmias or vagal atrial fibrillation, based on AF-Nest ablation, and a Control Group (CG) consisting of 30 patients undergoing conventional ablation not targeting AF-Nest ablation. All patients had symptomatic arrhythmias non-responsive to medical treatment and were excluded if they had structural cardiac, cardiopulmonary diseases or NYHA Heart Failure Class > I; cerebrovascular diseases or medication or metabolic related syncope. The study was approved by the University Post-Graduation Ethics Committee. Written informed consent was obtained from all patients. Both groups underwent the same procedures for preparation, anesthesia, monitoring, and recovery, performed in the same laboratory, with the same medical team. The only difference between groups, besides the arrhythmia, was the RF sites targeting (AFNG) or not-targeting AF-Nests (CG).

Electrophysiological procedure

All the patients underwent orotracheal intubation and general intravenous anesthesia controlled by BIS (Brain Index Spectral®). Parasympatholytic drugs were proscribed. A conventional recorder and NAVX-Ensite® Velocity St Jude electroanatomic mapping system were installed. The catheters were deployed under pulsed radioscopy by femoral vein using the Seldinger technique. A duodecapolar catheter was deployed in the coronary sinus. One quadripolar catheter was advanced through superior vena cava and internal jugular vein up to the jugular foramen to allow extracardiac non-contact vagal stimulation throughout the ablation. Left atrium was accessed by transseptal puncture. A decapolar circular catheter was used to get the 3D anatomical model, simultaneously achieving fractionation map. AF-Nest mapping and ablation were proceeded by an irrigated RF St Jude Flexability catheter. Coagulation activated time between 300 to 400s was maintained by adjusting intravenous heparin infusion.

Extracardiac Vagal Stimulation (ECVS)

The vagal denervation extent was evaluated by stepwise ECVS[32]. In this technique, vagal stimulation (Figure 2) is obtained without dissection or contact with the vagus nerve. A quadripolar electrode is advanced by the superior vena cava and internal jugular vein, up to the jugular foramen, Figure 2-B,C. Usually, in this place, there is close proximity to the vagus nerve. ECVS is attained by pulsed electric field (pulse amplitude of 1V / kg body weight up to 70V, 50 microseconds width, 50Hz frequency during 5 seconds) within the jugular vein[32], Figure 2-A. Typical response is transitory asystole and/or AV block, Figure 2-D,E,F.

The ECVS was performed before ablation to record the basal response, during the procedure for guiding the denervation progression, and at the end to confirm the endpoint.

Mapping of AF-Nests

An initial AF-Nests map was obtained during anatomy acquisition with the Ensite Velocity system using the Fractionation Software, Figure 3. Subsequently, by using the ablation lead, the tagged locations and the regions overlapping the GPs were explored with conventional endocardial mapping searching for fragmented potentials as shown in Figure 3 by using a 30 to 500Hz and a 300 to 500Hz filtered channels.

AF-Nest Group

Transesophageal echocardiography was used to exclude thrombus, to look for patent oval foramen, to guide transseptal puncture, to evaluate anatomy and for thermal esophagus protection by mechanical deviation[33]. AF ablation was performed in four steps: 1. AF-Nest ablation at the antrum of pulmonary veins; 2. AF-Nest ablation outside the antrum of PVs (posterior septal region, left and right atrial septum and superior vena cava); 3. Ablation of residual tachycardias if induced at the end of the procedure (atrial and background tachycardias[34]) and 4. Completion of vagal denervation. After each step, a new ECVS was performed to verify the denervation progression. The Figure 4-B shows the AF-Nests locations related to GPs 1, 2, 3 and 4. The GP2 region is the most extensive and was ablated by the left atrium, essentially in the interatrial septum, right PV vein antrum and P point (triangular area between right PV insertion, left atrial roof and fossa ovalis) and by the right atrium between the base of the superior vena cava and the fossa ovalis. The AF-Nests of the GP3 region were accessed from the right atrium in the coronary sinus ostium and, additionally, to the upper medial portion of the inferior vena cava and also, through the left atrium ablating the left posterior septal region and the coronary sinus roof. The GP4 area was approached by the left atrium in the left superior PV antrum. GP1 ablation was the last, approached by the right atrium in the

inferomedial portion of the superior vena cava. The patients were evaluated in the first 24 hours and after the 2nd, 6th and 12th month. The arrhythmias treated in this group are plotted in Table 1.

Control Group

This group was submitted to conventional ablation for treating the arrhythmias listed in Table 1. Transseptal approach was not necessary. Ablations were performed in the ventricular wall in the case of ventricular arrhythmias and anomalous pathways, or at specific atrial focus in the other cases without targeting AF-Nests. Before and after the ablations, ECVSs were performed and the responses were recorded.

Statistical analysis

Quantitative data are shown as the mean value ± standard deviation (SD). Normality was assessed by the Shapiro-Wilk test. Paired or unpaired samples were applied with a two-tailed t-test to establish comparisons between continuous paired data before and after ablation. All values were considered statistically significant with a two-tailed p value <0.05.

Results

The patients were sequentially enrolled according to the arrival and appropriate clinical indication for each group. In the AFNG there were ablated a mean of 33.6±13 AF-Nest per patient in a mean of 14.5±3.5 minutes of radioscopy. There was no statistical difference between the AFNG and the CG patients when compared age (p=0.20), left atrial size (p=0.27) and ejection fraction (p=0.25). Male gender prevailed in both groups (78%, p=0.04), Table 1. ECVS was obtained in all patients in a mean of 3.4±2.7 minutes with 0.4±0.8 minutes of radioscopy. In 3 patients (4.8%) there was some difficulty for catheter deployment due to anatomical variations

of the venous system. The mean ECVS amplitude was 67.3±5.5V; 68.7±4V in the AFNG and 65.9±6.5V in the CG, (p = 0,04). The ECVS pulse amplitude in AFNG was slightly higher, considering the higher body weight in this group, Table 1. Initial ECVS caused asystole by sinus arrest and AV block in both groups. In one patient (0.62%), ECVS of the right vagus produced incomplete AV block with sinus bradycardia, however, ECVS in the left one achieved sinus arrest followed by total transient AV block.

Before ablation, ECVS caused intense vagal response similar in the two groups (p=0.96), however it was completely abolished after ablation only in the AFNG. The vagal response after ablation remained almost identical to the initial response in the CG (p=0.35). The absence of vagal response in AFNG after ablation produced a huge statistical difference between groups (p<0.000). There were no complications related to ablations and ECVS during the procedures and throughout the follow-up period.

Comparison between pre and post ablation vagal pauses in the AFNG was highly significant, $p < 0.001$, while in the CG the same assessment did not reach significance (p=0.35). Four AFNG patients (12.5%) had some residual vagal response at the end of the procedure, which was abolished by additional AF-Nests ablation in the Waterston´s groove and GP4 area in the same session. Pre and post ablation vagal pauses are shown in Table 2.
Mean of vagal pauses for each ablation step in the AFNG are shown in Figure 4.

As expected, vagal denervation increased the sinus rate and the most significant rise (p<0.000) resulted from ablation of the left interatrial septum between the right pulmonary veins insertion and the fossa ovalis, an area with a strong effect on sinus P cells automatism ("P point"), Figure 4. There were no residual or side effects related to vagal stimulation during the procedures and throughout the follow-up.

After one-year, only 6.2% of AF patients in the AFNG group had AF recurrence that was clinically treated without the need for reablation. There was no recurrence of bradyarrhythmias.

Discussion

Considering that the parasympathetic tone is permanently inhibitory, vagal denervation may be highly beneficial for treating several clinical conditions such as reflex bradyarrhythmias, functional bradyarrhythmias and vagal AF. The cardioneuroablation proposed vagal denervation through endocardial catheter ablation, Figure 5-B,C. Acute denervation may also result from fibers elimination, however, for a long-term denervation neural bodies elimination is essential, as the axon fibers rapidly regenerate[25]. The main questions are the neuro-myocardial interface mapping and the strategy to measure the resulting denervation.

Cardioneuroablation Rationale

The location of parasympathetic postganglionic neural bodies in the atrial walls and epicardial GPs[29] (Figure 1) makes them more vulnerable to RF. Therefore, the CNA achieves, predominantly, parasympathetic denervation since most of the sympathetic and sensory fibers recover naturally in a short time[25]. Their neural bodies, located away from the heart in the paravertebral chain, are protected from the endocardial RF energy, Figure 1-A. This remarkable organization creates the conditions for a rather selective endocardial ablation that can be suitable in the treatment of functional bradyarrhythmias[35,36,37,38] neurocardiogenic cardioinhibitory syncope and vagal atrial fibrillation[39].

Origin and Mapping of AF Nests

It was observed in the initial study that AF-Nests were probably related to the neuro-myocardial interface in normal hearts[11], however there was not a specific study addressing this question.

This perception was based on the spectral AF-Nest properties (Figure 5-A) and on the observation that the AF-Nest ablation made the heart unresponsive to atropine and caused a pronounced and persistent RR variability reduction[10]. The neural fibers entry into the atrial wall alters the electrical contact among myocardial cells. The combination of poorly connected cells mixed with neural fibers changes the spectral properties of the atrial electrical potential featuring the fibrillar myocardium and the AF-Nests, Figure 3. They were identified in sinus rhythm, also characterized by fractionated endocardial potentials, most visible by using bandpass filter from 300 to 500 Hz[11,13], on-line spectral mapping or by 3D mapping (Ensite-Velocity Fractionation Software), Figure 3 and Figure 5. Higher AF-Nest density overlaps the GP locations and PV antrum, as described in the first study reproduced by several authors[10,18,22].

AF-Nests Ablation and Denervation

Initial ablations were targeted to the AF-Nests overlapping the GP 2, 1, and 3, Figure 1-B. After this step, if ECVS still demonstrated vagal response, the GP 4 area and the Waterston's groove were treated in addition to new AF-Nests mapped and ablated in both atria up to complete vagal response elimination. The GPs[26,30,40] are located in the atrial epicardium, and can be reached by endocardial RF, especially by using irrigated catheter that causes deeper lesions[41]. An interesting data described in the initial studies and reproduced in this paper was the identification of the so-called "P point", a trigone in the left interatrial septum, which base is the insertion of the right pulmonary veins to the ceiling of the left atrium, extending to the fossa ovalis, Figure 3. This area typically has numerous AF-Nests and its ablation causes a rapid and significant sinus rate increase, being an essential target in Cardioneuroablation[10,42], Figure 4. Immunohistochemistry by acetylcholinesterase staining[43], demonstrated high density of intraparietal neurons in this interatrial septum zone given rise to high number of fibers that innervate the sinus node[44].

With small variations, the sinus rate increase by P point ablation was proportional and reproducible in all patients of the AFNG producing the most significant sinus rate rise and vagal pauses elimination observed in the baseline ECVS, Figure 4, Figure 5, and Figure 6. Additional findings showed that the ablation at the antrum of left pulmonary veins, postero-septal space and coronary sinus ostium, despite producing less sinus effect, preferentially caused more AV node denervation, correcting and/or increasing the Wenckebach's point. These findings suggest that, regardless of the interconnection of the two vagus, there is some lateralization, therefore cardioneuroablation could be tailored according to the need of each case, seeking for improving sinus automatism and/or AV node dromotropism[22,45,46,47].

Extracardiac Vagal Stimulation

In this study, the ECVS had a fundamental role by allowing the denervation assessment at each step of the procedure without surgical access to the vagus nerve. Additionally, it caused no residual effect, injury or functional detriment to the patients, being also possible to be repeated for stepwise ablation control, showing to be highly reproducible, Figure 6. The ECVS was feasible in all patients. Some difficulty of accessing the right internal jugular vein due to anatomical variation occurred in 3 cases (4.8%). However, change of the position of the patient's head, Tremdelemburg maneuver, the insertion of a long guide or the contralateral access, solved the problem. Difficulty was progressively reduced with operator training. In the control group, ECVS was also very useful for evaluating AV and VA anomalous pathways conduction, allowing us to confirm its elimination by ablation, Figure 2-D,E,F.

Denervation

The AF-Nests ablation caused significant parasympathetic denervation, demonstrated by the complete elimination of the vagal response induced by ECVS, Figure 6 and Figure 7. In the

AFNG, 4 patients (12.5%) had residual vagal response corrected by additional AF-Nest ablation. This was possible due to the transient nature of ECVS that allows it to be repeated in a few minutes, Figure 2-D,E,F. The same would not be possible with atropine whose action lasts for several hours[48], preventing the subsequent reassessment of the vagal response. Consistent denervation in the AFNG and absence of denervation in the CG were the most important findings of this study. These observations reinforce the supposition that the AF-Nests are related to the cardiac vagal innervation since their ablation eliminated the vagal response in all patients of the AFNG. In the CG, non-NFA ablation did not change the vagal response at all, Figure 7 and Figure 4. This study also suggests that to obtain a complete and consistent denervation, it is necessary to approach the right and left atria as significant denervation targets were identified in both chambers.

AF-Nests versus Complex Fractionated Atrial Electrograms (CFAEs)

It is appropriate to consider the differences between AF-Nests and CFAEs ablation. AF-Nests are featured in sinus rhythm only, while CFAEs are characterized during atrial fibrillation. During AF, part of the high frequencies of CFAEs is caused by a large number of collisions, creating a virtual spectrum and reducing the specificity of AFN mapping. This fact was well studied in the article of Oh S et al. that concluded "CFAE sites were not the same as the AF nests in this animal model of vagally mediated AF. Therefore, these two types of ablation methods appear to target different substrates of AF"[49].

Epicardial Ablation of Ganglionated Plexus

Endocardial ablation of the areas overlapping GPs was described in the original article of Cardioneuroablation in 2005[10]. With different purpose, in 2009 Nakagawa et al. showed that epicardial and endocardial ablation of GPs could contribute to AF ablation outcome[50]. However,

this study reinforced the value of vagal denervation in the treatment of AF. In the present study, we sought to enhance endocardial denervation because it is less invasive.

Limitations

As the vagus nerve and surrounding tissues have a large amount of sensory fibers, ECVS must only be performed under general anesthesia to avoid discomfort. We have been using general anesthesia controlled by Brain Index Spectral to keep the lowest depression of the autonomic reflexes.

ECVS should not be performed with generic stimulators because of tissue injury risk. Accurate control of amplitude, frequency, duty cycle, pulse width, current and output impedance are absolutely necessary for safety, efficiency and reproducibility of the procedure.

Properly AF-Nests identification may be more difficult and less specific in the absence of electrograms filtering, fractionation software and/or in the absence of spectral mapping.

Certain patients may have anatomical variations precluding unilateral access to the jugular foramen. Usually, the contralateral access solves this difficulty.

Conclusions

Catheter endocardial AF nests ablation causes almost complete vagal denervation demonstrating that these structures are related to the cardiac parasympathetic innervation. A non-AF-Nests ablation does not modify the vagal response. The extracardiac vagal stimulation showed to be very practical, objective, and reproducible for immediate evaluation of the vagal denervation, constituting an essential resource for the endpoint of procedures that seek vagal effect attenuation.

Sources of Funding: None

Disclosures: None.

References:

1. Chen-Scarabelli C, Scarabelli TM. Neurocardiogenic syncope. *BMJ*. 2004;329:336-41. Review.

2. Carpenter A, Frontera A, Bond R, Duncan E, Thomas G. Vagal atrial fibrillation: What is it and should we treat it? *Int J Cardiol.* 2015;201:415-21.

3. Amin V, Pavri BB. Carotid sinus syndrome. *Cardiol Rev*. 2015;23:130-4.

4. de Marneffe M, Gregoire JM, Waterschoot P, Kestemont MP. The sinus node and the autonomic nervous system in normals and in sick sinus patients. Acta Cardiol. 1995; 50:291-308.

5. Wenzke KE, Walsh KE, Kalscheur M, Wasmund SL, Page RL, Brignole M, Hamdan MH. Clinical Characteristics and Outcome of Patients with Situational Syncope Compared to Patients with Vasovagal Syncope. *Pacing Clin Electrophysiol*. 2017;40:591-595.

6. Kaplan BM, Langendorf R, Lev M, Pick A. Tachycardia-bradycardia syndrome (so-called "sick sinus syndrome"). Pathology, mechanisms and treatment. *Am J Cardiol*. 1973;31:497-508.

7. Besnier F, Labrunée M, Pathak A, Pavy-Le Traon A, Galès C, Sénard JM, Guiraud T. Exercise training-induced modification in autonomic nervous system: An update for cardiac patients. *Ann Phys Rehabil Med*. 2017;60:27-35.

8. Billman GE, Cagnoli KL, Csepe T, Li N, Wright P, Mohler PJ, Fedorov VV. Exercise training-induced bradycardia: evidence for enhanced parasympathetic regulation without changes in intrinsic sinoatrial node function. *J Appl Physiol*. 2015;118:1344-55.

9. Jose AD. Effect of combined sympathetic and parasympathetic blockade on heart rate and cardiac function in man. *Am J Cardiol*. 1966;18:476–478.

10. Pachon JC, Pachon EI, Pachon JC, Wolf TJ, Pachon MZ, Vargas RN, Jatene AD. "Cardioneuroablation" - new treatment for neurocardiogenic syncope, functional AV block and sinus dysfunction using catheter RF-ablation. *Europace.* 2005;7:1-13.

11. Pachon M JC, Pachon M EI, Pachon M JC, Wolf TJ, Pachon MZ, Vargas RN, Pachon DQ, Lopez M FJ, Jatene AD. A new treatment for atrial fibrillation based on spectral analysis to guide the RF-ablation catheter. *Europace*. 2004;6:590-601.

12. Pachon JC, Pachon EI, Cunha Pachon MZ, Wolf TJ, Pachon JC, Santillana TG. Catheter ablation of severe neurally meditated reflex (neurocardiogenic or vasovagal) syncope: cardioneuroablation long-term results. *Europace*. 2011;13:1231-42.

13. Pachon, José Carlos and Pachon, Enrique I., inventors; Apparatus and Methods for Arrhythmia Treatment Based on Spectral Mapping During Sinus Rhythm; United States patent. US20110098699 A1. 2011.

14. Chang HY, Lo LW, Lin YJ, Lee SH, Chiou CW, Chen SA. Relationship between intrinsic cardiac autonomic ganglionated plexi and the atrial fibrillation nest. *Circ. J*. 2014;78:922-8.

15. Mateos JC, Mateos EI, Lobo TJ, Pachón MZ, Mateos JC, Pachón DQ, Vargas RNA, Piegas LS, Jatene AD. Radiofrequency catheter ablation of atrial fibrillation guided by spectral mapping of atrial fibrillation nests in sinus rhythm. *Arq Bras Cardiol*. 2007;89:124-34, 140-50.

16. Oh S, Kong HJ, Choi EK, Kim HC, Choi YS. Complex fractionated electrograms and AF nests in vagally mediated atrial fibrillation. *Pacing Clin Electrophysiol*. 2010;33:1497-503.

17. Yenn- Jiang Lin, Shih-Lin Chang, Li-Wei Lo, Shih-Ann Chen-Mapping of the Atrial Electrogram in Sinus Rhythm and Different Atrial Fibrillation Substrates. Shenasa M, Hindricks G, Borggrefe M, Breithardt G. Cardiac Mapping, Wiley-Blackwell 4th Edition, 2013; 323-338.

18. Arruda M, Natale A. Ablation of permanent AF: adjunctive strategies to pulmonary veins isolation: targeting AF NEST in sinus rhythm and CFAE in AF. *J Interv Card Electrophysiol.* 2008;23:51-7.

19. Yao Y, Shi R, Wong T, Zheng L, Chen W, Yang L et al. Endocardial autonomic denervation of the left atrium to treat vasovagal syncope: an early experience in humans. *Circ Arrhythm Electrophysiol.* 2012;5:279-86.

20. Verheule S, Wilson EE, Arora R, Engle SK, Scott LR, Olgin JE - Tissue structure and connexin expression of canine pulmonary veins. *Cardiovasc Res*. 2002;55:727-738.

21. Aksu T, Guler TE, Mutluer FO, Bozyel S, Golcuk SE, Yalin K. Electroanatomic-mapping-guided cardioneuroablation versus combined approach for vasovagal syncope: a cross-sectional observational study. *J Interv Card Electrophysiol.* 2019;54:177-188.

22. Rivarola E, Hardy C, Sosa E, Hachul D, Furlan V, Raimundi F, Scanavacca M. Selective atrial vagal denervation guided by spectral mapping to treat advanced atrioventricular block. *Europace*. 2016;18:445-9.

23. Arrowood JA, Goudreau E, Minisi AJ, Davis AB, Mohanty PK. Evidence against reinnervation of cardiac vagal afferents after human orthotopic cardiac transplantation. *Circulation*. 1995;92:402e8.

24. Sakamoto S, Schuessler RB, Lee AM, Aziz A, Lall SC, Damiano RJ Jr. Vagal denervation and reinnervation after ablation of ganglionated plexi. *J Thorac Cardiovasc Surg*. 2010;139:444-52.

25. Beitzke D, Wielandner A, Wollenweber T, Vraka C, Pichler V, Uyanik-Uenal K, Zuckermann A, Greiser A, Hacker M, Loewe C. Assessment of sympathetic reinnervation after cardiac transplantation using hybrid cardiac PET/MRI: A pilot study. *J Magn Reson Imaging*. 2019; 20.

26. Pauza DH, Skripka V, Pauziene N, Stropus R. Morphology, distribution and variability of the epicardial neural ganglionated subplexuses in the human heart. *Anat Rec*. 2000;259:353-382.

27. Van Stee EW. Autonomic Innervation of the Heart. *Environ Health Perspect*. 1978;26:151-8.

28. Lazzara R, Scherlag BJ, Robison MJ, Samet P. Selective in situ parasympathetic control of the sinoatrial canine and atrioventricular nodes. *Circ Res*. 1973;32:393-401.

29. Armour JA, Murphy DA, Yuan BX, Macdonald S, Hopkins DA. Gross and Microscopic Anatomy of the Human Intrinsic Cardiac Nervous System. *The Anatomical Record.* 1997;247:289–298.

30. Chiou CW, Eble JN, Zipes DP. Efferent vagal innervation of the canine atria and sinus and atrioventricular nodes. The third fat pad. *Circulation*. 1997;95:2573-84.

31. Dorwarth U, Fiek M, Remp T, Reithmann C, Dugas M, Steinbeck G, Hoffmann E. Radiofrequency catheter ablation: different cooled and noncooled electrode systems induce specific lesion geometries and adverse effects profiles. *Pacing Clin Electrophysiol*. 2003;26:1438-45.

32. Pachon M JC, Pachon M EI, Santillana P TG, Wolf TJ, Pachon CTC, Pachon M JC et al. Simplified method for vagal effect evaluation in cardiac ablation and electrophysiological procedures. *JACC Clin Electrophysiol*. 2015;1:451-60.

33. Mateos JC, Mateos EI, Peña TG, Lobo TJ, Mateos JC, Vargas RN, Pachón CT, Acosta JC. Simplified method for esophagus protection during radiofrequency catheter ablation of atrial fibrillation - prospective study of 704 cases. *Rev Bras Cir Cardiovasc*. 2015;30:139-47.

34. Pachón-M JC, Pachón-M EI, Santillana P TG, Lobo TJ, Pachón CTC, Pachón-M JC, Albornoz V RN, Zerpa A JC, Ortencio F, Arruda M. Ablation of "Background Tachycardia" in Long Standing Atrial Fibrillation: Improving the Outcomes by Unmasking a Residual Atrial Fibrillation Perpetuator. *J Atr Fibrillation*. 2017;10:1583.

35. Pachon M JC, Pachon M EI, Lobo TJ, Pachon M JC, Pachon MZ, Vargas RN, Manrique RM, Jatene AD. Syncopal high-degree AV block treated with catheter RF ablation without pacemaker implantation. *Pacing Clin Electrophysiol.* 2006;29:318-22.

36. Rebecchi M, de Ruvo E, Strano S, Sciarra L, Golia P, Martino A, Calo L. Ganglionated plexi ablation in right atrium to treat cardioinhibitory neurocardiogenic syncope. *J Interv Card Electrophysiol*. 2012;34:231–235.

37. Aksu T, Guler TE, Bozyel S, Yalin K. Potential usage of cardioneuroablation in vagally mediated functional atrioventricular block. *SAGE Open Med*. 2019;15;7:2050312119836308.

38. Piotrowski R, Baran J, Kułakowski P. Cardioneuroablation using an anatomical approach: a new and promising method for the treatment of cardioinhibitory neurocardiogenic syncope. *Kardiol Pol.* 2018;76:1736-1738.

39. Sutton R, Lim PB. Cardioneuroablation: Present status as a tenable therapy for vasovagal syncope. *Turk Kardiyol Dern Ars*. 2019;47:1-3.

40. Randall WC, Milosavljevic M, Wurster RD, Geis GS, Ardell JL. Selective vagal innervation of the heart. *Ann Clin Lab Sci*. 1986;16:198-208.

41. Dorwarth U, Fiek M, Remp T, Reithmann C, Dugas M, Steinbeck G, Hoffmann E. Radiofrequency catheter ablation: different cooled and noncooled electrode systems induce specific lesion geometries and adverse effects profiles. *Pacing Clin Electrophysiol*. 2003;26:1438-45.

42. Rivarola EW, Hachul D, Wu T, Pisani C, Hardy C, Raimundi F, Melo S, Darrieux F, Scanavacca M. Targets and End Points in Cardiac Autonomic Denervation Procedures. *Circ Arrhythm Electrophysiol.* 2017;10:e004638.

43. Pauza DH, Rysevaite-Kyguoliene K, Vismantaite J, Brack KE, Inokaitis H, Pauza AG, Rimasauskaite-Petraitienė V, Pauzaite JI, Pauziene N. A combined acetylcholinesterase and immunohistochemical method for precise anatomical analysis of intrinsic cardiac neural structures. *Ann Anat*. 2014;196:430-40.

44. Pauza DH, Pauziene N, Pakeltyte G, Stropus R. Comparative quantitative study of the intrinsic cardiac ganglia and neurons in the rat, guinea pig, dog and human as revealed by histochemical staining for acetylcholinesterase. *Ann Anat*. 2002;184:125-36.

45. Aksu T, Baysal E, Guler TE, Yalın K. Selective right atrial cardioneuroablation in functional atrioventricular block. *Europace*. 2017;19:333.

46. Fukunaga M, Wichterle D, Peichl P, Aldhoon B, Čihák R, Kautzner J. Differential effect of ganglionic plexi ablation in a patient with neurally mediated syncope and intermittent atrioventricular block. *Europace*. 2017;19:119-126.

47. Klank-Szafran M, Stec S, Sledź J, Janion M. Radiofrequency ablation and cardioneuroablation for AVNRT and atrioventricular block. *Kardiol Pol.* 2010;68:720-4.

48. Leier CV, Johnson TM, Hashimoto H, Schaal SF. Effects of Commonly Used Cardioactive Drugs on Atrial and Sinoatrial Conduction in Man. *J Cardiovasc Pharmacol*. 1980;2:553-566.

49. Oh S, Kong HJ, Choi EK, Kim HC, Choi YS. Complex fractionated electrograms and AF nests in vagally mediated atrial fibrillation. *Pacing Clin Electrophysiol*. 2010;33:1497-503.

50. Nakagawa H, Scherlag BJ, Patterson E, Ikeda A, Lockwood D, Jackman WM. Pathophysiologic basis of autonomic ganglionated plexus ablation in patients with atrial fibrillation. *Heart Rhythm*. 2009;6:S26-34.

Table 1: Demographic parameters, arrhythmias and procedures in each group

	AF Nest Group	Control Group	N°	*p*
Patients	32	30	62	-
Gender (M/F)	23/9	16/14	39/23	0.04
Age	50.5 ± 17	44.6 ± 15.6	47.7 ± 16.4	0.20
Left Atrium (mm)	40.2 ± 9.1	36.4 ± 4.4	38.9±7.9	0.27
EF (Teicholz)	64.4 ± 8.8	66.8 ± 6.23	65.4±7.7	0.25
Weight (Kg)	83.1 ± 13.9	76 ± 17.7	79.7 ± 16.1	0.08
Pulsed Radioscopy (minutes)	14.5± 3.5	6.6 ± 3.7	10.6 ± 5.3	<0.00
Number of Ablated AF-Nest/patient	33.6 ± 13	---	---	---
Duration (H:MM)	3:42 ± 56	3:13 ± 44	3:28 ± 16	0.025
Arrhythmia Type	Paroxysmal AF	-	16-50%	-
	Persistent AF	-	14-44%	-
	Functional Bradycardia	-	2-6%	-
	-	Nodal Reentry	10-34%	-
	-	Ventricular Extrasystoles	6-20%	-
	-	WPW Syndrome	6-20%	-
	-	AV Reentry	4-13%	-
	-	Atrial Flutter	3-10%	-
	-	Atrial tachycardia	1-3%	-

Table 2: Pauses induced by ECVS pre and post-CNA in both groups

	AF Nest Group	Control Group	*p*
Heart rate before ablation	62.5 +/- 19 bpm	66.9 +/- 11.1 bpm	0.27
15 sec Mean Atrial Rate During Neural Stimulation	31 +/- 13.2 bpm	36.7 +/- 16.8 bpm	0.06
15 sec Mean Ventricular Rate During Neural Stimulation	29.2 +/- 13.6 bpm	36.7 +/- 16.8 bpm	0.06
Pre-Procedure Pause	8370 +/- 2727 ms	6899 +/- 3019 ms	0.96
Post-Procedure Heart Rate	72 +/- 12.9 bpm	67.6 +/- 9 bpm	0.51
Post-Procedure Pause	0	5971 +/- 2724ms	<0.00
***p* pause pre and post**	<0.00	0.35	-

Figures Legends:

Figure 1A: Draft of the autonomic cardiac nervous system with the three main innervation partitions; RF: endocardial RF effect limit; 1: parasympathetic postganglionic neural bodies unrecoverable after RF; 2 and 3: fibers of the sympathetic and sensory systems that usually recover after RF. Different from the sympathetic and sensory systems, whose bodies are far from the heart, the postganglionic parasympathetic neural body is over or inside the atrial wall and susceptible to be eliminated by the endocardial RF energy resulting in more extensive and lasting denervation. **B:** Scheme of the main ganglionated plexus location that may be transmurally ablated from the endocardium (see text for explanation).

Figure 2: Above: Scheme of the Extracardiac Vagal Stimulation (ECVS) used to detect the integrity of pre-ablation vagal innervation and post-ablation vagal denervation. A: Neurostimulator; B: Stimulation catheter within the internal jugular vein; C: cross-section scheme of the neck showing the great proximity of the vagus nerve to the internal jugular vein and to the carotid artery. Below: EKG showing immediate cardiac response to ECVS (asystole D, E, F) and its reproducibility at repetitive one-second vagal stimulation (*).

Figure 3: Several AF-Nest mapping systems: A: AF-Nest potential featured in a regular recorder with conventional filtering setup; B: LA electroanatomical model obtained by the Velocity system. The yellow dots are fractionated potentials detected automatically by the software. The red dots are RF applications in the left-superior interatrial septum area ("P point"). C: Compact

myocardium potential with conventional filter of 30 to 500Hz. D and E show respectively the spectra of AF-Nest and compact myocardium.

Figure 4: Mean and standard deviation of maximum RR duration induced by ECVS (15 seconds from the ECVS start) at every step of the ablation in AFNG and CG. In the AFNG there is a progressive reduction of maximum RR duration at every step up to the abolishment of any vagal pause. The most significant maximum RR reduction occurred after ablation of the P-Point area. In the CG, the vagal response did not change significantly with ablation; CNA: cardioneuroablation; Abl: conventional ablation; LPV: left pulmonary veins; LPS: left postero-septal area; RA: right atrium; P-Point: trigone from right pulmonary veins up to fossa ovalis; AFNG: group undergoing ablation of the AF-Nests; CG: group undergoing non-AF-Nest ablation. Units showed in milliseconds.

Figure 5: Ablation of an AFNG patient with symptomatic functional bradycardia. In A, B and C there are typical AF-Nests identified by the fragmentation observed in the filtered time domain recordings (30-500Hz and 300-500Hz). A typical-high frequency signal is displayed in channel 2 (circle). D and E are continuous recordings during RF application in the AF-Nest showed in C, at the P-Point. The RF started on the right-upper recording D and was maintained until the end of E. Note the gradual rate increase from 42bpm to 81bpm, as a result of the acute vagal denervation. LIA: left interatrial; RA: Right atrium; RF: radiofrequency ablation. Source: SEMAP database.

Figure 6: 5-second ECVS recordings collected during stepwise ablation in one AFNG patient. In A, the ECVS at the beginning of the procedure, before any ablation. In B, ECVS after AF-Nest ablation in the antra of the left pulmonary veins. In C, ECVS after the AF-Nest ablation on the posterior septal space (there is junctional escape rhythm that starts at the vertical dash line until the end of the tracing). In D, the ECVS was performed after AF-Nest ablation on the antra of right PVs and in E, ECVS after right atrium ablation. The sinus rate is displayed in each recording showing denervation progress.

Figure 7: Above, recordings of an AFNG patient before and after AF-Nests ablation. ECVS (shadow square) was applied during 5s causing a pause of 11.3s consisting of the ECVS length plus a period of 6.3s cardiac vagal recovery time. After ablation, similar ECVS produced no vagal pause during or after the stimulation. Below, recordings of a CG patient before and after successful non-AFN ablation (ventricular ectopic beats). Before ablation, 5s ECVS caused a pause of 6.6s. After ablation, a new 5s ECVS induced again a similar asystole of 7.8s showing no vagal denervation by non-AFN ablation. This result also shows the ECVS reproducibility. Dashed lines define the 15s period that was considered to measure the average heart rate resulting from the ECVS.

What is known?

- Numerous clinical conditions with apparently normal heart are caused by persistent or reflex vagal tone increasing, such as neurocardiogenic syncope, vagal atrial fibrillation, brady-tachycardia syndrome, carotid sinus syndrome, situational syncope, symptomatic overtraining bradycardia, and sinus dysfunction. Many of these patients have limiting symptoms and even need a pacemaker.
- Cardioneuroablation has been a new option for these cases as it allows to permanently reduce the vagal effect avoiding pacemaker implantation.

What the study adds?

- The ablation of fractionated endocardial potentials during sinus rhythm (AF-Nests) promotes intense vagal denervation. AF-Nests may be easily identified and are directly related to the neuro-myocardial interface.
- Extracardiac vagal stimulation during the procedure is essential to demonstrate the presence of the vagal effect, to guide the ablation, and to prove the denervation after AF-Nests ablation.

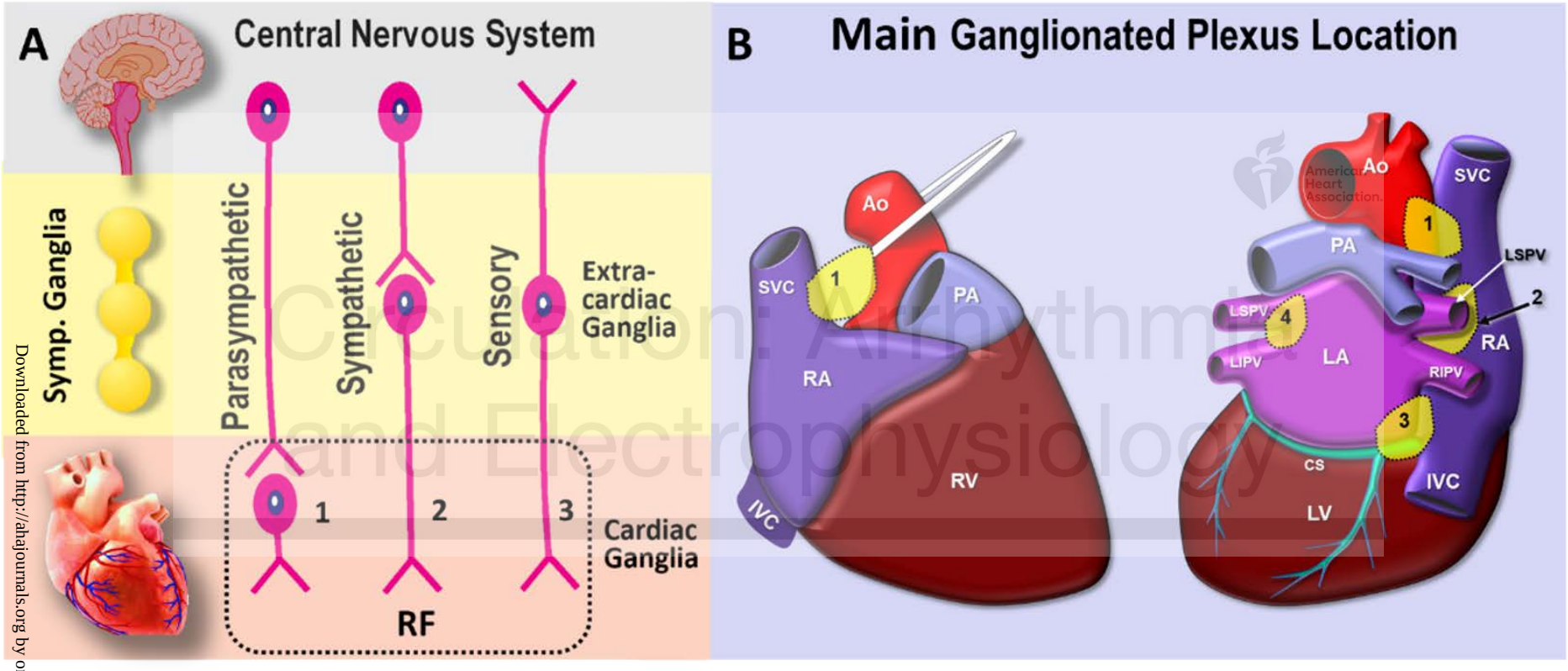

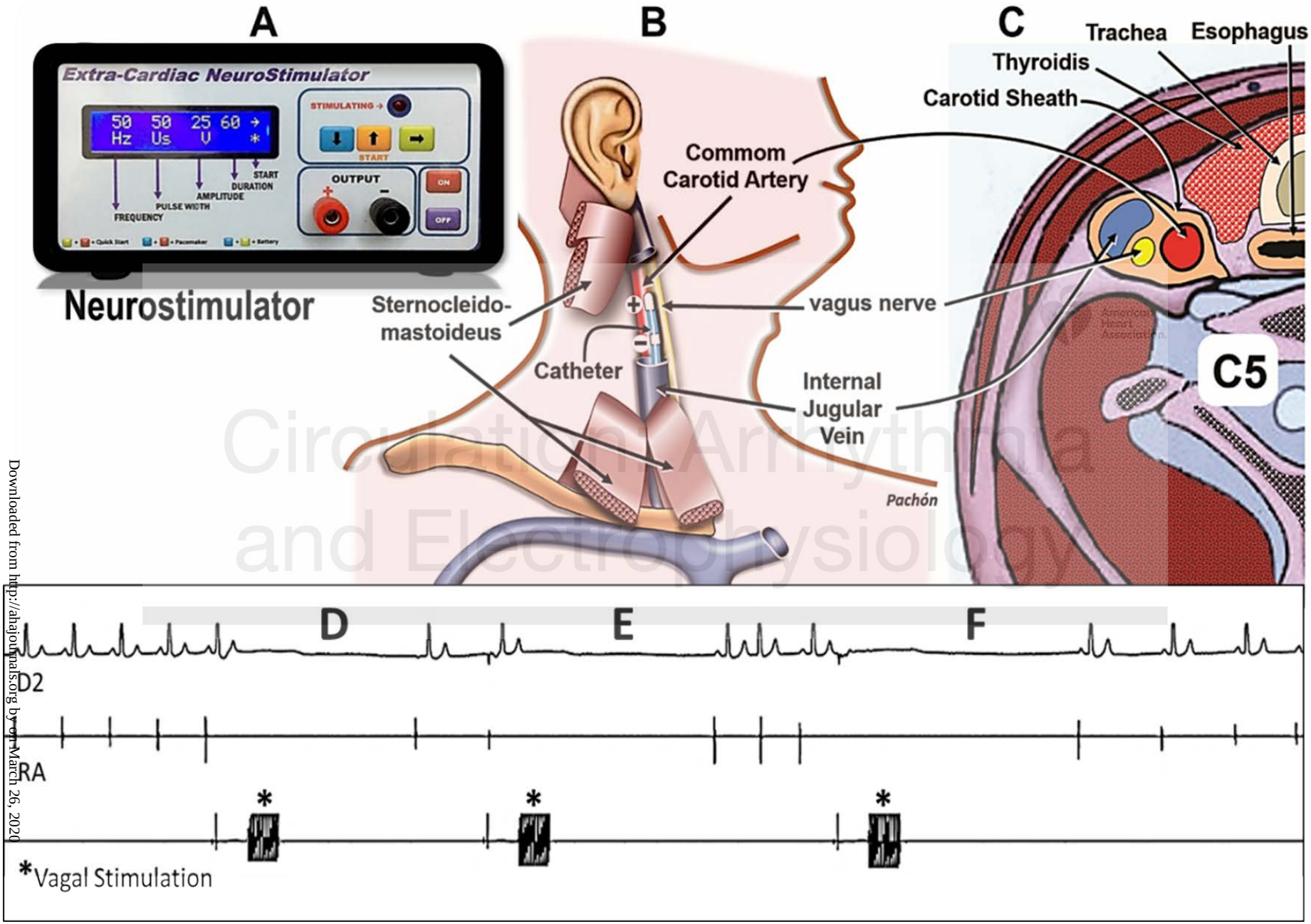

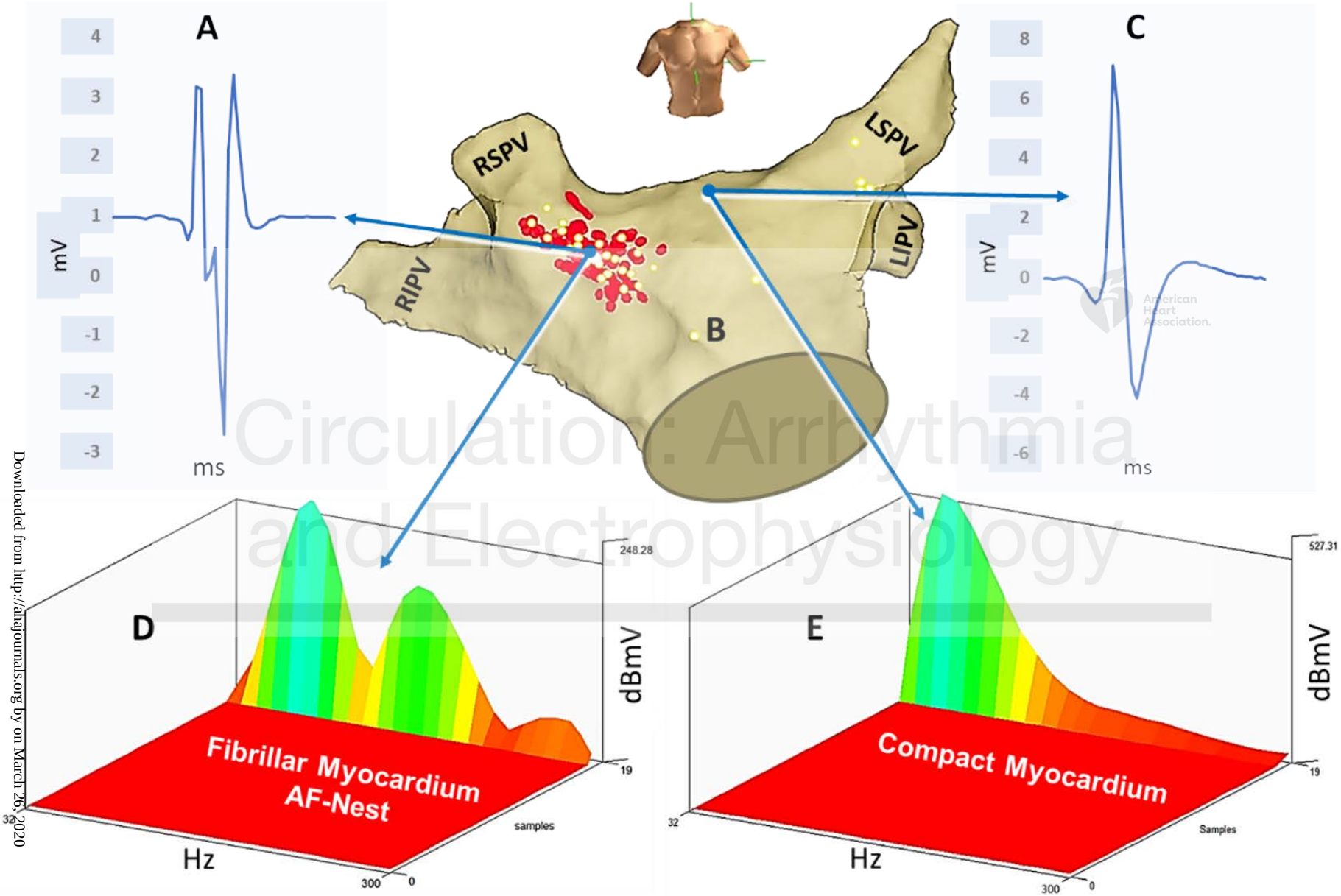

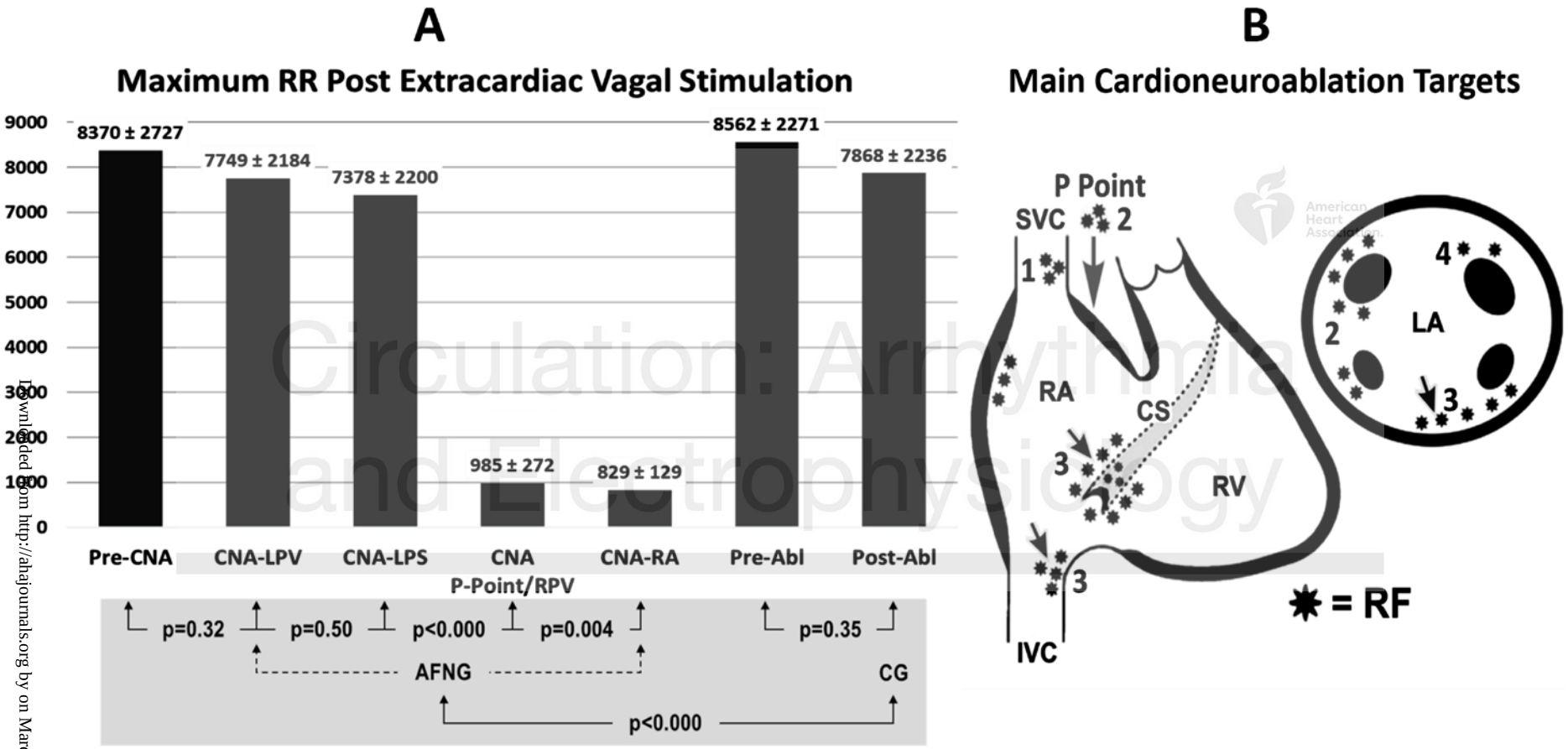

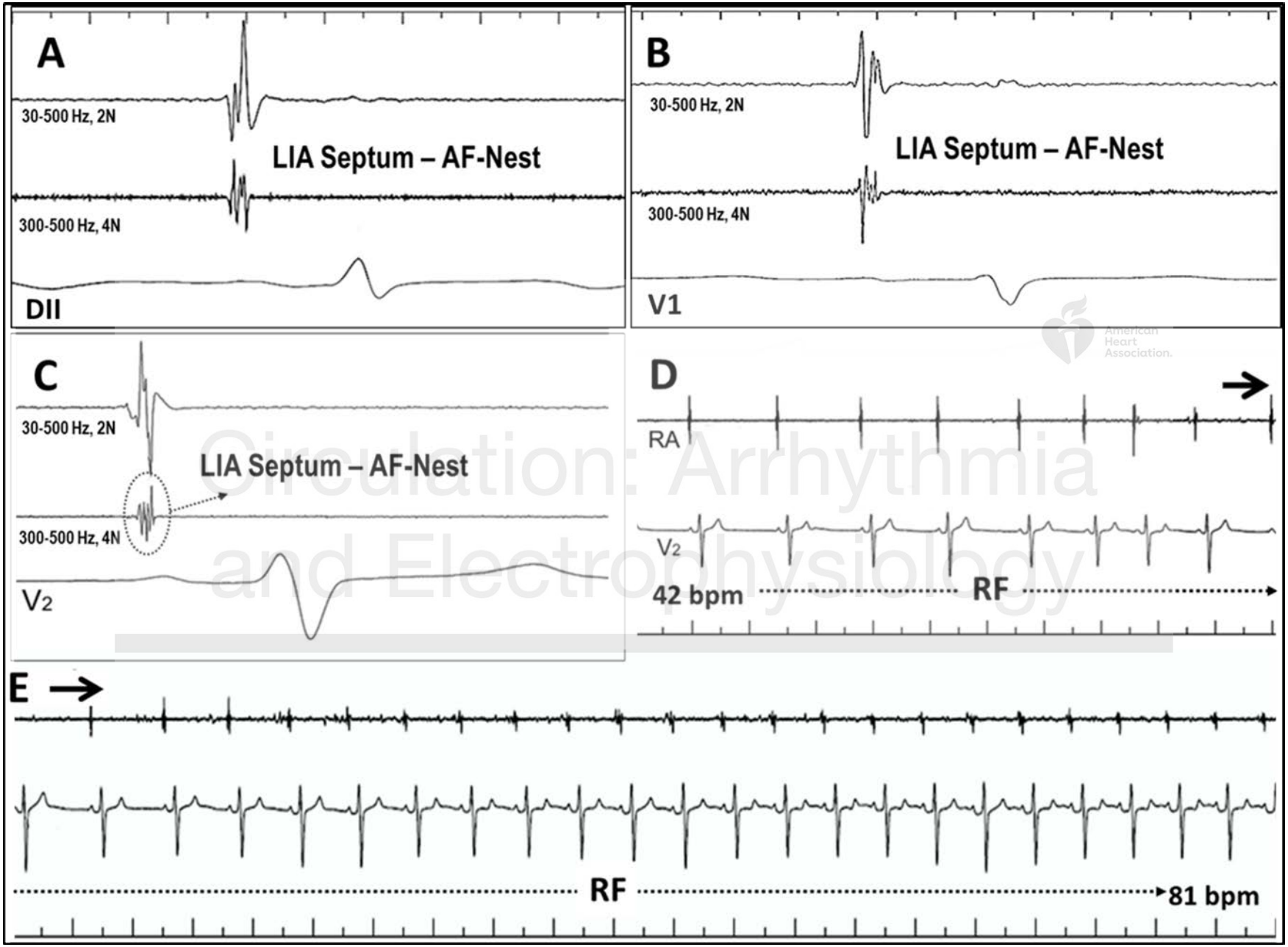

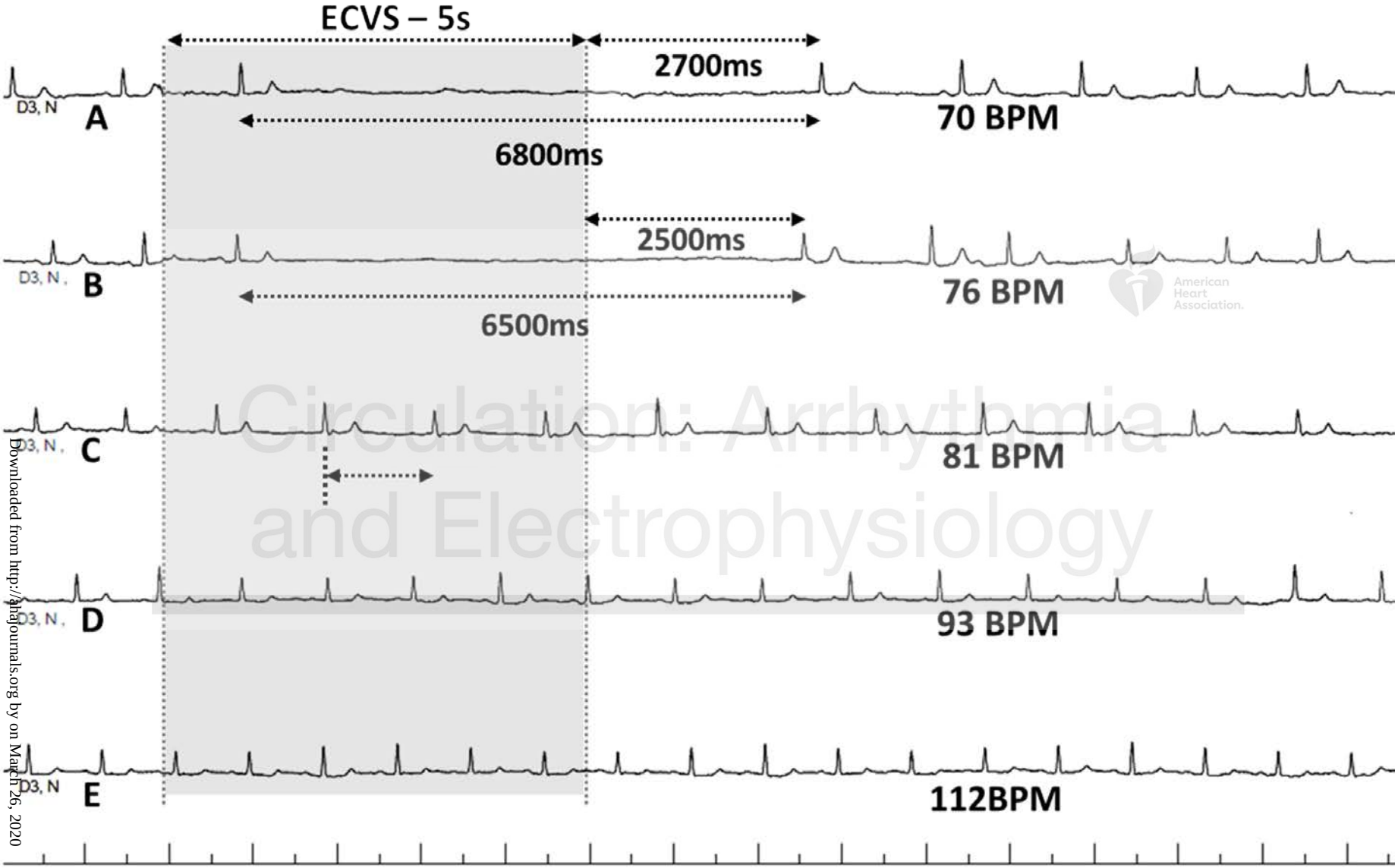

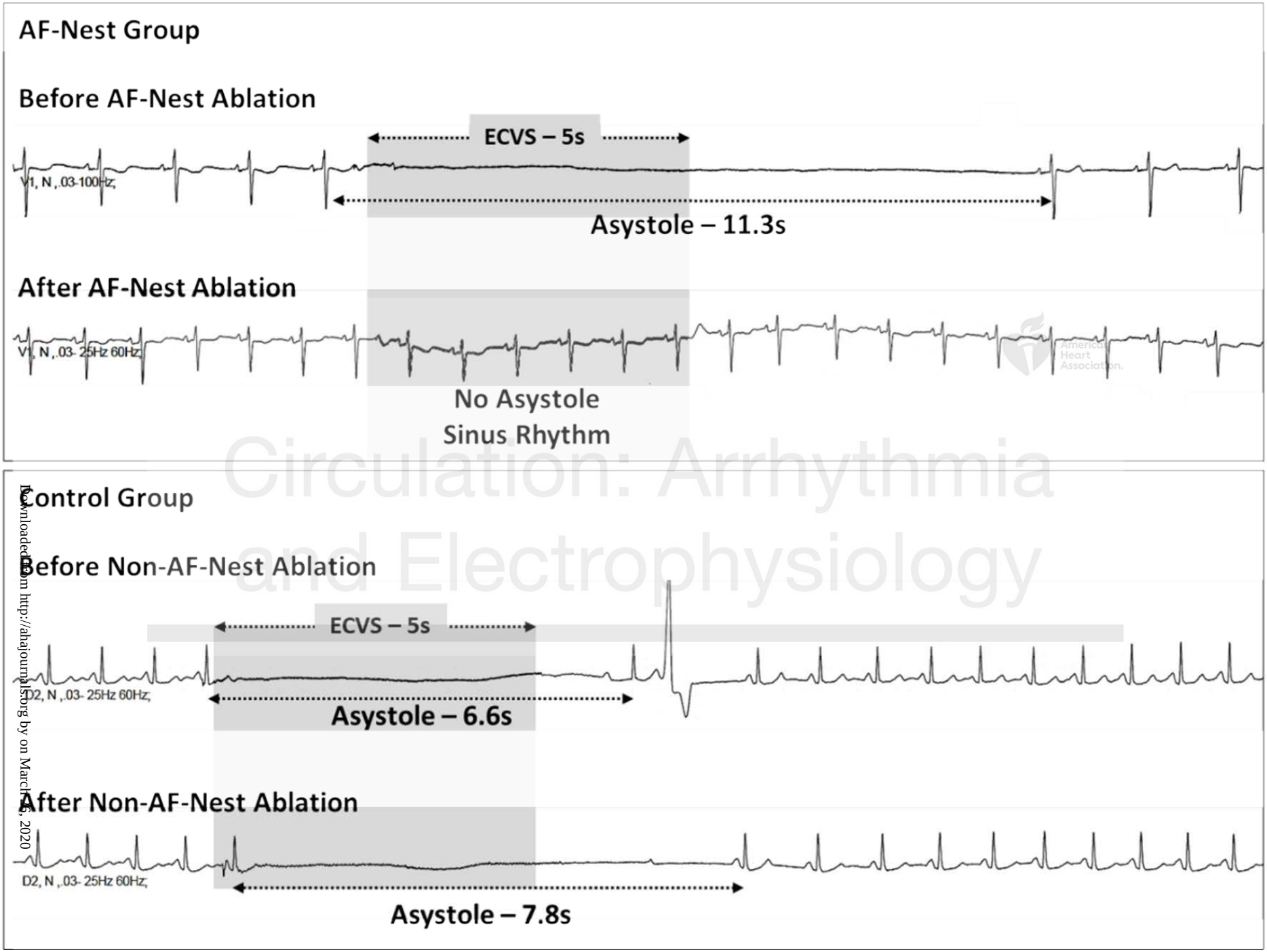

Graphic Abstract